

Content available at: <https://www.ipinnovative.com/open-access-journals>

Indian Journal of Orthopaedics Surgery

Journal homepage: <https://www.ijos.co.in/>

Original Research Article

Clinical, radiological and functional outcome following surgical fixation of acetabular fractures

Senthil Narayanan Vanamail^{1*}, Perumal Vanamail²¹Meenakshi Mission Hospital & Research Centre, Madurai, Tamil Nadu, India²Trichy SRM Medical College Hospital & Research Centre, Irungalur, Tamil Nadu, India

ARTICLE INFO

Article history:

Received 17-03-2024

Accepted 22-03-2024

Available online 08-06-2024

Keywords:

Acetabular- fracture

Surgical fixation

Functional outcome

Complications

ABSTRACT

Background: Acetabular fractures are commonly caused by high-velocity injuries that can result from falls from heights or motor vehicle accidents. Surgical fixation has been found to result in improved clinical outcomes such as reduced pain, improved range of motion, and improved alignment and stability of the joint. Patients with pelvic injuries often have associated multiple systemic injuries, adding to the overall morbidity and mortality. Treating fractures in the pelvic area involving the acetabulum can be complicated, significantly when displaced. Proper exposure of the acetabulum and rigid internal fixation is necessary to achieve the main goals of treatment, which are to reconstruct the articular surface and promote early mobilization. Closed methods make it nearly impossible to restore the articular surfaces completely and obtain enough stability for early hip motion.

Objectives: This study assesses the functional outcome of open surgical fixation of acetabulum fractures involving single or both columns.

Materials and Methods: Our study looked at patients over 18 years old with displaced fractures, and we treated them using only two approaches: the Kocher Langenbeck approach and the Modified Stoppa approach. Radiological and functional examinations were performed monthly for the first six months. Postoperative radiological assessments were graded using Matta's criteria, and functional outcomes were assessed using modified Merle d' Aubigné and Postel Hip Score.

Results: We treated displaced acetabular fractures using only two non-extensile approaches: the Kocher Langenbeck approach and the Modified Stoppa approach. In most cases (67%), we used only one method, except in 7 patients. Our treatment achieved an impressive 85% rate of good to excellent outcomes (18 out of 21). Our study found that the delay in surgery time significantly impacted Merle d' Aubigne scores ($P < 0.05$), leading to complications and lower functional outcomes in complicated cases. The functional and radiological outcomes were also significantly affected by the mechanism of injury, time between injury and surgery, initial degree of displacement, and quality of reduction. Surgical fixation of displaced acetabular fractures can yield better results with good imaging facilities, experienced surgeons, better instrumentation, and good perioperative care. However, further studies with an adequate sample size are needed to validate our findings.

Conclusion: A study on the outcome of acetabular fractures treated surgically found that early surgical intervention and good perioperative care can lead to satisfactory functional outcomes. The study used only two non-extensile approaches and achieved an 85% rate of suitable to excellent outcomes. The study also observed that the mechanism of injury, time between injury and surgery, initial degree of displacement, and reduction quality significantly affected functional and radiological outcomes. However, further studies are needed to validate the findings.

This is an Open Access (OA) journal, and articles are distributed under the terms of the [Creative Commons Attribution-NonCommercial-ShareAlike 4.0 License](https://creativecommons.org/licenses/by-nc-sa/4.0/), which allows others to remix, tweak, and build upon the work non-commercially, as long as appropriate credit is given and the new creations are licensed under the identical terms.

For reprints contact: reprint@ipinnovative.com

1. Introduction

Acetabulum fractures are often caused by high-velocity injuries, such as those resulting from motor vehicle accidents or falls from a height. An earlier study¹ showed that Acetabular fractures are mainly caused by motor vehicle accidents (80.5%) and falls (10.7%). The study found that young, active men are more likely to experience acetabular fractures, with posterior wall fractures being the most common type, accounting for 23.6% of all acetabular injuries according to the Letournal classification. (2007).² Acetabular fractures usually happen along with other fractures. When the fragments of a fracture move out of place, it can cause the hip joint to become uneven. This unevenness puts pressure on the cartilage surface, which can cause it to break down quickly and lead to arthritis of the hip joint, which can be disabling. Fixing fractures to provide stable, pain-free hip joints and promote early mobilization to prevent secondary osteoarthritis is crucial. However, fixing acetabular fractures can be very challenging for orthopaedic surgeons due to the acetabulum's complex anatomy, the complicated fracture pattern, and the difficult access to the fracture site. This makes it a steep learning curve for surgeons.³

Fractures of the pelvic area involving the acetabulum are complicated to treat, significantly when displaced. The main goals of the treatment should be to reconstruct the articular surface and promote early mobilization. However, this can only be achieved through proper exposure to the acetabulum and rigid internal fixation. Restoring the articular surfaces completely and obtaining enough stability for early hip motion is nearly impossible with closed methods.

The functional outcome of fractures depends on several factors, including age, associated injuries to vital structures, fracture pattern,^{4,5} superomedial dome impaction, femoral head dislocation during injury,⁶ delay to surgery, femoral head damage, and the quality of reduction.⁷ This study evaluates the functional outcome of acetabular fractures using Kocher Langenbeck, Modified Stoppa, or both approaches.

2. Materials and Methods

The Department of Orthopaedic Surgery at Meenakshi Mission Hospital and Research Centre, Madurai, Tamil Nadu state, India, conducted a two-year (2018-2020) hospital-based prospective observational study. The institutional ethical committee granted ethical clearance for the study. All patients with closed acetabular fractures with displacement more than 2mm single or both columns, age greater than 18 years, and fractures less than three weeks were included in the study. Open fractures, patients with preexisting hip arthritis, pathological fractures, and patients

with inflammatory arthritis were excluded from the study.

Radiological assessment was conducted using anteroposterior views of the acetabulum and computed tomography. Closed reduction was performed on dislocated patients under sedation, and skeletal traction was applied to all patients. Open reduction and internal fixation were carried out 5 to 7 days after the injury using non-extensile approaches, either alone or in combination. These approaches included the Posterior Kocher Langenbeck approach and the Modified Stoppa approach. All patients were given Indomethacin 25mg TDS orally for six weeks to prevent deep vein thrombosis, low molecular weight heparin for seven days, and oral anticoagulants for five weeks. Passive mobilization began on postoperative day 2, and active movements were gradually introduced based on pain levels. Weight-bearing was allowed once the fracture consolidated, mainly in the third or fourth month. Radiological and functional examinations were performed monthly for the first six months. Postoperative radiological assessments were graded using Matta's criteria,⁸ and functional outcomes were assessed using modified Merle d'Aubigné and Postel Hip Score.⁹

2.1. Statistical analysis

The study used IBM SPSS version 25.0 for statistical analysis. Descriptive statistics such as mean, standard deviation (SD), and range values were calculated for continuous outcome variables like age, delay in time of surgery, and Modified Merle d'Aubigne and Postel score. At the same time, categorical data were presented as frequency and percentage values. To compare the means between the two groups, the Student's t-independent test was used. The correlation between the delay time of surgery and Modified Merle d'Aubigne and Postel score was assessed through bivariate correlation analysis. Functional outcomes were classified as excellent, good, fair, or poor based on the clinical cut-off score, and a two-sided probability of $P < 0.05$ was considered statistically significant.

3. Results

Our study followed up on 21 patients who were admitted with acetabular fractures. Out of the total patients, 16 (76%) were below the age of 50, which is considered the most active age group (Table 1). The mean age (\pm SD) of males and females was 40.5 ± 13.3 and 41.7 ± 11.5 years, respectively, and no significant difference ($P > .05$) was found in the mean age. The combined mean age of the study group was 40.9 ± 12.5 years. Out of the 21 patients, 12 (57.1%) had right-side injuries, while the remaining 9 (42.9%) patients had left-side injuries (Table 2). Our study was dominated by male patients (14, 66.7%), with a male-to-female ratio of 2:1. In our study, the majority of fractures were caused by road traffic accidents (18, 86%), followed

* Corresponding author.

E-mail address: senthilvsn@gmail.com (S. N. Vanamail).

by high-impact falls (3, 14%) (Figure 1).

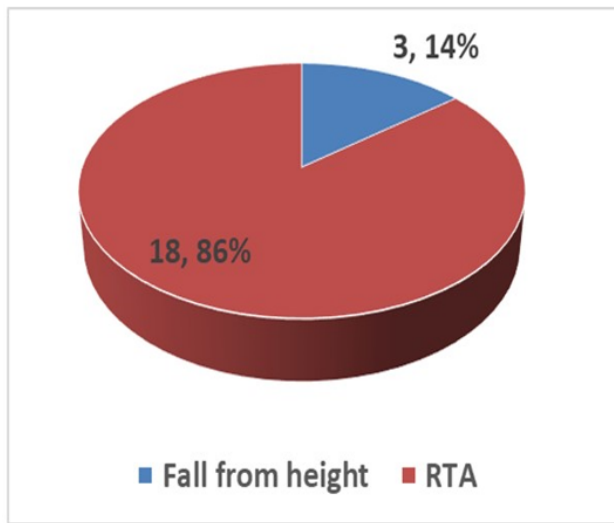


Figure 1: Distribution of patients by injury mode

In our study, the most common fracture type was posterior columns with posterior wall fractures, with seven patients (33.4%) affected. This was followed by posterior wall fractures, observed in 4 patients (19.1%) (Table 3). Five patients had a posterior hip dislocation. One patient had a central hip dislocation. Two of the Posterior hip dislocation patients had associated sciatic nerve injury. Nine patients (42.8%) had associated skeletal injuries. The mean (\pm SD) days of delay in surgery for males and females were 4.4 ± 2.6 and 4.6 ± 4.7 days. The overall mean delay is 4.43 ± 3.3 days. The average blood loss was found to be around 600 ml. Additionally, eight patients required intraoperative blood transfusion.

Three patients (14.3%) had complications, and of these;

One patient with a Head injury had postoperative sciatic nerve palsy, operated by the Kocher Langenbeck approach. Subsequently, he developed a surgical site infection and osteonecrosis of the femoral head. He underwent total hip arthroplasty after controlling the infection. Sciatic Nerve palsy was recovering.

One patient who was operated on by modified Stoppa's approach developed Deep vein thrombosis and postoperative seroma collection. Deep vein thrombosis was treated with Anticoagulant. Seroma drained, and a compression vest was applied, which subsided gradually.

One patient developed chondrolysis and was planned for Total Hip Replacement. Postoperatively, the quality of fracture reduction was analyzed using Matta's criteria. Of the 21 patients, 15 (71.4%) had an anatomic reduction, while 6 (28.6%) had a satisfactory reduction. We observed that an increasing degree of fracture comminution posed a difficulty in achieving a congruent articular surface. The Mean \pm SD of days delay in surgery for complicated cases

(8.3 ± 6.0 days) was significantly ($P=0.024$) higher compared to non-complicated cases (3.8 ± 2.4 days). The Mean \pm SD of a score of Merle d' Aubigne for complicated cases (13.3 ± 2.3) was significantly ($P=0.012$) less compared to non-complicated cases (15.8 ± 1.3).

Our study found a significant negative correlation ($r=-0.44$, $P=0.044$) between the delay in surgery and the Merle d'Aubigne score. This means that a longer delay in surgery was associated with a lower Merle d'Aubigne score.

17 (81%) patients achieved good or excellent functional outcomes (Table 5). Only four (19%) had either fair or poor functional outcome status. Two of these four patients had complications, and the other two did not have any complications (Figure 2).

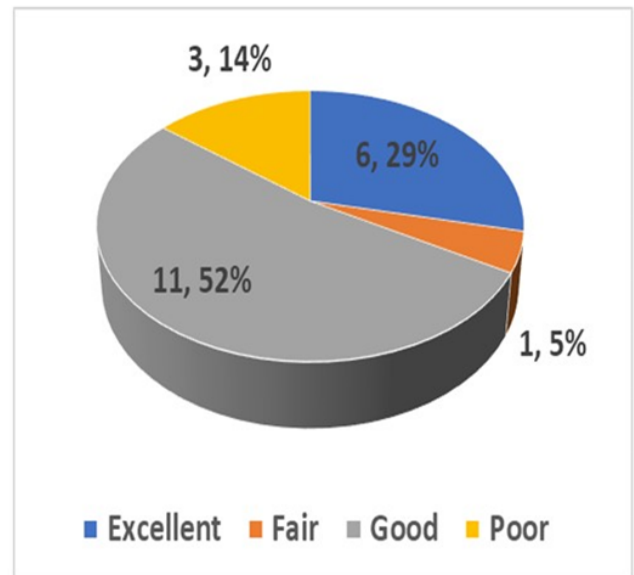


Figure 2: Functional outcome status

We observed that the mean score for anatomically reduced fractures was 16.57; for imperfect reduction, it was 14.4; and for poorly reduced fractures, it was 11.3. The average functional outcome score was 15.47, ranging from 11 to a maximum score of 18. Our study showed that out of 21 patients, six patients (28.5%) had excellent, 11 patients (52.3%) had good, one patient (4.7%) had fair, and three patients (14.2%) had poor results. Overall, about 81% had good to excellent outcomes.

Another study¹⁰ was conducted on 105 closed acetabular fractures treated with various modalities. The most common fracture pattern observed was a posterior wall fracture, followed by a transverse fracture. Of the 105 patients, 49 were treated conservatively, while 56 underwent surgical intervention. The study reported excellent radiological outcomes in 97 patients (92%). The authors concluded that excellent medium-term results are only possible if the fracture is reduced and anatomically suitable. They further

indicated that the outcome results are influenced by factors such as patient age, fracture pattern, associated injuries, delay to surgical fixation, and articular cartilage damage.

Our study found that various factors, such as the mechanism of injury, the time between injury and surgery, the initial degree of displacement, and the reduction quality, significantly affected both functional and radiological outcomes.¹¹

Table 1: Age and gender distribution

Age group	Gender		Total (N=21) n (%)
	Female (N=7) n (%)	Male (N=14) n (%)	
20-30 years	1 (14.30%)	4 (28.60%)	5 (23.80%)
31-40	2 (28.60%)	4 (28.60%)	6 (28.6%)
41-50	2 (28.60%)	3 (21.40%)	5 (23.8%)
51-60	2 (28.60%)	2 (14.30%)	4 (19.0%)
>60 years	0 (0%)	1 (7.1%)	1 (4.80%)

Table 2: Distribution of patients by associated injury types

Associated Skeletal Injury types	N	%
Nil	6	28.6
Both bone forearm	1	4.8
Both bone leg #	2	9.5
Central dislocation	1	4.8
Distal radius#	1	4.8
Humerus #	1	4.8
Posterior dislocation	5	23.8
Proximal tibia #	1	4.8
Superior and inferior pubic rami#	3	14.3

Table 3: Types of procedures carried out

Procedure	N	%
ORIF Kocher langenbeck approach	11	52.4
ORIF Kocher langenbeck + ORIF	7	33.3
Modified Stoppa approach		
ORIF Modified Stoppa approach	3	14.3

Table 4: Distribution of patients by fracture types

Fracture Types	N	%
Anterior column	2	9.5
Anterior column + Posterior column	3	14.3
Anterior column + Posterior wall	2	9.5
Anterior wall	1	4.8
Anterior wall + Posterior wall	1	4.8
Posterior column + Posterior wall	7	33.4
Posterior wall	4	19.1
Transverse + Posterior wall	1	4.8

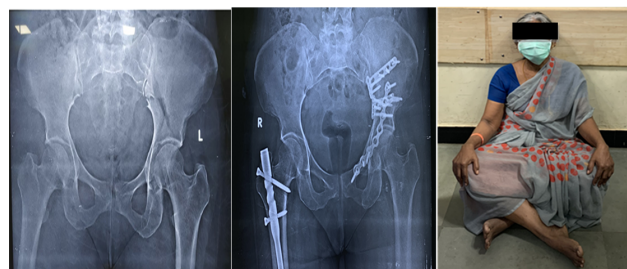

Figure 3: A 51-year-old female sustained a road traffic accident and was diagnosed to have a left posterior column plus anterior column acetabulum fracture and right shaft of femur fracture. Surgical fixation is done using the Kocher Langenbeck/Modified Stoppa approach. Nailing done for right femur. In the six months following, the patient showed excellent results

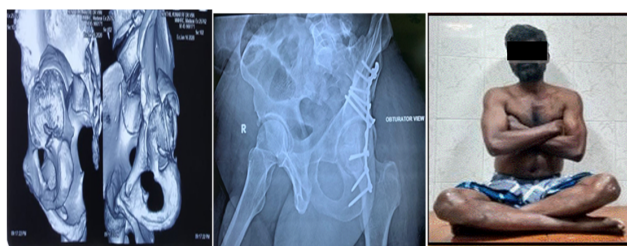

Figure 4: A 45-year-old male sustained a Road traffic accident and was diagnosed to have left posterior column acetabulum fractures. He was taken up for internal fixation after three days. Six months later, the patient showed Excellent results

4. Discussion

The treatment of acetabular fractures is constantly evolving. Treating such fractures involves considering the patient as a whole, as they are usually caused by high-energy forces and often accompanied by additional visceral or skeletal injuries or both. Current concepts of damage control orthopaedics suggest that a primary survey and hemodynamic stabilization should be done before definitive fracture fixation. Occasionally, fracture fixation can be delayed for more than a week to minimize the risk of postoperative acute respiratory distress syndrome (ARDS).^{12,13} The primary benefits of open reduction and internal fixation for acetabular fractures include anatomic reduction, rigid fixation, and early mobilization. The procedure's clinical outcome directly depends on the reduction quality achieved during surgical fixation.

In our study, we utilized only two approaches, namely the Kocher Langenbeck approach and the Modified Stoppa approach. We primarily used a single approach in most patients, except for 7 cases (Table 4). We achieved a satisfactory reduction in 85% of the cases. According to Tile, achieving an anatomic decrease in cases of acetabular fractures can be challenging, even with the best hands. The success rate for anatomic reduction is around 70%, which is

Table 5: Functional outcome by the type of fracture

Type of fracture	No. of patients	Average score	Functional outcome			
			Excellent	Good	Fair	Poor
Anterior column	2	14	-	1	-	1
Anterior column + Posterior Column	3	15	1	1	-	1
Anterior column + Posterior wall	2	15	-	1	1	-
Anterior wall	1	17	1	-	-	-
Anterior wall + Posterior wall	1	15	-	1	-	-
Posterior column + Posterior Wall	7	15.6	2	4	-	1
Posterior wall	4	16.2	2	2	-	-
Transverse + Posterior wall	1	16	-	1	-	-

influenced by factors such as the type and complexity of the fracture.

Understanding the mechanism of injury is crucial in identifying potential injuries and providing optimal care to trauma patients. By knowing how the injury occurred, healthcare providers can better anticipate and diagnose injuries, leading to more effective treatment and better outcomes.^{14,15} Preoperative evaluation, including unique views and CT scans, is crucial in planning the appropriate approach, minimizing surgery duration, and reducing intraoperative and postoperative complications. The Kocher-Langenbeck approach is one of the surgical approaches many pelvic acetabular surgeons prefer. It is commonly used in fractures that do not involve the anterior wall or column and is employed frequently in many studies, accounting for approximately 90% of cases.¹⁶ Our study found that excellent reductions and satisfactory functional outcomes for fractures such as T-shaped fractures, transverse and posterior wall fractures, and posterior column and posterior wall fractures can be achieved by a single Kocher-Langenbeck approach. This approach is a preferred surgical technique for many pelvic acetabular surgeons and is commonly used for fractures that do not involve the anterior wall or column.¹⁷ It was observed that anatomical reduction alone was not enough to restore joint function. Other factors were also found to be influential in determining the functional outcome, such as fracture pattern, marginal impaction, age of the patient, and associated co-morbid conditions. These factors were considered during the treatment plan to ensure the patient received the best care for optimal outcomes.¹⁸ We observed one sciatic nerve palsy in a patient who underwent the posterior approach. A similar observation was reported in another study¹⁹ and one case of deep vein thrombosis (DVT) in a patient who underwent the anterior approach. However, the patient's DVT subsided gradually, and they achieved an excellent functional outcome.

Minimizing the delay between the injury and surgery is crucial to achieve anatomical reduction and reduce the incidence of arthritis. Delayed surgery can lead to difficulty in achieving an anatomic reduction. Therefore, early surgical intervention is recommended to minimize

the risk of complications and improve the chances of a successful outcome.²⁰ Our mean delay in surgery was 4.43 ± 3.3 days. The incidence of avascular necrosis (AVN) among patients with acetabular fractures cannot be solely attributed to the surgical approach used during treatment. Various other factors, such as the initial violence of injury and prolonged duration of unreduced femoral head dislocation, may also contribute to the development of AVN. Additionally, iatrogenic factors such as damage to the blood supply during surgery may also play a role. Therefore, it is essential to carefully evaluate the patient's condition and potential risk factors before deciding on the appropriate treatment approach.¹⁵

Although our study included a small group of 21 patients, we utilized good preoperative planning, non-extensile approaches, and early rehabilitation to achieve successful outcomes. According to our modified Merle d'Aubigne and Postel scoring system, we achieved a 94% rate of good to satisfactory results. However, further long-term follow-up is necessary to comment on the durability of these outcomes.

5. Conclusion

Our study on displaced acetabular fractures treated with open reduction and internal fixation demonstrated a satisfactory functional outcome. We focused on patients above 18 years old and used only two non-extensile approaches, namely the Kocher-Langenbeck approach and the Modified Stoppa approach. Most patients (67%) were treated with a single method, except for 7. We achieved an 85% rate of suitable to excellent outcomes (18 out of 21), which is impressive. Our study also found a significant negative correlation ($r = -0.44$, $P < 0.05$) between the delay in surgery time and the Merle d'Aubigne scores. Delayed surgery time was associated with complications and lower functional outcomes in complicated cases. We also observed that the mechanism of injury, time between injury and surgery, initial degree of displacement, and quality of reduction significantly affected functional and radiological outcomes. With good imaging facilities, experienced surgeons, better instrumentation, and good

perioperative care, surgical fixation of displaced acetabular fractures can yield better results. However, further studies with an adequate sample size are warranted to validate our findings. There were certain limitations to our research. For instance, the patients were from a single institute, which may limit the generalizability of the findings. Additionally, due to the COVID-19 lockdown, a small number of patients were able to come for follow-up in the year 2020. However, despite these limitations, our study achieved a reasonable success rate with an 85% rate of good to satisfactory results according to the modified Merle d'Aubigne and Postel scoring systems. Nonetheless, a prospective multi-institutional study with a larger sample size and long-term follow-up is suggested to address these limitations.

6. Source of Funding

None.


7. Conflict of Interest

None.

References

- Giannoudis PV, Grotz MR, Papakostidis C, Dinopoulos H. Operative treatment of displaced fractures of the acetabulum. *J Bone Joint Surg Br.* 2005;87(1):2–9.
- Letournel E. Acetabulum fractures: classification and management. *Clin Orthop Relat Res.* 1980;(151):81–106.
- Fornaro J, Keel M, Harders M, Marincek B, Székely G, Frauenfelder T. An interactive surgical planning tool for acetabular fractures: initial results. *J Orthop Surg Res.* 2010;4(1):50.
- Matta JM, Mehne DK, Rom RA. Fractures of the Acetabulum: Early Results of a Prospective Study. *Clin Orthop Relat Res.* 1986;205(205):241–50.
- Moed BR, Paul HY, Gruson KI. Functional outcomes of acetabular fractures. *J Bone Joint Surg Am.* 2003;85(10):1879–83.
- Hougaard K, Thomsen PB. Traumatic posterior dislocation of the hip: prognostic factors influencing the incidence of avascular necrosis of the femoral head. Archives of orthopedic and traumatic surgery. *Arch Orthop Trauma Surg.* 1986;106(1):32–5.
- Mears DC, Velyvis JH, Chang CP. Displaced acetabular fractures managed operatively: indicators of outcome. Clinical orthopedics and related research. *Clin Orthop Relat Res.* 2003;(407):73–86.
- Matta JM. Fracture of the acetabulum: reduction accuracy and clinical results in patients managed operatively within three weeks after the injury. *Orthopedic Trauma Directions.* 2011;9(2):31–6.
- Moed BR, Carr SEW, Gruson KI, Watson JT, Craig JG. Computed tomographic assessment of fractures of the posterior wall of the acetabulum after operative treatment. *J Bone Joint Surg Am.* 2003;85(3):512–22.
- Badami RN, Shetty M, Kumar MA. The functional and radiological outcome of acetabular fractures and the factors affecting the outcome. *Int J Orthop Sci.* 2017;3(4):312–8.
- Iqbal F, Uddin AA, Younus S, Zia OB, Khan N, Asmatullah. Surgical outcomes of acute acetabular transverse fracture using ilioinguinal and Stoppa approach. *J Acute Dis.* 2017;6(6):278–83.
- Taeger G, Ruchholtz S, Waydhas C, Lewan U, Schmidt B, Nast-Kolb D. Damage control orthopaedics in patients with multiple injuries is effective, time-saving, and safe. *J Trauma.* 2005;59(2):408–16.
- Prasad AS, Rishi R. History of Pelvis-Acetabular Fracture Treatment. *Trauma Int.* 2016;2(2):17–9.
- Beuran M, Negoï I, Păun S, Runcanu A, Gaspar B. Mechanism of injury—trauma kinetics. What happens? How? *Chirurgia (Bucur).* 2012;107(1):7–14.
- Dunet B, Tournier C, Billaud A, Lavoine N, Fabre T, Durandeau A. Acetabular fracture: long-term follow-up and factors associated with total hip arthroplasty secondary implantation. *Orthop Traumatol Surg Res.* 2013;99(3):281–90.
- Fica G, Cordova M, Guzman L, Schweitzer D. Prasad AS, Rishi R. History of Pelvis-Acetabular Fracture Treatment. *Trauma International.* 1998;22(6):17–19.
- Zhu SW, Wang MY, Wu XB, Yang MH, Sun X. Operative treatment of associated acetabular fractures via a single Kocher-Langenbeck approach. *Zhonghua Yi Xue Za Zhi.* 2011;91(5):327–30.
- Kreder HJ, Rozen N, Borkhoff CM, Laflamme YG, McKee MD, Schemitsch EH, et al. Determinants of functional outcome after simple and complex acetabular fractures involving the posterior wall. *J Bone Joint Surg Br.* 2006;88(6):776–82.
- Fassler PR, Swiontkowski MF, Kilroy AW, Roult ML. Injury of the sciatic nerve associated with acetabular fracture. *J Bone Joint Surg Am.* 1993;75(8):1157–66.
- Zhang L, Xu M, He C, Du H, Chen H, Guo Y, et al. Effectiveness of acetabular transverse and posterior wall fractures by Kocher-Langenbeck approach. *Zhongguo Xiu Fu Chong Jian Wai Ke Za Zhi.* 2010;24(12):1428–31.

Author biography

Senthil Narayanan Vanamail, Resident  <https://orcid.org/0009-0002-9533-4830>

Perumal Vanamail, Professor  <https://orcid.org/0000-0002-5014-4665>

Cite this article: Vanamail SN, Vanamail P. Clinical, radiological and functional outcome following surgical fixation of acetabular fractures. *Indian J Orthop Surg* 2024;10(2):124–129.