



## Original Research Article

# Results of Unipolar v/s Bipolar (fixed) prosthesis in hemireplacement arthroplasty in neck femur fractures: A comparative study

Anand Kaushal<sup>1</sup>, Sagarkumar Usdadia<sup>1,\*</sup>, Rasik Shiyal<sup>1</sup>, Jaimin Patel<sup>1</sup>, Dhimant Patel<sup>1</sup>

<sup>1</sup>Dept. of Orthopaedics, B.J Medical College and Civil Hospital, Ahmedabad, Gujarat, India



## ARTICLE INFO

## Article history:

Received 07-12-2018

Accepted 07-11-2019

Available online 06-01-2020

## Keywords:

Hemiarthroplasty

Neck femur fractures

Unipolar prosthesis

Bipolar prosthesis.

## ABSTRACT

**Introduction:** Intracapsular femoral neck fractures account for 50% of all hip fractures occurring mainly in elderly females. Surgical treatment of neck of femur fracture is based on patient's age, comorbidities, walking abilities and life expectancy. In displaced fractures in a young patient mainly internal fixation is used while for displaced fractures in elderly patient hemiarthroplasty is preferred. Here we evaluate the results of unipolar v/s fixed bipolar prosthesis in these patients treated with hemiarthroplasty.

© 2019 Published by Innovative Publication. This is an open access article under the CC BY-NC-ND license (<https://creativecommons.org/licenses/by/4.0/>)

## 1. Introduction

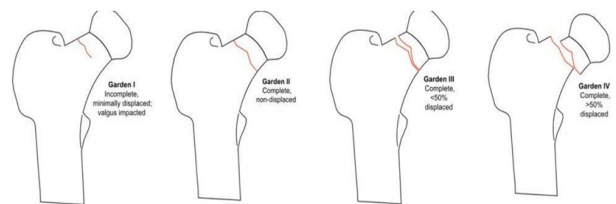
Intracapsular femoral neck fractures account for 50% of all hip fractures occurring mainly in elderly females. One of the major causes being trivial trauma. Intracapsular neck of femur fractures (#NOF) occur within the capsule of the hip joint. The blood supply to femoral head travels in a retrograde

direction via the capsule. As such, any fracture within the capsule could be likely to damage this blood supply.

### 1.1. Classification of intracapsular neck of femur fractures

The most common classification is the Garden classification

1. Garden I: incomplete and undisplaced fracture
2. Garden II: Complete but undisplaced fracture
3. Garden III: Complete fracture with partial displacement
4. Garden IV: Complete fracture with >50% displacement



**Fig. 1:** Types of neck of femur fracture (Garden classification)

Surgical treatment of neck of femur fracture is based on patient's age, comorbidities, walking abilities, life expectancy.<sup>1</sup> In displaced fractures (Gardens type I, II) internal fixation is used with acceptable rate of fracture healing complications and good outcome regarding function. Internal fixation is also preferred in young patients with displaced fracture (Gardens type III, VI).<sup>2</sup> In displaced femoral neck fracture in elderly patients various treatment options are available like total hip arthroplasty, hemireplacement arthroplasty and ORIF. In active elderly patient with long life expectancy total hip arthroplasty is best treatment while hemiarthroplasty is used in elderly patients with shorter life expectancy

\* Corresponding author.

E-mail address: [sagar.usdadia@gmail.com](mailto:sagar.usdadia@gmail.com) (S. Usdadia).

with lower functional demands.<sup>3</sup> There are two types of hemireplacement prosthesis available: Unipolar prosthesis and bipolar prosthesis. In Hemireplacement arthroplasty head of femur is replaced with metal prosthesis and the acetabulum is left intact. The unipolar hemiarthroplasty is single prosthesis in which hip joint movement occurs between acetabulum and prosthesis. But in Bipolar hemiarthroplasty, there is additional artificial joint between two parts of the prosthesis. It has a femoral head that swivels during movement. This helps to reduce the amount of wear and tear on the new joint for longer lasting results.

The femoral neck fractures are rare among young people – they are only 2% in patients under 50 years of age. The incidence increases with age, and after 50 years is doubled for each subsequent decade, and is 2-3 times higher in women than in men. 80% of hip fractures occur in women and 90% in people older than 50 years. Intracapsular femoral neck fractures account for 50% of all hip fractures. In this fracture, only 15% are undisplaced.<sup>4,5</sup>

## 2. Materials and Methods

### 2.1. Selection of patients

This randomized prospective clinical study was conducted on 120 patients with neck of femur fracture treated with Unipolar and fixed bipolar hemireplacement arthroplasty operated by same surgical team at a tertiary trauma care center between June 2016 and June 2018. These cases were selected for study randomly. Fracture patterns were classified on basis of Garden classification. Follow up intervals of patients are at 6 weeks followed by 3, 6, 12 and 24 months. All patients were able to walk after surgery independently with or without support.

### 2.2. Inclusion criteria

1. Age >60 years
2. All patients of displaced fracture – Gardens type III, IV
3. No systemic or local infection
4. No any mental illness

### 2.3. Exclusion criteria

1. Skeletally immature
2. Pathological fractures other than osteoporosis
3. Osteoarthritis and Rheumatoid arthritis of hip
4. Undisplaced fracture neck of femur

All surgeries are performed by using posterolateral approach in lateral position. A longitudinal incision is made posterior to lateral side of greater trochanter and carry it distally about 6cm along femoral axis. Proximally incision is made slightly curved towards The PSIS to a point approximately 5-6 cm proximal to greater trochanter. Then do sharp dissection of fascia lata and gluteal muscles across

greater trochanter and incise fascia lata in line with skin incision. Then retract gluteal muscle flap posteriorly which shows short external rotators inserting on femur. The sciatic nerve can be palpated in depths of the wound. Exposure of sciatic nerve is not necessary. Then dissect tendinous insertion of rotators. Before dividing the tendons, place absorbable sutures for retraction and subsequent repair. Reflection of rotators exposes the hip capsule. Then enter joint with u shaped 3-sided capsulotomy. The hip can then be exposed by flexion and internal rotation of the femur, which delivers the fractured femoral neck out of the joint, allowing access to the fractured head in the acetabulum. Then it is removed, and hemiarthroplasty can be carried out. After completion of procedures, place posterior capsular flap sutures and then tendon sutures are tied after being passed through drill holes in posterolateral aspect of greater trochanter.

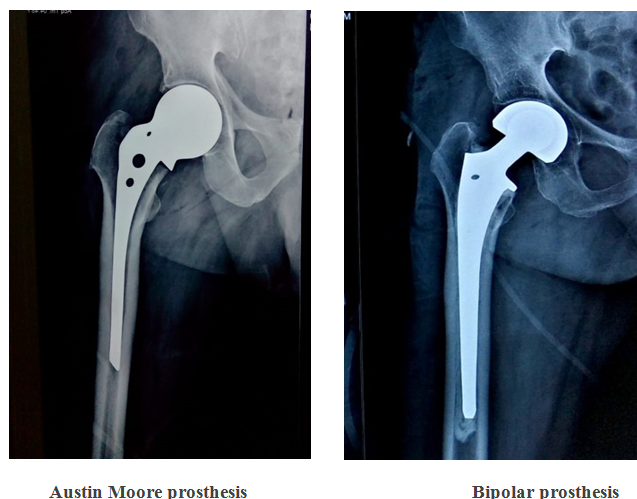
### 2.4. Unipolar hemiarthroplasty

In this procedure all replacements were done by using Austin Moore prosthesis. Surgery was done by using same lateral approach. After delivering head of femur, femoral canal must not be reamed. It is necessary to judge the leg length and hip soft tissue tension correctly at the time of insertion since there is no ability to vary this after insertion. Prosthesis were placed in neutral or slight valgus position but not in varus. Local bone graft was taken from neck tissues. It was put in between fenestrations which are available in Austin Moore prosthesis which helps in post-operative stability of prosthesis and prevent implant loosening. It is necessary to excise residual femoral neck bone laterally at the base of the greater trochanter. This will allow the prosthesis to press into softer cancellous bone in the lateral region, avoiding excess pressure on the calcar causing fracture. Once the implant was inserted, reduction was accomplished. The implant was reduced, the capsule repaired and the wound closed.

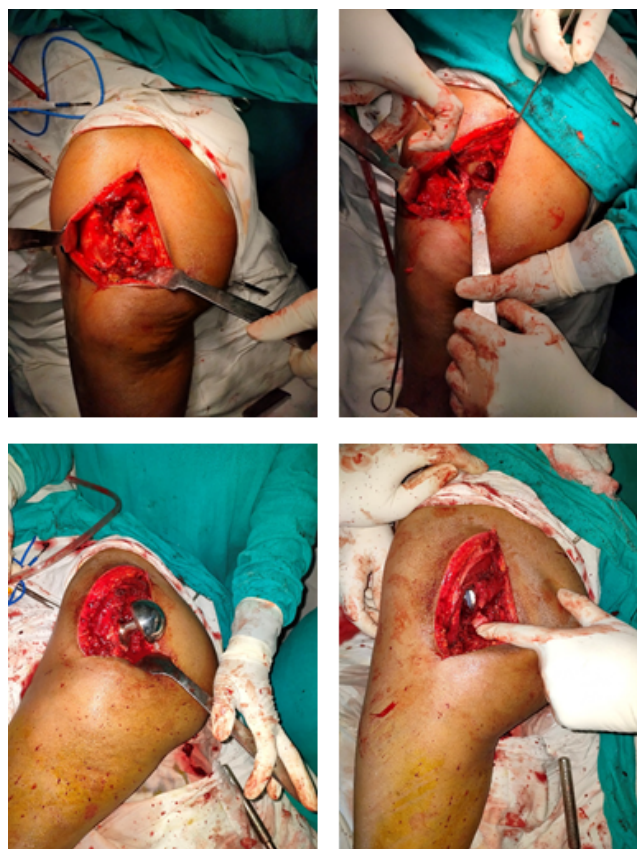### 2.5. Bipolar hemiarthroplasty

There is an articulation between the inner head and the shell and the shell and the acetabulum. This dual articulation was proposed to reduce the risk of wear and acetabular protrusion. There are two types available cemented and uncemented. In our study only cemented unfenestrated fixed implants are included. Prosthesis were kept in place by using surgical simplex bone cement with use of cement restrictor. Canal was first reamed and cement was pushed in canal with gun in retrograde pattern. Then suitable sized prosthesis was inserted. Prosthesis with larger outer head is usually preferred. We used stem pusher and Tommy bar to control depth and anteversion. Then it was placed in 10-15° anteversion, add 5-10° if there was likely chance of posterior dislocation and held in place until cement was hard

(~15min). In our institution, M J surgical bipolar prosthesis are used. Other surgical approach is identical to unipolar hemiarthroplasty.



**Fig. 2:**



**Fig. 3:** Surgical Steps

## 2.6. Complications

Complications are divided mainly into major and minor subtypes. Minor complications include persistent hip pain, poor mobility, lower limb muscle wasting, superficial infection. Major complications are dislocation, prosthetic loosening, periprosthetic fracture (iatrogenic or late), deep infection, cement related complications, pulmonary embolism, deep vein thrombosis.<sup>6,7</sup> Dislocations are the most common cause for revision surgery. Technical errors at the time of surgery with implant malposition are perhaps the commonest cause. The surgical approach also has an influence with the posterior approach having increasing the risk of dislocation compared with anterolateral exposures. Uncemented Austin Moore prosthesis may loosen and change position if the patient is active or has another fall. Closed reduction is usually possible with unipolar and total hip implants. The bipolar hemiarthroplasty is much difficult to reduce closed. A particular risk with closed reduction of bipolar implants is dissociation of the bipolar head from the stem, which will make closed reduction difficult. In cases of recurrent dislocation or irreducible dislocation, an open reduction is required.<sup>8</sup> Poor prognostic factors for return of mobility are increasing age, cognitive impairment, and any degree of impaired mobility before fracture. The presence of concomitant medical comorbidities increases the risk of death after surgery. This applies particularly to patients with significant cardiorespiratory conditions. Low- molecular-weight heparin or aspirin is probably the safest choices for thromboprophylaxis for DVT and embolism in patients with a femoral neck fracture supplemented by a pneumatic compression device if tolerated by the patient.

Acetabular erosions were analyzed by radiologists. They are graded according to criteria of baker et al.<sup>8</sup> grade 0 no erosions, grade 1 (narrowing of articular cartilage with no bone erosions), grade 2 (acetabular bone erosions and early migration), and grade 3 (protrusion acetabuli).

The Harris hip score<sup>9</sup> measures hip functions divided in four categories; pain (0-44), function (0-47) absence of deformity (0-4) and range of motion (0-5). Possible maximum score is 100.

## 3. Observations & Results

This is a study of 120 patients of age group >60 years. The mean age was 73.6 years. In our study, the median age of males was comparatively younger than females. Most of them occurred in old females which occurred due to trivial trauma. 16% of the patients had Gardens III and 84% patients had Gardens type IV fracture.

In our study 25% patients (30) were treated with unipolar arthroplasty -Austin Moore prosthesis while 75% patients (90) were treated with cemented bipolar arthroplasty.

The operative time for unipolar hemiarthroplasty was 30 mins as compared to 50 mins in Bipolar Hemiarthroplasty

which was of great importance in high risk patients.

Immediate mobilization with help of aids were started in post op day 1 in both the groups of patients. Regarding post-operative pain relief and pain in further follow ups there are no any statistical difference found between two groups.<sup>10,11</sup> Follow up was taken at 6 weeks followed by 3, 6, 12, 24 months with clinical and radiological assessment.

1(0.83%) patient in which bipolar had done, had periprosthetic fracture and was treated with revision THR. Possible reason was history of low velocity accidental trauma. In our study, 10(8.3%) dislocation had occurred. All of them had bipolar prosthesis. Out of them 7 treated with closed reduction. And rest of them treated with open reduction. Deep infection occurred in 3(2.5%) patient, all of them had bipolar prosthesis. One patient was treated with debridement and higher antibiotics followed by antibiotics coated cemented beads and two patients underwent girdle stone arthroplasty. Two of the patients (1.66%) had DVT, all of them had bipolar prosthesis.

Post-operative mortality occurred in 2.5% (3) patients in bipolar group. Possible reasons are morbid condition, pulmonary embolism or cement related complication. No mortality was observed in unipolar group.

In follow up period, residual pain was present in 35% of patient, there is no any difference present in Unipolar and bipolar hemiarthroplasty.

Acetabular erosion is more appeared in unipolar group. 7(23%) patient having acetabular erosion after 2 years in unipolar hemiarthroplasty and 11(9%) patient had bipolar hemiarthroplasty. 7 patient having unipolar hemiarthroplasty had acetabular erosion out of which 2 patients are in grade 2. While all 11 patients with bipolar hemiarthroplasty are in grade

Acetabular erosion grading done by using criteria of baker et al.<sup>8</sup> Mean Harris Hip Score was similar in both unipolar and bipolar hemiarthroplasty at 2 years. In unipolar it was 76.8 and in bipolar it was 78.4.

#### 4. Discussion

Neck femur fractures are common injuries in elderly females. Effective method for the treatment of fracture is necessary due to less successful outcome of conservative treatment.

The aim of this study is to evaluate the results of unipolar hemiarthroplasty and bipolar arthroplasty in neck femur fractures. In bipolar arthroplasty we used only cemented fixed bipolar devices not modular bipolar devices.

There are studies on fixed bipolar prosthesis showing that the bipolar Hemiarthroplasty functions as a unipolar Hemiarthroplasty a few months (3 – 12) after surgery.<sup>12,13</sup> The articulation ceases to function as it was intended and for practical purposes the implant behaves as a unipolar implant. There is dual articulation varies with the diameter of the inner head. Brueton et al.<sup>14</sup> investigated motion

with two bipolar designs, one with a 22-mm inner head and the other with a 32-mm inner head. The prosthesis with the smaller head diameter exhibited predominantly intraprosthetic motion compared with the larger diameter head where motion was mainly extra prosthetic. So, in our study, some of bipolar act as Unipolar devices after a few months. So, usefulness of these devices is questioned.

We had studied 120 patients of neck of femur fracture of which 90 are treated by bipolar hemiarthroplasty and 30 are treated by unipolar hemiarthroplasty. In our study most patients were females and mode of injury was trivial trauma in old age. Austin Moore prosthesis was used in elderly females with morbid conditions. Dislocation are found most common complications in arthroplasty which occurs mostly first 3 month after surgery.

Neck femur fracture in patients of osteoarthritis and rheumatoid arthritis of hip joint are treated with total arthroplasty than hemiarthroplasty. Osteoarthritis is seen more after unipolar arthroplasty then bipolar arthroplasty because of more wear and tear in it.

In unipolar hemiarthroplasty no cementing and reaming was done. Uptake of prosthesis is done with help of graft which is put in fenestration available in Austin Moore prosthesis.

Postoperative mortality following arthroplasty is usually due to cardiopulmonary causes (myocardial infarction or pulmonary emboli). Intraoperative deaths (cardiac arrest) during hip arthroplasty occur infrequently and have been associated with bone cement. Patients with severe underlying cardiovascular disease are more prone. The hemodynamic effects of medullary fat embolism during the process of cement pressurization — rather than the toxic effects of the cement itself — cause this problem. Patient may have acute pulmonary hypertension, hypotension, right ventricular dysfunction, myocardial infarction, and even sudden death. Non cemented arthroplasty produces low intramedullary pressures, fewer emboli and less hemodynamic disturbance.

In our study Unipolar hemiarthroplasty is more effective form of treatment because there is not any reported dislocation in our institution, less operative time which aids benefit for patient with morbid general conditions as well as less chances of infection. There are not any reported cases of deep infection with no any post-operative mortality. There is also cost utility benefit in favor of unipolar hemiarthroplasty because it is less costly and there is no cementing done.

In bipolar hip dislocation, 1st closed reduction under GA was preferred if it was not reduced then open reduction was tried. In case of deep infection, injectable higher antibiotics is used, if it is not curable then debridement is done. If infection persist then Girdle stone arthroplasty is preferred in elderly patients while in young patient antibiotics coated beads were inserted. Girdle stone arthroplasty was done as

last sort of treatment in young inpatient.

This study is essentially preliminary assessment. Study is only a short term follow up with average of 6 months to two years.

## 5. Conclusion

We have studied 120 patients of intracapsular neck of femur fracture with unipolar hemiarthroplasty and bipolar hemiarthroplasty. Unipolar hemiarthroplasty is simple, less operative time, less expensive and has lesser complications than bipolar hemiarthroplasty. Bipolar hemiarthroplasty has more episodes of late revision surgeries than unipolar hemiarthroplasty. Hence Unipolar hemiarthroplasty is best treatment ideal for elderly patients with morbid conditions.

## 6. Source of Funding

None.

## 7. Conflict of Interest

None.

## References

1. Blomfeldt R. Surgical treatment of patients with displaced femoral neck fractures. Aspects on outcome and selection criteria. *Karolinska Institutet*. 2006;.
2. Bhandari M, Devereaux PJ, Tornetta P, Swiontkowski MF, Berry DJ, Haidukewych G. Operative management of displaced femoral neck fractures in elderly patients. An international survey. *J Bone Joint Surg Am*. 2005;87:2122–2130. PubMed.
3. Keating JF, Grant A, Masson M, Scott NW, Forbes JF. Randomized comparison of reduction and fixation, bipolar hemiarthroplasty, and total hip arthroplasty Treatment of displaced intracapsular hip fractures in healthy older patients. *J Bone Joint Surg Am*. 2006;88:249–260. Available from: [10.2106/JBJS.E.00215](https://doi.org/10.2106/JBJS.E.00215).
4. Karagas MR, Lu-Yao GL, Barrett JA, Beach ML, Baron JA. Heterogeneity of hip fracture: age, race, sex, and geographic patterns of femoral neck and trochanteric fractures among the US elderly. *Am J Epidemiol*. 1996;143(7):677–682.
5. Gallagher JC, Melton LJ, BL RR, Bergstrath E. Epidemiology of the fractures of the proximal femur in Rochester, Minnesota. *Clin Orthop Relat Res*. 1980;150:163–171. Pubmed.
6. Varley J, Parker MJ. Stability of hip hemiarthroplasties. *Int Orthop*. 2004;28:274–277. PMC free article.
7. Sullivan NP, Hughes AW, Chesserearly TJ. Complications Following Cemented Modular Hip Hemiarthroplasty. *Open Orthop J*. 2015;9:15–19.
8. Baker RP, Squires B, Gargan MF, Bannister GC. Total hip arthroplasty and hemiarthroplasty in mobile, independent patients with a displaced intracapsular fracture of the femoral neck. A randomized, controlled trial. *J Bone Joint Surg Am*. 2006;88:2583–2589. PubMed. Available from: [10.2106/JBJS.E.01373](https://doi.org/10.2106/JBJS.E.01373).
9. Nilsson A, Bremander A. Measures of hip function and symptoms: Harris hip score (HHS), hip disability and osteoarthritis outcome score (HOOS), Oxford hip score (OHS), Lequesne index of severity for osteoarthritis of the hip (LISOH), and American Academy of Orthopedic Surgeons (AAOS) hip and knee questionnaire. *Arthritis Care Res*. 2011;63(S11):200–207. Available from: <http://onlinelibrary.wiley.com/doi/10.1002/acr.20549/pdf>.
10. Inngul C, Hedbeck CJ, Blomfeldt R, Lapidus G, Ponzer S, et al. Unipolar hemiarthroplasty versus bipolar hemiarthroplasty in patients with displaced femoral neck fractures. A four-year follow-up of a randomised controlled trial. *Int Orthop*. 2013;37:2457–2464.
11. Calder SJ, Anderson GH, Jagger C, Harper WM, Gregg PJ. Unipolar or bipolar prosthesis for displaced intracapsular hip fracture in octogenarians: a randomised prospective study. *J Bone Joint Surg (Br)*. 1996;78:391–394.
12. Phillips TW. The Bateman bipolar femoral head replacement. A fluoroscopic study of movement over a four-year period. *J Bone Joint Surg Br*. 1987;69:761–764. PubMed.
13. Verbeter GH. A femoral head prosthesis with a built-in joint. A radiological study of the movements of the two components. *J Bone Joint Surg Br*. 1983;65:544–547. PubMed.
14. Brueton RN, Craig JS, Hines BL. Effect of femoral component head size on movement of the two-component hemi-arthroplasty. *Injury*. 1993;24(4):231–235.

## Author biography

**Anand Kaushal** Assistant Professor

**Sagarkumar Usdadia** Resident

**Rasik Shiyal** Resident

**Jaimin Patel** Resident

**Dhimant Patel** Resident

**Cite this article:** Kaushal A, Usdadia S, Shiyal R, Patel J, Patel D. Results of Unipolar v/s Bipolar (fixed) prosthesis in hemireplacement arthroplasty in neck femur fractures: A comparative study. *Indian J Orthop Surg* 2019;5(4):258-262.