



## Case Report

# Arthroscopic assisted evacuation of a rare Brodie's abscess in the femoral head of an adolescent girl – A case report

Tashi G Khonglah<sup>1,\*</sup>, Bhaskar Borgohain<sup>1</sup>, Kashif A Ahmed<sup>1</sup>

<sup>1</sup>Dept. of Orthopaedics & Trauma, The North Eastern Indira Gandhi Regional Institute of Health & Medical Sciences, Shillong, Meghalaya, India



## ARTICLE INFO

### Article history:

Received 14-03-2020

Accepted 17-03-2020

Available online 21-04-2020

### Keywords:

Arthroscopic debridement

Bone infection

Brodie's abscess

Head of Femur

Hip joint

Subacute osteomyelitis

## ABSTRACT

Brodie's abscess is a form of subacute osteomyelitis. It is a diagnostic problem because such patients typically have mild local symptoms, few or no constitutional symptoms, and near-normal laboratory values. Though metaphyseal lesions were common in the proximal tibia and proximal femur, these lesions rarely affect the femoral head and neck. We report a case of a 16-year-old girl presenting with a rare Brodie's abscess involving the femoral head that was treated using an arthroscopically assisted curettage of the lesion combined with culture-directed antibiotics. This unusual location would have increased the likelihood of incomplete excision of the diseased tissue and would have led to recurrence. To avoid these risks, we opted for arthroscopic curettage under fluoroscopic guidance using a lateral approach. By this improvised method, there was minimal resection of bone and we found this technique of evacuation safe, uncomplicated and minimally invasive which resulted in early recovery.

© 2020 Published by Innovative Publication. This is an open access article under the CC BY-NC-ND license (<https://creativecommons.org/licenses/by/4.0/>)

## 1. Introduction

A Brodie's abscess is a form of localised subacute osteomyelitis and is known to occur more commonly in children. It is a diagnostic dilemma because such patients typically have mild local symptoms, few or no constitutional symptoms, and near-normal laboratory values. Furthermore, a Brodie's abscess can mimic various benign and malignant conditions, resulting in delayed diagnosis and treatment.<sup>1</sup> Corresponding to the original case series presented by Brodie, this recent systematic review revealed the tibia (48.6%) followed by the femur (31.1%) as the most commonly involved bones.<sup>2</sup> Though metaphyseal lesions were common in the proximal tibia and proximal femur, these lesions rarely affected the head and neck.<sup>3</sup> Till date, there has been only one case report in literature describing a Brodie's abscess of the femoral capital epiphysis.<sup>4</sup> We report a case of a 16-year-old girl who presenting with a rare Brodie's abscess inside the femoral head, that

was subsequently treated by an arthroscopically assisted curettage of the lesion in combination with culture-directed antibiotics.

## 2. Case Report

We report a case of a 16-year old girl attending our out-patient department of a tertiary care hospital of North-East India. She presented with a history of intermittent pain on her right hip for the past 1 year. However, during the preceding 3 weeks, before she attended our hospital, the pain had become more constant and activities, like squatting or sitting, crossed legged caused discomfort. Gradually, with her symptoms becoming more severe, walking was painful. The pain was relieved by lying down and by non-steroidal anti-inflammatory drugs.

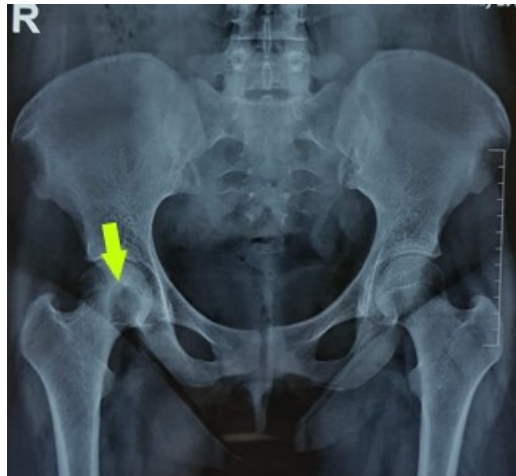On examination, the patient walked with mild right-sided limp. There was tenderness over the right hip joint with restricted and painful terminal movements. There was no limb length discrepancy and no neurovascular deficit. Swelling and erythema were absent and there was no

\* Corresponding author.

E-mail address: [dr\\_tashi@yahoo.com](mailto:dr_tashi@yahoo.com) (T. G. Khonglah).

significant lymphadenopathy. There was no fever, malaise, loss of appetite, weight-loss or trauma. Examination of the opposite hip was normal and so were the findings of the knee joints and the spine.

A laboratory examination revealed a raised erythrocyte sedimentation rate at 92 mm/hour. While C reactive protein was elevated at 14.3mg/L, other hematologic parameters remained normal. A plain anteroposterior view radiograph of the pelvis revealed a discrete predominantly osteolytic, ovoid lesion, with a sclerotic border at the center of the head of the femur (Figure 1).

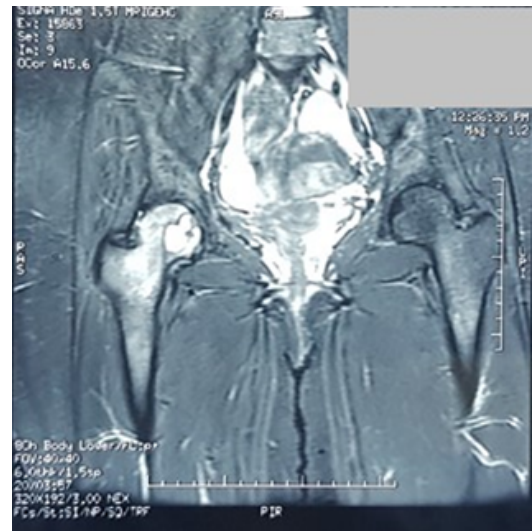


**Fig. 1:** Radiograph of the pelvis showing an osteolytic, ovoid lesion, with a sclerotic border at the center of the head of the right femur (arrow)

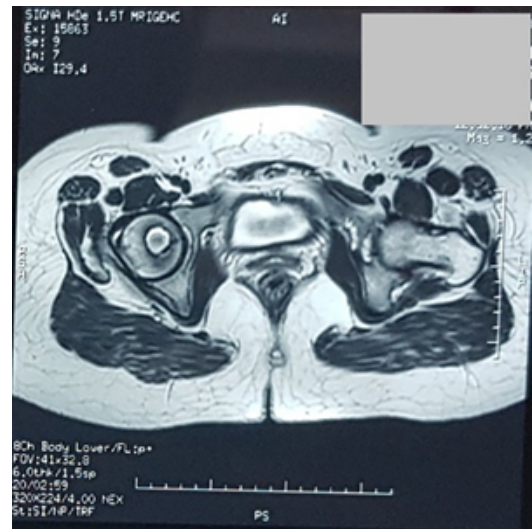
A Magnetic Resonance Imaging study of the hip was performed, and the scan showed a subchondral lobulated T1 W hypointense and a T2 W hypointense lesion measuring 2.1 to 1.3 cm in the head of the right femur. There was peripheral enhancement with central necrotic changes of the lesion. Surrounding edema was also noted in the right proximal femur while the hip joint remained normal (Figures 2 and 3). These radiological features were in favour of an intraosseous Brodie’s abscess located in the head of the right femur.

After discussing the risks and the benefits of the procedure with the patient’s family, surgery was decided for the patient. Under spinal anaesthesia, the patient was placed on an orthopaedic traction table. The lesion was pinpointed under fluoroscopic guidance in both the anteroposterior and in the lateral view. Using a lateral approach, a guidewire was passed in to the lesion. To create space in these tight confines, a triple reamer without the reamer for the barrel plate was used to drill over the guidewire (Figure 4).

Macroscopically, frank pus was draining from the abscess and this was immediately sent for culture and sensitivity. Passing a curette into this deep and narrow space was a challenging task and it was decided then to make

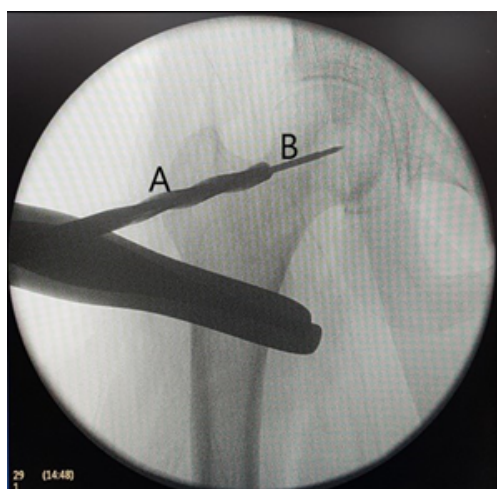


**Fig. 2:** A T2 weighted MRI image with coronal view of the right hip presenting a subchondral lobulated lesion

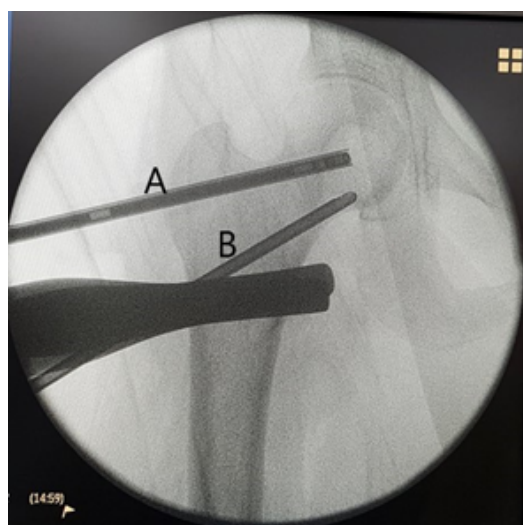


**Fig. 3:** A T1 weighted MRI image showing a bone lesion with rim enhancement and central necrotic changes suggestive of a Brodie’s abscess in the head of the right femur

another converging portal using a guidewire and a triple reamer. These convergent portals were intended to reduce the crowding of the arthroscopic instruments at the site of entry. An arthroscope was passed through the first portal and an arthroscopic shaver via the other distally placed portal (Figure 5). Under gravity, normal saline through the arthroscope was used to flush the infected material from the lesion inside the head of the femur. Simultaneously, suction from the arthroscopic shaver was used to draw out the remaining purulent matter. After thoroughly washing the cavity, the wound was closed over a negative suction drain.

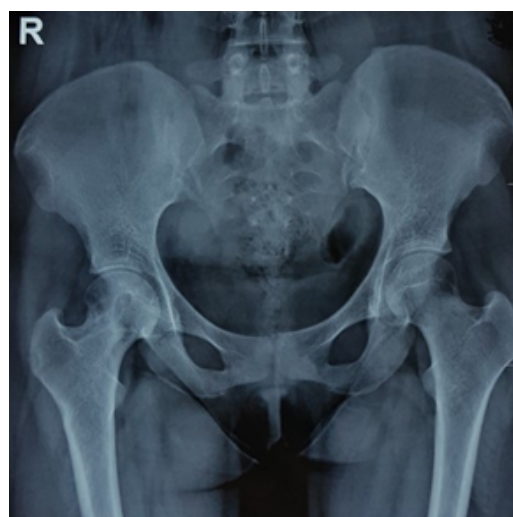

**Fig. 4:** Under fluoroscopic guidance, a triple reamer (A) without the reamer for the barrel plate was used to drill over a guide wire (B) directed at the lesion



**Fig. 5:** Under fluoroscopic guidance, normal saline from an arthroscope (A) was used to flush the infected material while concurrently, suction from the arthroscopic shaver (B) was used to draw out the remaining purulent matter

Postoperatively, microbiological culture identified the organism to be *Staphylococcus aureus*. The patient was treated on intravenous clindamycin for 3 weeks followed by another 3 weeks of oral Clindamycin. During this period, the patient was not permitted to bear weight. Partial weight bearing was allowed only after 6 weeks. At 6 months of follow-up, an anteroposterior radiograph of the hip showed a small persistent bony cavity which had reduced in size and the sphericity of the head of the femur was well maintained (Figure 6). Clinical and haematological examinations were normal by then.



**Fig. 6:** A 6-month follow-up radiograph showing sphericity of the right femoral head maintained

### 3. Discussion

To the authors' knowledge, this is the first case report describing a Brodie's abscess located inside the head of the femur that was subsequently debrided using an arthroscope. This subacute form of hematogenous osteomyelitis accounts for 2.5%–42% of primary bone infections and in general, patients are found to be younger than 25 years of age.<sup>5</sup> Infection persists in this weaker form because of the modified association between the virulence of the bacteria and the resistance of the host. Therefore, signs and symptoms of systemic disease are frequently absent.<sup>1</sup>

Such lesions can develop insidiously with a median of 12 weeks of complaints before diagnosis was established.<sup>2</sup> A Brodie's abscess is often difficult to differentiate from bone tumours both benign and malignant. There have been several pre-operative differential diagnoses including osteoid osteoma, osteosarcoma, chondroblastoma, Ewing's sarcoma, giant cell tumour, fibrosarcoma, eosinophilic granuloma and those of unknown aetiology.<sup>1</sup> These bone infections are seen to occur most often in the vascular rich metaphysis. The incidence of epiphyseal acute and subacute osteomyelitis is extremely rare. Reports of infection involving the knee joint, predominately affect the distal femur or the proximal tibia.<sup>4</sup> Brodie's abscess is rare in the femoral neck.<sup>6</sup> Though conventional radiographs are still the most utilised diagnostic imaging modality for most physicians considering the diagnosis of Brodie's abscess, other techniques such as CT-scan, MRI and nuclear medicine imaging modalities have also been described.<sup>2</sup> Although soft tissue swelling can be identified on radiographs within a few days of onset of infection, bony changes on plain radiographs may not be detected even 5 to 10 days after onset of symptoms.<sup>7</sup> In children,

the modality of choice to distinguish between infection and bone tumours is MRI.<sup>8</sup> As in our patient, Magnetic Resonance Imaging studies of the hip was pivotal in confirming our diagnosis.

The cornerstone of treatment remains primarily surgery with a combination of culture-directed antibiotics. Surgery for lesions about the neck of the femur consisted of drilling and washout under fluoroscopic localisation and rarely an open approach was required.<sup>4</sup> The lesion we encountered was at a depth inside the head of the femur. This uncommon location would have increased the likelihood of partial excision of the diseased tissue and would have led to a recurrence. In the series of Stephen and MacAuley, all three cases of femoral neck lesions recurred after surgical excision and require re-operation.<sup>3</sup> To avoid such hazards, we chose to improvise for a debridement using an arthroscope under fluoroscopic guidance through a lateral approach. With minimal resection of bone, the need for any kind of bone grafting did not arise. After drainage and obtaining material for culture and histology, appropriate potent antibiotic therapy was then required as with any form of osteomyelitis.

With regards to the causative organisms, it has been found that there were two separate forms of primary subacute hematogenous osteomyelitis and they were distinguished based on the age of the patient and bacteriological etiology. The infantile form affects children aged between 6 months and 4 years and is predominantly due to *K. kingae*. The juvenile form involves children aged >4 years and *Staphylococcus aureus* appears to be the main bacterial aetiology. Other organisms such as *Streptococcus*, *Pseudomonas*, *Haemophilus influenza*, *Mycobacterium tuberculosis* may be encountered.<sup>9</sup> Brodie's abscesses, in particular, have an established relationship with staphylococcal infections.<sup>10</sup> Similarly, in our study the causative organism was *Staphylococcus aureus*.

#### 4. Conclusion

Our case report is the first to document a Brodie's abscess inside the head of the femur. With similar lesions known to mimic bone tumours, a comprehensive workup is important. This unusual location of the abscess at a depth, inside the head of the femur presented us with a tough challenge. We found that this technique of arthroscopic assisted evacuation was safe, uncomplicated and minimally invasive. A detailed planning of the procedure and the use of precise instruments was critical to ensure success.

#### 5. Key Messages

1. A Brodie's abscess inside the femoral head is a rare presentation

2. In children, the modality of choice to differentiate between infection and bone tumours is magnetic resonance imaging.
3. Arthroscopic curettage of these lesions in the femoral head under fluoroscopic guidance is safe and minimally invasive.

#### 6. Source of Funding

None.

#### 7. Conflict of Interest

None.

#### References

1. Cottias P, Tomeno B, Anract P, Vinh TS, Forest M. Subacute osteomyelitis presenting as a bone tumour. *Int Orthop*. 1997;21(4):243–8.
2. van der Naald N, Smeeing DPJ, Houwert RM, Hietbrink F, Govaert GAM, van der Velde D. Brodie's Abscess: A Systematic Review of Reported Cases. *J Bone Jt Infect*. 2019;4(1):33–9.
3. Stephens MM, Macauley P. Brodie's abscess. A long-term review. *Clin Orthop*. 1988;(234):211–7.
4. Hourston GJ, Kankam HK, Mitchell PD, Latimer MD. Brodie abscess of the femoral capital epiphysis in a 2-year-old child caused by *Kingella kingae*. *BMJ Case Rep*. 2017;doi:10.1136/bcr-2016-217663.
5. Craigen MA, Watters J, Hackett JS. The changing epidemiology of osteomyelitis in children. *J Bone Joint Surg Br*. 1992;74-B(4):541–5.
6. Schlur C, Bachy M, Wajfisz A, le Pointe HD, Josset P, Vialle R. Osteoid osteoma mimicking Brodie's abscess in a 13-year-old girl. *Pediatr Int Off J Jpn Pediatr Soc*. 2013;55(2):e29–e31.
7. Yeo A, Ramachandran M. Acute haematogenous osteomyelitis in children. *BMJ*. 2014;348. doi:10.1136/bmj.g66.
8. Jaramillo D, Dormans JP, Delgado J, Laor T, Geme JWS. Hematogenous Osteomyelitis in Infants and Children: Imaging of a Changing Disease. *Radiol*. 2017;283(3):629–43.
9. Spyropoulou V, Chargui AD, Merlini L, Samara E, Valaikaite R, et al. Primary subacute hematogenous osteomyelitis in children: a clearer bacteriological etiology. *J Child Orthop*. 2016;10(3):241–6.
10. Ruttan TK, Higginbotham E, Higginbotham N, Allen CH, Hauger S. Invasive *Kingella kingae* Resulting in a Brodie Abscess. *J Pediatr Infect Dis Soc*. 2015;4(2):e14–6.

#### Author biography

**Tashi G Khonglah** Assistant Professor

**Bhaskar Borgohain** Professor

**Kashif A Ahmed** Senior Resident

**Cite this article:** Khonglah TG, Borgohain B, Ahmed KA. Arthroscopic assisted evacuation of a rare Brodie's abscess in the femoral head of an adolescent girl – A case report. *Indian J Orthop Surg* 2020;6(1):50–53.