



## Original Research Article

## Clinical and functional outcome of proximal humerus fractures treated with locking compression plate (LCP) in adults – A prospective study

Janapamala V S Kishore<sup>1,\*</sup>, Prashant Tonape<sup>1</sup>

<sup>1</sup>Dept. of Orthopaedics, Sterling Multispeciality Hospital, Pune, Maharashtra, India



## ARTICLE INFO

## Article history:

Received 13-09-2020

Accepted 19-09-2020

Available online 30-12-2020

## Keywords:

Proximal humerus fracture

Locking compression plate

Constant murley score

internal fixation

## ABSTRACT

**Aim:** To evaluate the outcome of open reduction and internal fixation using locking compression plate for proximal humeral fractures, done at a tertiary care referral teaching super specialty hospital in Andhra Pradesh, India from 1<sup>st</sup> may 2015 to 31<sup>st</sup> may 2017.

**Materials and Methods:** The study consists of 53 patients diagnosed with proximal humerus fractures which were treated by open reduction and internal fixation with locking compression plate in a week after trauma, with in the age group of 20-60 years were selected. All patients were preoperatively evaluated with radiographs and CT 3D reconstructions. Post operatively their prognosis assessed by 100 point Constant-Murley scoring system. After attrition, to loss of follow-up, 49 patients followed for minimum 1 year. Their results were analyzed including complications.

**Results:** At the end of one year, sixteen patients (32.65%) had excellent outcome with scores between 86-100, twenty five patients (51.02%) were functionally good with scores between 70 and 85. Seven patients (14.28%) had scores between 56 and 70, which according to the literature is a fair result. One patient (2.04%) had scores less than 55 points and was graded poor. The Mean Constant-Murley shoulder score was 82.85, thereby falling in the good outcome category.

**Conclusion:** The Proximal humerus Locking Compression plating (LCP) technique gives moderate to excellent results in cases with proximal humerus fractures, depending on the fracture pattern. Those who were treated with early fixation and early mobilization were found to have a better functional outcome irrespective of the fracture type. Good surgical results can only be obtained by vigorous physiotherapy imparted by an expert team and strong motivation from the patient side. The results obtained with using Locking Compression Plates (LCP) were comparable to Proximal Humerus InterLocking System (PHILOS) plates except for varus collapse being common complication while using former for internal fixation.

© This is an open access article distributed under the terms of the Creative Commons Attribution License (<https://creativecommons.org/licenses/by/4.0/>) which permits unrestricted use, distribution, and reproduction in any medium, provided the original author and source are credited.

### 1. Introduction

Proximal humerus fractures are one of the commonest fractures occurring in the skeleton representing approximately 4% of all fractures and 26% of humerus fractures.<sup>1</sup> They trail behind only femoral neck and distal radius as the third most common fracture in patients older than 65 years.<sup>2</sup>

Fractures that occur in the elderly usually result from a trivial fall on an outstretched hand or the side of the

shoulder. Younger patients with these injuries are more likely due to high energy trauma following road traffic accidents and present with significant associated injuries.<sup>3</sup> They occur more commonly in elderly patients, after cancellous bone of the humeral neck has weakened by senility but these fracture are seen in patients of all ages & merge with epiphyseal separations. The most serious fractures and fracture dislocations are often seen in active, middle aged patients. These fractures can be extremely disabling and their management often demands experienced surgical skills and judgment.<sup>4</sup>

\* Corresponding author.

E-mail address: [drjvsatyakishore@gmail.com](mailto:drjvsatyakishore@gmail.com) (J. V. S. Kishore).

Codman first recognized that proximal humerus fractures in adults occur along the lines of old physal scars, with injury patterns involving four segments. Neer refined Codman's classification scheme by emphasizing the degree of displacement or angulations of an anatomical segment and was published in 1975. The AO/ASIF proposed a classification scheme based on vascular supply to the articular surface of the proximal humerus to predict the risk of avascular necrosis.<sup>5</sup> The final management decision should not be based solely on the presence of number of fracture fragments as dictated by the classification systems described. Instead, they must be individualized on the basis of age, associated injuries, and functional demands of the patient and fracture characteristics. In elderly patients, restoration of muscle power to the injured arm is not the prime objective. The main requirement is to achieve activities of daily living which do not need much strength, but require a reasonable range of movement.<sup>6</sup>

However, till now very limited prospective studies have been done describing the functional outcome, long term of preoperative surgical delay and complications following locking plate fixation of proximal humeral fractures in rural Indian population where flurosia is endemic, which corresponds to the population in this study.

## 2. Materials and Methods

This is a prospective observational, cohort study comprising of forty nine patients with proximal humerus fractures who were treated with Proximal humeral locking compression plate at our department of orthopaedics, a tertiary care referral teaching super specialty hospital between the period of 1<sup>st</sup> May 2015 to 31<sup>st</sup> May 2017. As the case load in our hospital in a given study period is 52 and after attrition by loss of follow up for 3 cases, the remaining sample size was 49 cases. They were followed for minimum period of 1 year.

### 2.1. Inclusion criteria

1. Patients in the age group of 20-60 years.
2. All cases of closed proximal humeral fractures (Closed two-part fracture with humeral diaphyseal extension or three or four-part fracture having a tuberosity displacement enough to cause a significant sub-acromial impingement).

### 2.2. Exclusion criteria

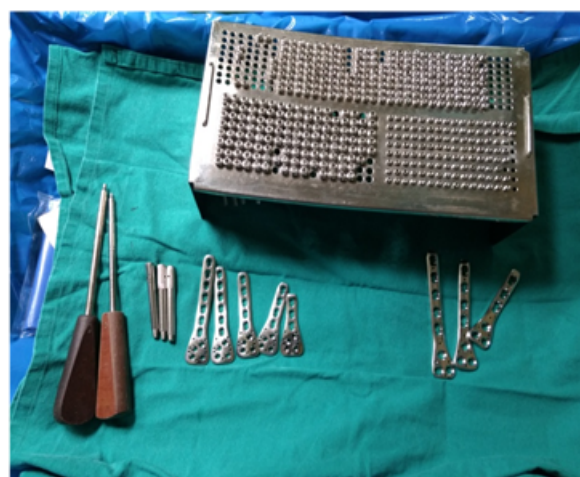
1. Skeletally immature patients.
2. Age > 60 yrs.
3. Patients with distal neurovascular deficits.
4. Patients with open fractures.
5. Pathological fractures.
6. Terminally ill patients with multiple medical comorbidities.

The selected patients were distributed into NEER 2 part, 3 parts and 4 part grades according to radiological analysis. Patients' consent obtained for participation in the study. Patients operated by 4 orthopaedic consultants at our tertiary care hospital with open reduction and internal fixation by proximal humerus locking compression plate through standard Delto-pectoral approach with patient in beach chair position. Provisional fixation of fracture done by K-wires under C-Arm guidance, over which the LCP is fixed and closure of surgical wound done after assessing that there is no screw penetration into sub-chondral bone. Patients were discharged on 2<sup>nd</sup> post operative day, on oral antibiotics for 4 days and asked to follow standardized supervised OPD based physiotherapy at hospital as per protocol. Patients were regularly followed up after 2 weeks, 6 weeks, 3 months, 6 months and 1 year.

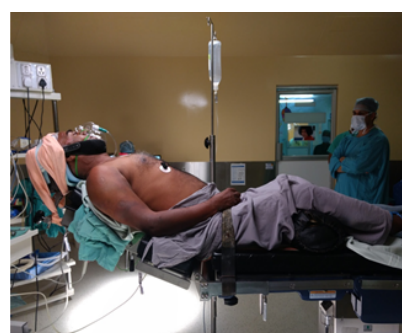Constant-Murley scoring (100 point scoring system) assessment includes subjective complaints and clinical signs

The subjective complaints assessed were Pain(15 points) and activities of daily living(20 points).

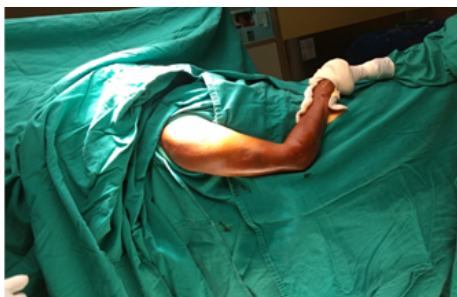The clinical signs assessed were range of motion(40 points) and power based on MRC grading(25 points).



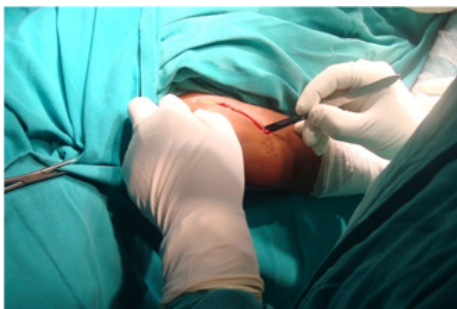**Fig. 1:** Implants and instruments used for fracture fixation



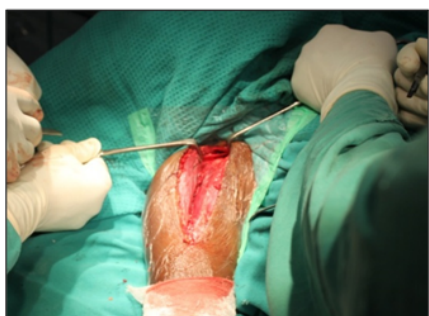**Fig. 2:** Beach chair position for hand to lie on arm rest



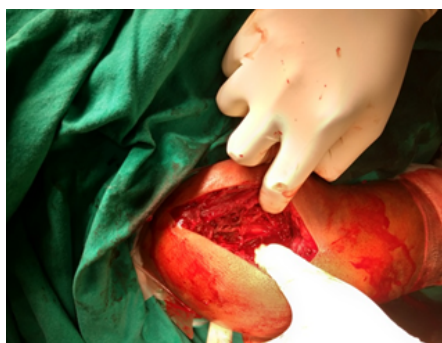**Fig. 3:** During draping



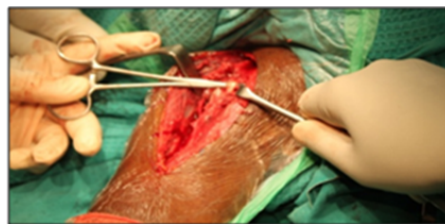**Fig. 4:** Delto-pectoral incision



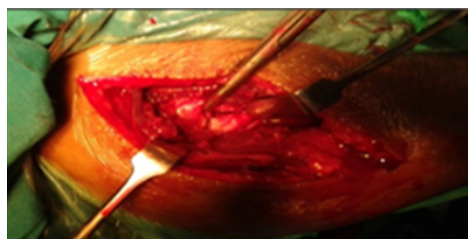
**Fig. 5:** Explore of the delto-pectoral interval



**Fig. 6:** Splitting few anterior fibers of deltoid



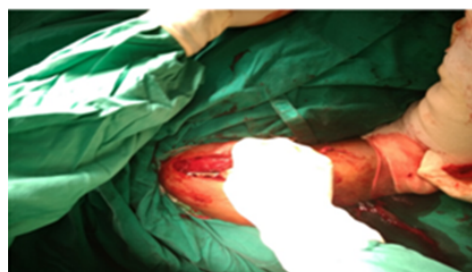**Fig. 7:** Identifying the log head of biceps



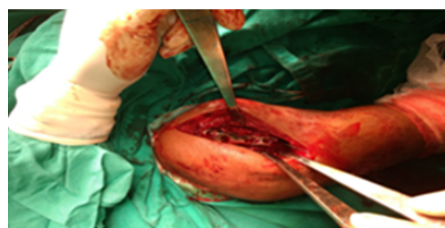**Fig. 8:** After deep surgical dissection showing the fracture site



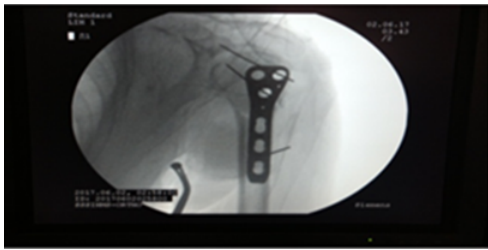**Fig. 9:** C-arm position to assist fracture fixation intra-operatively



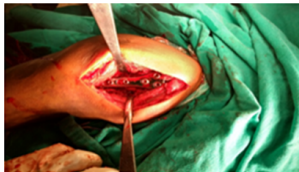**Fig. 10:** Insertion of LCP plate on to the bone



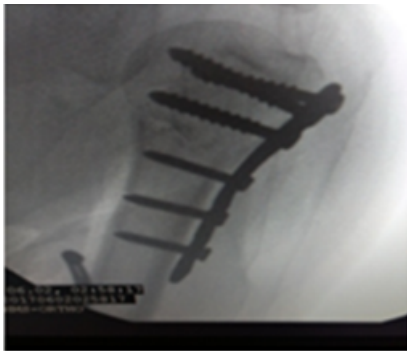**Fig. 11:** Provisional fixation of fracture with K wires and LCP in situ



**Fig. 12:** Positioning of the plate using image intensifier with K wires



**Fig. 13:** Fracture fixation with plate in-situ



**Fig. 14:** After final fixation of plate with K wires removed

**3. Results and Analysis**

Trivial non velocity injury in 25 patients and motor vehicle accidents in 20 patients are the major cause. Electric shock (1 patient) and fall from height (3 patients) are minor causes.

**Table 1:** Grading based on Constant- Murley score

Grading	Constant score	Patients number	Percentage
Excellent	86-100 points	16	32.65%
Good	71-85 points	25	51.02%
Moderate	56-70 points	7	14.28%
Poor	0-55 points	1	2.04%

At the end of one year, sixteen patients (32.65%) had excellent outcome, twenty five patients (51.02%) were functionally good and seven patients (14.28%) had scores between 56-70, which according to the literature is a fair result. One patient (2.04%) had scores less than 55 points and were graded poor. The mean Constant-Murley shoulder score was 82.85, thereby falling in the good outcome

category.

**Table 2:** Number of patients in each Neer’s grade and mean Constant Murley score as per neer’s class at 1 year follow up.

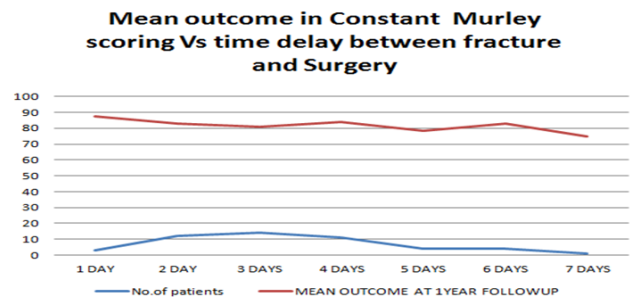
Neers fracture class	Number of patients	Constant score
2 part fracture	15	85.06
3 part fracture	23	82.78
4 part fracture	11	80.09

The average outcome after 1 year follow-up as per Neer’s classification shows excellent outcome for two part fracture (mean constant score = 85.06). While three part Fractures have average outcome. (mean constant score = 82.78). The 4 part fractures have poor outcome (mean constant score = 80.09). However, the difference in outcomes is minimal and not statistically significant.

**Table 3:** Time delay between fracture and surgery days and comparing its outcome at end of 1 year follow-up

Fracture to surgery delay	No. of patients	Constant Murley score at 1 year follow up
1 day	3 (6.12%)	87.33
2 days	12(24.48%)	82.75
3 days	14 (28.57%)	80.64
4 days	11(22.44%)	84.09
5 days	4(8.16%)	78.5
6 days	4(8.16%)	83
7 days	1 ( 2.04%)	75

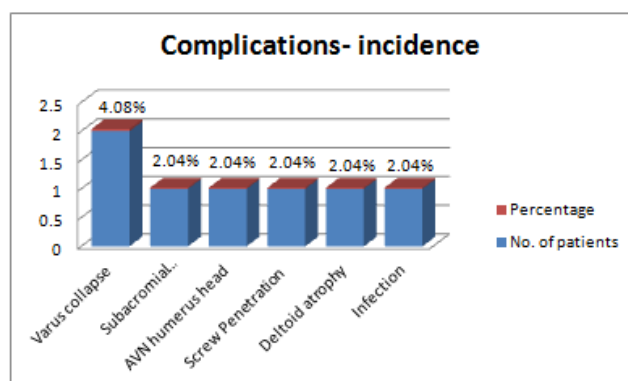
The mean outcome at the end of 1year follow-up shows that there is decrease in the mean Constant-Murley score gradually towards the longer interval between fracture to surgery delay.



**Graph 1:** When comparing the mean outcome at 1 year of age with time delay in days preoperatively they seem to be inversely corresponding as the delay between fracture and surgery increases the mean outcome decreases.

**3.1. EA although it’s statistically insignificant**

Complications encountered in this study include varus collapse in two patients (4.08%), subacromial impingement



Graph 2: Incidence of complications over 1 year follow-up

in one patient (5%), AVN humeral head In one patient (2.04%), persistent shoulder stiffness and deltoid atrophy in one patients (10%), screw penetration in one patient, late onset infection in one diabetic patient (2.04%). Penetrated screw has been removed after two weeks post op percutaneously, Implant removal was done in infected diabetic patient in view of failed and exposed implant at 1 year follow up.

Complications like nonunion were not reported in our series of patients, because only limited number of cases formed the study cohort.

#### 4. Discussion

Beate Hanson et al.,<sup>6</sup> in their series of 160 patients, 65 patients (40.6%) had sustained fractures following slip and fall on their outstretched hand or on their shoulder and 10 patients (6.3%) had sustained fractures due to high velocity road traffic accidents. In our series of 49 patients, 20 patients (40.81%) sustained fractures following high velocity road traffic accidents. 25 patients (51.02%) sustained fractures, which resulted from axial loading during a trivial domestic fall on an outstretched hand or on the side of the shoulder. Three younger patients (20%) sustained injury due to fall from height accidents . One patient had electric shock.

Neer et al.,<sup>7</sup> in their series of 43 patients treated with open reduction and internal fixation with plate and screws showed good to excellent results in 48% of cases. For patients with 3-part fractures, plating techniques resulted in the best outcomes, as measured by the Neer pain scoring systems. In our series of 49 operative patients, majority of the patients (83.67%) had fair to good results. Excellent outcome was registered in sixteen (32.65%) patients and only one patient (2.04%) having poor results. Poor results were mainly due to poor patient compliance and failure to attend regular physiotherapy.

Three-part fractures were the most common [23 patients]. 83 % of our patients had moderate to excellent

results following LCP plate fixation. Patients were followed up for a mean duration of 12 months. The average time taken for fracture healing was 15 weeks. The mean Constant-Murley shoulder score was 82.85 points after 1 year follow up and was categorized as having good outcome. Our patients were able to achieve a good functional range of movement, averaging 110.5° flexion, 81.75° abduction and rotations (internal and external) ranged between 30° and 45°.

Misra A et al.,<sup>8</sup> in their series of patients treated with internal fixation, 76% had better pain relief and 67% patients had good functional range. In our series of 49 operative patients, 85% had excellent pain relief and rest 13% have average outcome. 2% had poor functional outcome

Lu et al.<sup>9</sup> treated 39 proximal humerus fractures including isolated 2-part GT fractures with ORIF after a delay of 21-120 days from initial injury, ROM were improved except for internal rotation and all of the evaluated scores including visual analogue score, Constant – Murley score , university of California Los Angeles(UCLA) scoring system and Simple Shoulder score demonstrated great reconstruction. In our study patients were operated with in a week and delay within a week does not effect the shoulder outcome to a statistically significant value, although a trend towards decrease in long term outcome was noted with increasing preoperative surgical delay. To the best of our knowledge, there are few studies discussing delayed treatments of GT fractures and we did not find enough evidence to help surgeons to decide whether late surgery can achieve satisfactory outcome or not.

Sameer Aggarwal, Mandeep Dhillon et al.,<sup>10</sup> also noted varus malalignment and collapse in 5 out of 56 patients in their study, of which three underwent revision surgery with implant removal and new PHILOS plate; and two underwent shoulder hemiarthroplasty at a later date.

Koval et al.,<sup>11</sup> in their series of cases pointed out that the use of plates required more extensive soft tissue stripping, which may increase the risk of osteonecrosis. In our series, operative patients treated with plate fixation had one case (2.04%) with features suggestive of osteonecrosis at the end of one year, though our series had a small number of cases in exclusion criteria.

In our series, we encountered two patients with varus collapse during post-operative follow-ups. No revision surgeries were performed in both cases, were treated with U-cast application for 6 weeks, and both patients attained adequate functional outcomes after one year and were able to resume doing their daily household activities satisfactorily. In conjunction with this complication, we would like to highlight the critical importance of placing an inferomedial, strut or kickstand screw for fractures with metaphyseal comminution and a missing medial calcar portion which were available with newer implants like

PHILOS, a lagging feature of locking compression screws.

In our study one case of screw perforation with severe pain in the shoulder was noted at 2 weeks post op. Issue addressed with screw removal in operation theatre percutaneously, leaving implant in situ followed by mobilization of the joint. we realized that the best way to avoid this was to get confirmatory radiographs throughout the arc of rotation (maximum internal to maximum external rotation) after the hole has been drilled (with drill bit in-situ) to get the exact length of the screw and we preferred to put a smaller sized screw whenever the length measured fell between the two screw sizes.

Subacromial impingement occurred in one patient with painful restriction of abduction at 60°. However, with time, the patient improved and plate removal was done after the fracture had united at 12 months. Shoulder stiffness was noted in one patients at 8 weeks post operatively, which improved with regular, intensive physiotherapy. There was no incidence of Nonunion of humeral head. None had axillary nerve palsy pre or post-operatively and no secondary bone grafting was required. The results obtained in our study are comparable with the results obtained by other authors

### 5. Case Study 1

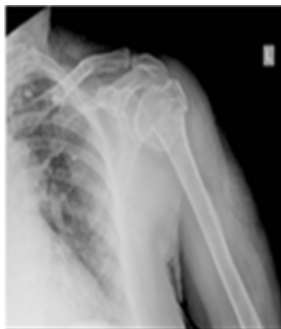

Fig. 15: Pre OP x-ray

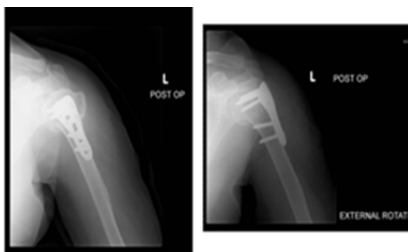


Fig. 16: Post OP x-ray

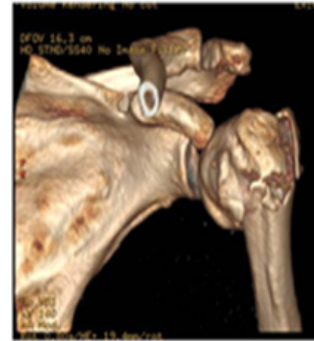


Fig. 17: Pre OP CT



Fig. 18: Forward flexion

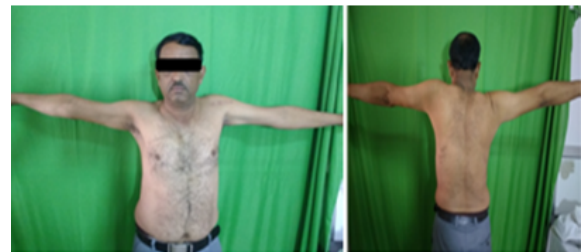

Fig. 19: Abduction (lateral extension)

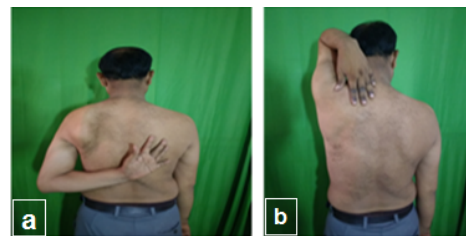
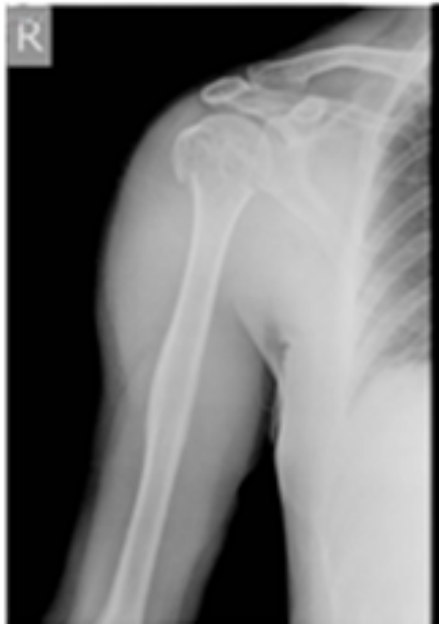

Fig. 20: a: Internal rotation; b: External rotation

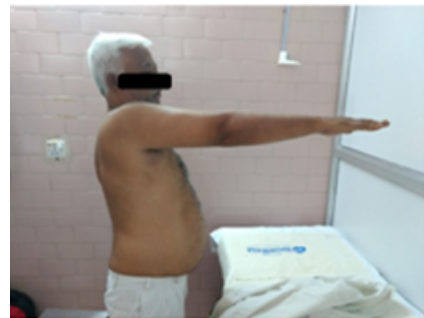### 6. Case Study 2

### 7. Conclusion

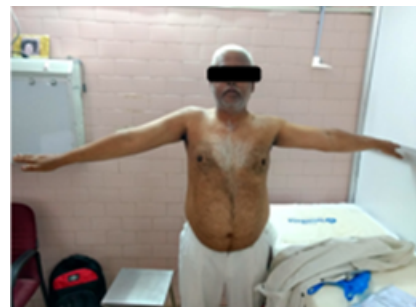The Proximal humerus Locking Compression plating (LCP) technique gives moderate to excellent results in cases with proximal humerus fractures, depending on the fracture pattern. Those who were treated with early fixation and early mobilization were found to have a better functional outcome irrespective of the fracture type. Operative



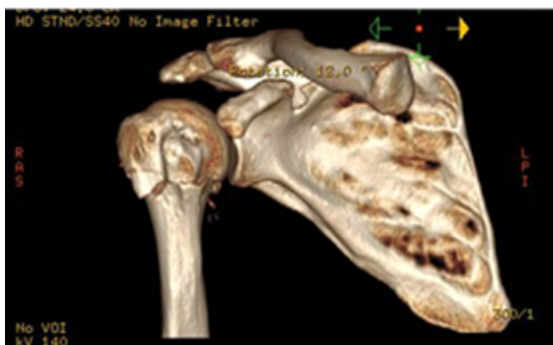**Fig. 21:** Pre OP x-ray



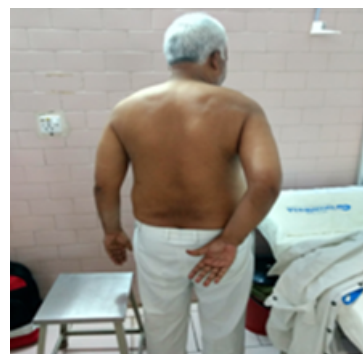**Fig. 24:** Foreword flexion



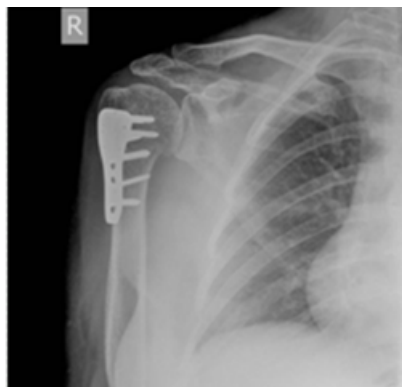**Fig. 25:** Abduction



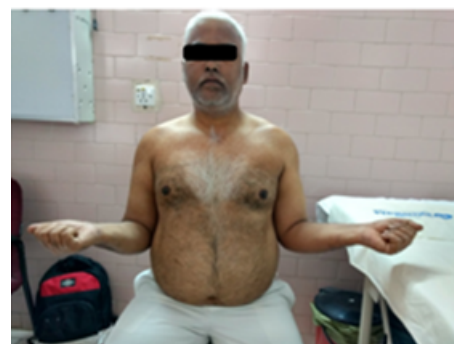**Fig. 22:** Pre OP CT



**Fig. 26:** Internal rotation



**Fig. 23:** Post OP AP view



**Fig. 27:** External rotation

treatment demands increased surgical competence, strict adherence to locking plate principles and requires a complete armamentarium of equipment to deal with such fractures. Good surgical results can only be obtained by vigorous physiotherapy imparted by an expert team and strong motivation from the patient side.

## 8. Source of Funding

None.

## 9. Conflict of Interest

None.

## References

1. Thyagarajan DS, Haridas SJ, Jones D, Dent C, Evans R, Williams R, et al. Functional outcome following proximal humeral interlocking system plating for displaced proximal humeral fractures. *Int J Shoulder Surg.* 2009;3(3):57–62.
2. Rockwood CA, Matsen FA, Wirth MA, Lippitt SB. Philadelphia: Saunders. and others, editor; 2009.
3. Neer CS, Rockwood CA. Fractures and dislocations of the shoulder ; 1984.
4. Hertel R, Hempfing A, Stiehler M, Leunig M. Predictors of humeral head ischemia after intracapsular fracture of the proximal humerus. *J Shoulder Elbow Surg.* 2004;13(4):427–33.
5. Robinson CM. Proximal humerus fractures. Bucholz R, Brown CMC, Heckman J, Tornetta P, editors. Philadelphia: Lippincott Williams & Wilkins; 2010.
6. Hanson B, Neidenbach P, de Boer P, Stengel D. Functional outcomes after nonoperative management of fractures of the proximal humerus. *J Shoulder Elbow Surg.* 2009;18(4):612–21.
7. Neer CS. Treatment of 3-part and 4-part displacement. *J Bone Joint Surg Am.* 1970;52(6):1090–103.
8. Misra A, Kapur R, Maffulli N. Complex proximal humeral fractures in adults — a systematic review of management. *Injury.* 2001;32(5):363–72.
9. Lu Y, Jiang C, Zhu Y, Wang M, Bowles RJ, Mauffrey C, et al. Delayed ORIF of proximal humerus fractures at a minimum of 3 weeks from injury: a functional outcome study. *Eur J Orthop Surg Traumatol.* 2014;24(5):715–21.
10. Aggarwal S, Bali K, Dhillon MS, Kumar V, Mootha AK. Displaced proximal humeral fractures: an Indian experience with locking plates. *J Orthop Surg Res.* 2010;5(1):60.
11. Koval KJ, Gallagher MA, Marsicano JG, Cuomo F, Mcshinawy A, Zuckerman JD, et al. Functional Outcome after Minimally Displaced Fractures of the Proximal Part of the Humerus\*. *J Bone Joint Surg Am.* 1997;79(2):203–7.

## Author biography

**Janapamala V S Kishore**, Fellow

**Prashant Tonape**, Consultant

**Cite this article:** Kishore JVS, Tonape P. Clinical and functional outcome of proximal humerus fractures treated with locking compression plate (LCP) in adults – A prospective study. *Indian J Orthop Surg* 2020;6(4):328-335.