

## Volar Barton fracture: Treatment Comparison of Plating and External fixation with Kirschner wires

Jayant Sharma<sup>1</sup>, Prashant Upadhyaya<sup>2\*</sup>

<sup>1</sup>Associate Professor, Index Medical College Indore

<sup>2</sup>DNB resident, Unique Super Speciality Hospital Indore.

**\*Corresponding Author:**

E-mail: jayantjaikishansharma@gmail.com

### Abstract

**Background:** Distal radius fractures are commonly seen and have various treatment methods available in literature hence, a clear consensus could not be reached as to the most ideal modality of management. With advent of buttress plates, open plating has become a treatment of choice in young adults whereas Kirschner wire fixation with external fixator application have achieved good results in osteoporotic and medically compromised patients.

**Methods:** Twenty eight patients of distal Radius fractures with volar Barton pattern came to us were either treated by open reduction and plating (16cases) and 12 cases were treated by Kirschner wire fixation with external JESS fixation, with an average follow-up of 18 months (range, 12-24 months).

**Results:** All the patients had union achieved without any major complications in plating patients (12 out of 16) and 10 out of 12 cases of Kirschner wires with JESS (p=.05)

**Conclusion:** Surgical techniques discussed here are the two standard procedures with a long follow up, also in the literature are proven to be effective treatment modalities, and are found to give the best possible result with least complication rates. Despite the fact that each technique has its own advantages and side effects, whereas results from the plating treatment seem to be best suited for patients who have minimal comminution and are heavy workers and need to join their working soon. Whereas the Kirschner wire and JESS was suited for comminuted fractures and osteoporotic fractures.

**Key words:** Volar Barton's fracture, Buttress plate, External fixation, JESS distractor, Kirschner wire.

Access this article online	
<b>Quick Response Code:</b> 	<b>Website:</b> www.innovativepublication.com
	<b>DOI:</b> 10.5958/2395-1362.2016.00002.5

### Introduction

Of the commonly seen fractures in OPD practice and mainly due to fall on outstretched hand Distal end Radius form the major group. These may be either a Barton or a Colle's fracture as per old nomenclature, but now a days are classified as per the **Frykmann's Classification**. **type I:** transverse metaphyseal fracture this includes both a Colles and Smith fracture as angulation is not a feature, **type II:** type I + ulnar styloid fracture, **type III:** fracture involves the radiocarpal joint this includes both a Barton and reverse Barton fractures, **type IV:** type III + ulnar styloid fracture, **type V:** transverse fracture involves distal radioulnar joint, **type VI:** type V + ulnar styloid fracture, **type VII:** comminuted fracture with involvement of both the radiocarpal and radioulnar joints, **type VIII:** type VII + ulnar styloid fracture).

Volar Barton fractures are not uncommon in our daily trauma OPD and may be due to high or low energy injuries. These fractures have a bimodal distribution, in old age it is seen as an osteoporotic

fracture and low energy trauma, and in young adults, it is usually a high energy trauma. (1,2) Such fractures are considered as unstable and treatment options available in literature, vary from closed reduction and plaster application or pin fixation and plaster or External fixation to plating with or without bone grafting (3,4). Surgical treatment is favoured in these fractures though various success rates have been mentioned in literature. (4, 5)

Presently, closed reduction with external fixation and percutaneous Kirschner pinning or open reduction with volar buttress plating have achieved most desired outcome functionally and radiologically. (4-6). Surgical treatment for Volar Barton's fractures are numerous but, there are few studies that compare both the techniques hence we took up this study in order to compare treatment and designate the indications of the type of treatment best suited for which type of fracture pattern.

### Methods

Patients selected for the study were received in our OPD from January 2013 to August 2015, 28 adult patients (>16 years) with Distal radius fractures were treated by us. This study did not include fractures with distal Ulna fractures associated, or carpal bone fractures and cases of poly trauma where sometimes the definite treatment got delayed.

Twenty eight fractures of volar Barton pattern (type 3 Frykmann) were included in this study (5,6)

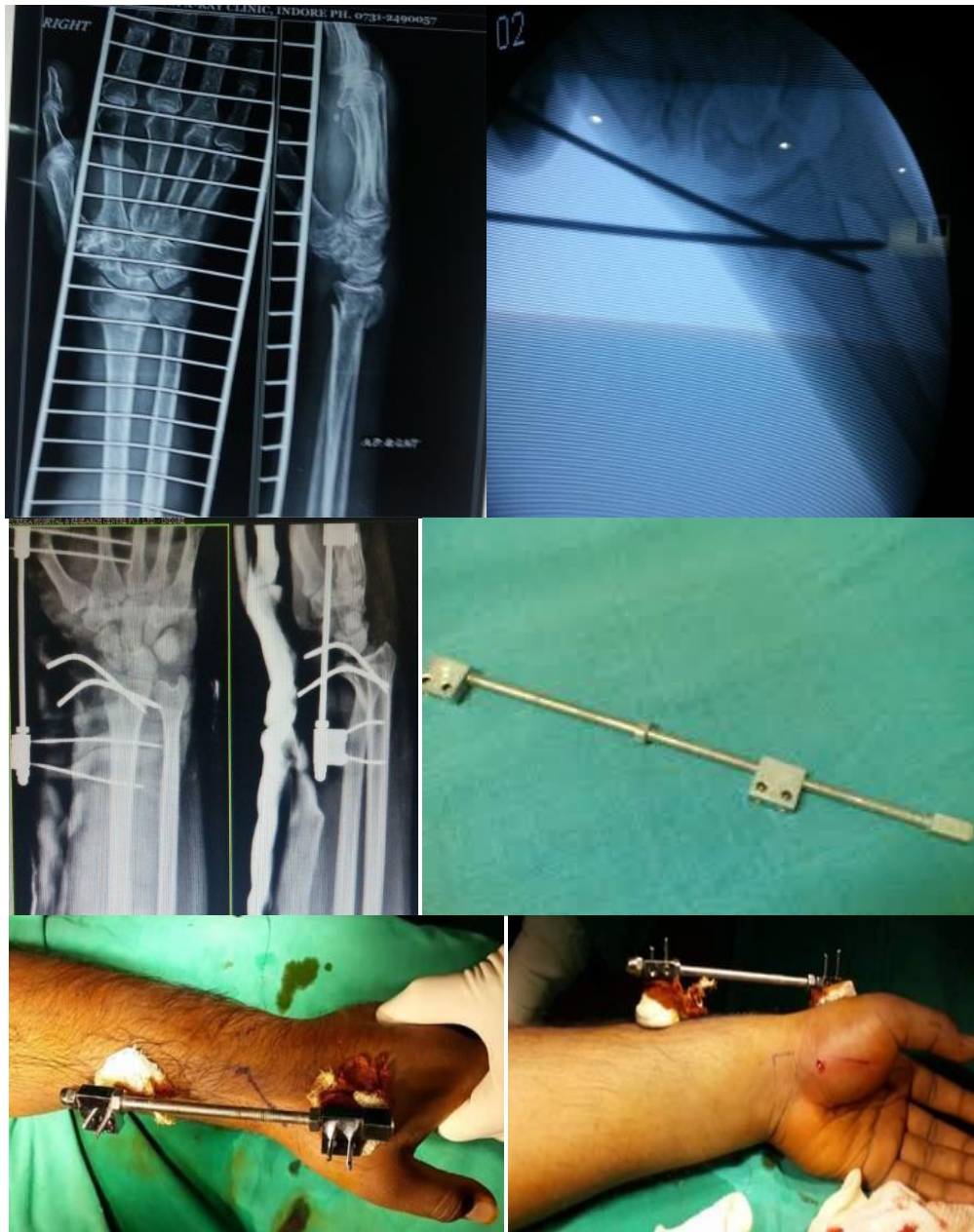
Fracture pattern showed a bimodal type of distribution with patients of age from 24 to 72 years (mean age of 48 years) preponderance of male patients in younger age group and older patients had a female preponderance. In the ratio of two is to one.

The mode of injury was motor vehicle accident in 13 cases in young adults, tripping over was the mode of injury in older age group. All the fractures were closed(7) Fourteen fractures were in the dominant extremity. In the OPD, the patient's vitals were first stabilized then the fracture was immobilized by a Below elbow slab. All these fractures were treated within 48 hours of injury, reduction of initial swelling

was obtained by ice fomentation, limb elevation and anti inflammatory medication. The treatment option was surgeon's personal experience and opinion regarding that fracture pattern, and as was done within 48hours didn't affect the achievement of reduction.

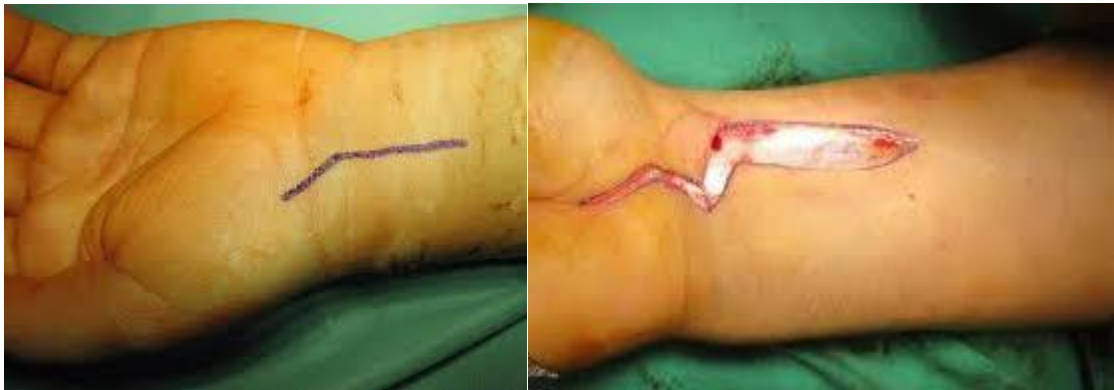### Surgical Technique

All the patients were given Brachial Block Anaesthesia, and linear manual traction was given by three fingers and thumb. The volar fragment is pushed back by forceful manipulation, then 2.0 mm Kirschner wire is introduced through radial styloid process to the ulnar side of the proximal cortex.

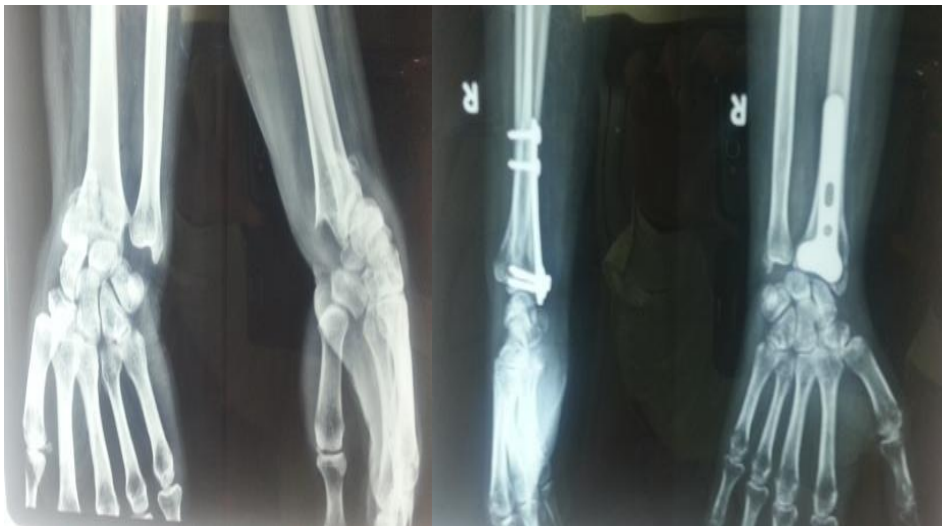

External fixator, of Joshi's external stabilizing system (JESS type of Distractor) (fig1) was applied to bridge the wrist joint and enforce wrist stability, This distractor helped in assisting distracting and reducing the fracture.

The Ellis approach (fig2.) was used for open reduction wrist joint was opened at the volar aspect. (8) The dissection was extended between the Flexor carpi radialis and the Palmaris longus. The Radial artery was identified and secured and the median nerve was shifted ulnar ward. Pronator Quadratus was cut from the radius.



Volar fragment was reduced using indirect method of reduction by placing a towel beneath and that it self-provided with the traction pull required to reduce the fracture along with a 5mm osteotome under direct vision and a buttress plate was applied to the volar aspect. In few instances the plate had to be bent about 10 degrees, volarward tilting and a short arm splint was applied.



The hand was kept in ulnar deviation and slight flexion.

After two weeks, the splint was removed and a functional brace was applied until the fracture got united. For those patients of the external fixation with Kirschner wire or short arm splint was removed after six weeks.

Active wrist range-of-motion exercises were started with the help of a physiotherapist. Progressive weight loading of the wrist was permitted over a period of two weeks. Patients were followed-up at the Outpatient Department after six weeks, three months, one year and eighteen months. The bony and the radiographical healing progress were recorded.

The wrist function was evaluated with Pattee and Thompson criteria, and a satisfactory outcome included an excellent or good grade.(3)

An excellent result had no pain, no disability and no more than 5° loss of wrist flexion or extension; a good result had occasional mild pain, no disability and 15° or less loss of wrist flexion or extension; fair results had mild to moderate pain, modification of certain activities, continued employment at the preinjury occupation and 25° or less loss of motion; and poor results had severe pain, residual disability requiring occupation change and more than 25° loss of motion. Statistic analysis for a significant statistical difference was set at  $p < 0.05$ .

A fracture union was clinically defined as no pain or tenderness during daily activity with loading, and radiographically defined when trabeculae had bridged the main fracture fragments (9) Non-union was defined

as a fracture that was still not united after one year's treatment.

## Results

The average follow-up period was 24 months (range, 18 months). Out of 28 cases, 16 fractures were treated with plating and 12 with pinning. All fractures healed within three months and the union rate was 90%. There were no perioperative complications. There were no cases of failure of closed reduction and Kirschner wire fixation that had to be converted to plating.

Postoperatively, the mean radioulnar variance (the ulnar prominence of the distal radioulnar joint) in the plating group was 2.3 mm (range, minus 2 to +1 mm) and in the pinning group was +1.8 mm (range, minus 2 mm to +2 mm). At the last follow-up, the mean radioulnar variance in the plating group was 1.0 mm and in the pinning group was +1.6 mm. The comparison between both techniques was not significant ( $p = 0.59$ ).

Postoperatively, the mean volar inclination (the volar tilting of the distal radial joint) in the plating group was plus 5.3 degrees (range, 0 to +10 degrees) and in the pinning group was plus 7 degrees (range, +1 to +10 degrees). At the latest follow-up, the mean volar inclination in the plating group was plus 6.1 degrees (range -1 to +10 degrees) and in the pinning group was plus 7.3 degrees (range, -2 to +10 degrees). The comparison between both techniques was significant ( $p$  value-.60). Postoperatively, the mean ulnar angulation (the inclination of the distal radial joint) in the plating group was 17.6 degrees (range, 15 to 24 degrees) and in the pinning group was 19.6 degrees (range, 15 to 22 degrees), ( $p$  value.50). At the latest follow-up, the mean ulnar angulation in the plating group was 19.0 degrees (range, 12 to 25 degrees) and in the pinning group was 17.5 degrees (range, 14 to 22 degrees). The comparison between both techniques was not significant (5,6). There was no superficial or deep wound infection, non-union or malunion (> 2 mm step-off of the joint surface, >5 mm of radioulnar variance >10 degrees of dorsal inclination, < 10 degrees of ulnar angulation).(11)

## Discussion and Conclusion

For achieving a good fracture healing there should be minimal gap at the fracture site, adequate stability and sufficient nutrition supply (12). Because, the distal radius is formed of massive cancellous bone which has plenty of blood supply and bone formation potential the fracture healing process and the chances of union are high but these fractures can go into malunion. Volar Barton's fractures often produce volar subluxation of the carpus (5,6). This malunion can be avoided by providing a reasonable anatomic reduction and stabilization.(5) A malunion can be a cause of serious disability, and damage the articular cartilage, which has no power of regeneration.(13,14)

In this study, plating or external fixation combined with Kirschner wires and pinning achieved sufficient stability during the fracture healing process. In other words, both techniques provide sufficient stability for the healing process to occur as per the literature, the stability of an external fixation is doubted hence it was not used in young active workers. (10). In our series we used threaded 2.5 mm pins for the distractor fixation and threaded Kirschner wires explain the cause of improved stability with external fixation method and better hold in the osteoporotic fractures. Clinically, both techniques have advantages and disadvantages. Plating treatment can reduce fragments more precisely and the fragments can be stabilized more securely (5, 6). However, it requires opening the fracture site. If local swelling is serious, closure of the incision site may be very difficult and is associated with wound gaping problems (2 cases), although the incision is usually not large and the infection rate is very low (1 case), although the fracture healing process is not hindered due to the abundance of cancellous bone in this area. The success rate is therefore high. (88%)

Kirschner wires used in treatment, avoid opening the fracture site and so there is no need to worry about incision site problems. However, fragment reduction with stabilization may be not so satisfactory, with loosening of Kirschner wires and external fixator pins due to pin tract infection. Moreover, tendon penetration by the external fixation may interfere with thumb and index finger movement. (16, 17) We observed this in one of our cases. Fortunately, the external fixation can usually be removed after six weeks, and wrist and finger range of motion exercises can then be implemented. Therefore, the functional outcome of the wrist joint is largely satisfactory.

In the literature, the satisfaction rating with volar plating is 77 to 94 %.(3-6). However, in the present series, all 12 cases of fracture achieved satisfactory results (80%). Long-term results mainly depend upon the degree of arthritis of the wrist as volar Barton's fractures involve the articular surface and the injured articular cartilage normally cannot regenerate. (13, 14)

Therefore, with a longer follow-up, the success rate will reduce, and this is a drawback of this short term study.(3-6) The cases where the results were compromised were due to pin loosening, loss of reduction in follow-up (1 case) and restriction of thumb and index finger movement. Despite the fact that external fixation and Kirschner wire can be removed within six weeks, some patients still had finger stiffness. Hence, JESS distractor pins must be placed in safe zone laterally with a proper use of a C Arm. (18-21)

These techniques have advantages and disadvantages. To avoid poor function of the joints, wrist and finger range-of-motion exercises should be implemented as early as possible. This is specially

important for Barton fractures that have intra articular involvement.

In conclusion, volar Barton's fractures are not uncommon. Current surgical techniques can provide very good results and functional outcome along with cosmesis. Both techniques have advantages and disadvantages but the results from the plating treatment seem to be better than Wire and external fixation. (22)

**Conflict of Interest: None**

**Source of Support: Nil**

#### References:

1. Ellis J. Smith's and Barton's fractures. A method of treatment. *J Bone Joint Surg Br* 1965; 47:724-7.
2. Woodyard JE. A review of Smith's fractures. *J Bone Joint Surg Br* 1969;51:324-9.
3. Pattee GA, Thompson GH. Anterior and posterior marginal fracture-dislocations of the distal radius. An analysis of the results of treatment. *Clin Orthop Relat Res Chang Gung* 1988;231:183-95.
4. Jupiter JB, Lipton H. The operative treatment of intraarticular fractures of the distal radius. *Clin Orthop Relat Res* 1993;292:48-61.
5. Aggarwal AK, Nagi ON. Open reduction and internal fixation of volar Barton's fractures: a prospective study. *J Orthop Surg (Hong Kong)* 2004;12:230-4.
6. Jupiter JB, Fernandez DL, Toh CL, Fellman T, Ring D. Operative treatment of volar intra-articular fractures of the distal end of the radius. *J Bone Joint Surg Am* 1996;78:1817-28.
7. Gustilo RB, Anderson JT. Prevention of infection in the treatment of one thousand and twenty-five open fractures of long bones: retrospective and prospective analyses. *J Bone Joint Surg Am* 1976;58:453-8.
8. Sisk TD. Fractures of shoulder girdle and upper extremity. In: Crenshaw AH, ed. *Campbell's Operative Orthopedics*. 7th ed. St. Louis: CV Mosby Co., 1987:1783-831.
9. Wu CC, Shih CH. Treatment for nonunion of the shaft of the humerus: comparison of plates and Seidel interlocking nails. *Can J Surg* 1992;35:661-5.
10. Seinsheimer F. Subtrochanteric fractures of the femur. *J Bone Joint Surg Am* 1978;60:300-6.
11. French RJ. Fractures and dislocations of the wrist. In: Brinker MR, ed. *Review of Orthopedic Trauma*. 3rd ed. Philadelphia: WB Saunders Co., 2001:277-302.
12. Karlstrom G, Olerud S. Fractures of the tibial shaft: a critical evaluation of treatment alternatives. *Clin Orthop*. 1974;105:82-111.
13. Mow VC, Proctor CS, Kelly MA. Biomechanics of articular cartilage. In: Nordin M, Frankel VH, eds. *Basic Biomechanics of the Musculoskeletal System*. 2nd ed. Philadelphia: Lea & Febiger, 1989:31-58.
14. West RV, Fu FH. Soft-tissue physiology and repair. In: Vaccaro AR, ed. *Orthopaedic Knowledge Update 8*. Rosemont, IL: American Academy of Orthopedic Surgeons, 2005:15-27.
15. Dicipinigaitis P, Wolinsky P, Hiebert R, Egol K, Koval K, Tejwani N. Can external fixation maintain reduction after distal radial fractures? *J Trauma* 2004;57:845-50.
16. Green SA. Complications of external skeletal fixation. *Clin Orthop Relat Res* 1983;180:109-16.
17. Behrens F. General theory and principles of external fixation. *Clin Orthop Relat Res* 1989;241:15-23.
18. Harley BJ, Scharfenberger A, Beaupre LA, Jomha N, Weber DW. Augmented external fixation versus percutaneous pinning and casting for unstable fractures of the distal radius--a prospective randomized trial. *J Hand Surg [Am]* 2004;29:815-24.
19. Hegeman JH, Oskam J, Vierhout PA, Ten Duis HJ. External fixation for unstable intra-articular distal radial fractures in women older than 55 years. Acceptable functional end results in the majority of the patients despite significant secondary displacement. *Injury* 2005;36:339-44.
20. Chen AC, Chan YS, Yuan LJ, Ye WL, Lee MS, Chao EK. Arthroscopically assisted osteosynthesis of complex intraarticular fractures of the distal radius. *J Trauma* 2002;53:354-9.
21. Ruch DS, Vallee J, Poehling GG, Smith BP, Kuzma GR. Arthroscopic reduction versus fluoroscopic reduction in the management of intra-articular distal radius fractures. *Arthroscopy* 2004;20:225-30.
22. Wright TW, Horodyski M, Smith DW. Functional outcome of unstable distal radius fractures: ORIF with a volar fixed-angle tine plate versus external fixation. *J Hand Surg [Am]* 2005;30:289-99.