



Original Research Article

Easy solutions to difficult problems in lower limbs

Sasanka Sekhar Chatterjee¹, Neelam Yadav^{2,*}¹Dept. of Plastic Surgery, Institute of Post Graduate Medical Education and Research, Kolkata, West Bengal, India²NRS Medical College, Kolkata, West Bengal, India

ARTICLE INFO

Article history:

Received 02-05-2023

Accepted 20-05-2023

Available online 04-09-2023

Keywords:

Flap failure

Lower limb recurrent defect

Tendoachilles defect

Wound resurfacing

Knee defect

ABSTRACT

Objectives: In clinical practice, all of us have at sometime or other faced with problems where the ideal solutions may not be possible. The reason is mostly economic but even desire of the patient not to undergo complex procedures has to be taken into account. In this article authors describe management of these surgical challenges when compromised confidence of patients and relatives from previous surgeries left him with minimum choices available for secondary surgeries. Here are six such cases where simplest option were chosen achieving best long term outcome both in form and function and with least donor morbidity.

Materials and Methods: This study describes the retrospective review of a single surgeon experience from his archives of six cases where salvage procedure were done, which fulfilled reconstructive goals as well as decreased apprehension related to failure of surgery.

Results: All 6 patients demonstrated complete wound healing by final follow up, without need for further reoperations or recurrence.

Conclusion: Surgeon by his depth of knowledge and huge experience was able to manage all these surgical challenges with ease providing optimal form and function following principles of plastic surgery with ingenuity. These procedure not only reduced the surgical morbidity but also hospital stay and overall cost of treatment.

This is an Open Access (OA) journal, and articles are distributed under the terms of the [Creative Commons Attribution-NonCommercial-ShareAlike 4.0 License](https://creativecommons.org/licenses/by-nc-sa/4.0/), which allows others to remix, tweak, and build upon the work non-commercially, as long as appropriate credit is given and the new creations are licensed under the identical terms.

For reprints contact: reprint@ipinnovative.com

1. Introduction

In clinical practice, all of us have at sometime or other faced with problems where the ideal solutions may not be possible. The reason is mostly economic but even desire of the patient not to undergo complex procedures has to be taken into account. The surgeon needs to find solutions to the particular problem conforming to the economic condition and desire of the patient considering modified reconstructive ladder/elevator.¹

In this article authors describe management of these surgical challenges when compromised confidence of patients and relatives from previous surgeries left him with

minimum choices available for secondary surgeries. Here are six such cases where simplest option were chosen achieving best long term outcome both in form and function and with the least donor morbidity based on their surgical experience. In all these cases reconstruction principles are based on the reconstructive triangle where ideal reconstruction technique depends on providing optimal form and function with maximum safety.²

2. Material and methods

This study describes the retrospective review of a single surgeon experience from his archives of six cases where salvage procedure were done, which fulfilled reconstructive goals as well as decreased apprehension related to failure of

* Corresponding author.

E-mail address: neelam.rims@gmail.com (N. Yadav).

surgery.

3. Result

Case 1: A 70 yrs. old lady, hypertensive, diabetic and suffering from COPD has been referred with an exposed Tendo Achilles following its repair after having exhausted her financial resources. Ideally the wound should be debrided and a perforator based flap or a microvascular free flap cover should be executed. These procedures can be physiologically demanding in high risk patients with multiple co morbidities, with exposure to prolonged general anaesthesia and increased surgical morbidities.

Procedure undertaken: After Debridement, the technique of soft tissue reconstruction involved, raising of bucket handle flaps on one side, a proximally based transposition flap on the other, skin grafting on donor site defects. (Figure 1)

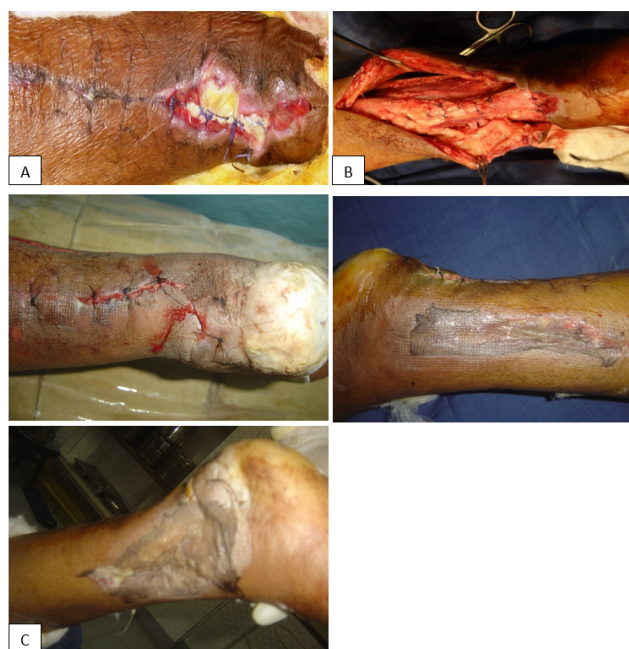

Fig. 1: A): Seventy yrs. old lady presents with multiple comorbidities and exposed Tendo Achilles with slough; **B):** Wound debridement, fresh repair of remnants of ends of Tendo Achilles, raising of bipedicle flap on lateral side and a perforator (pointed by Adson's forceps) based peninsular flap on medial side; **C):** Flap sutured in place skin graft applied in donor site

Case 2: A 68 yrs. Old factory worker sustained an injury over his left Tendo Achilles for which he had undergone a distally based fasciocutaneous flap cover elsewhere. He now presented with exposure of the tendon proximal to the flap which needed a cover.

Procedure undertaken: Debridement. Splitting of previous flap keeping a layer subcutaneous tissue over the previously injured site and transposing the skin containing

part of the flap proximally. (Figure 2)

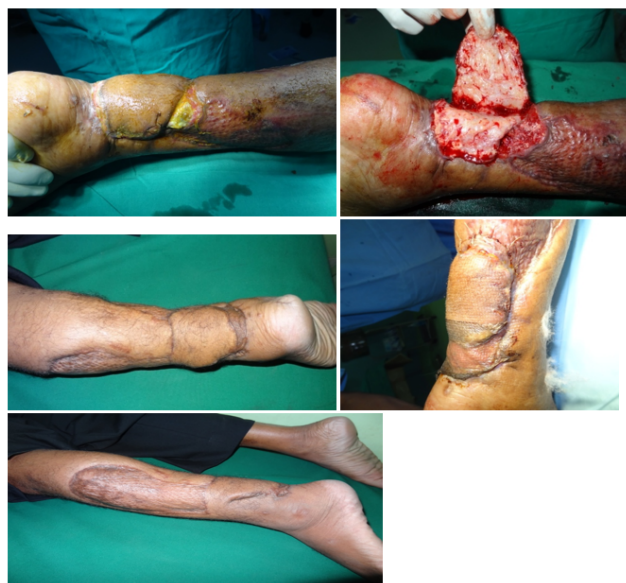

Fig. 2: Showing an existing ulcer over previous repair of Tendo Achilles reconstructed by a distally based fasciocutaneous flap. The flap was split, skin and a partial layer of subcutaneous tissue raised and used to cover the defect. The donor site is skin grafted followed by complete healing

Case 3: A girl of 15 yrs. sustained an injury in the anterolateral compartment of leg about 6 months back. Now she presented with a healed skin wound, ankle and toe drop.

Procedure undertaken: Wound explored with a lazy-s extension after excision of the previous scar, tendons were repaired and now closure was difficult as the distal part of leg contains less elastic skin. Tissue edema and configuration of the repair prevented an ideal closure resulting in exposure of the site of repair. To circumvent the problem, a small local fascial flap was raised and transposed to cover the repair site. This helped to close the wound loosely keeping a small area even partially exposed. The wound healed primarily with full functional recovery. (Figure 3)

Case 4: A 53 yrs. old male sustained fracture of patella for which he was operated. There was longitudinal wound gaping and the patient was referred by Orthopaedician.

Procedure undertaken: Bilateral bipedicle flaps were raised and sutured in two layers to cover the patella and skin grafting done on the donor defects with uneventful recovery. (Figure 4)

Case 5: A young man of 35 yrs. sustain traumatic amputation at knee level. Proper wound debridement led to growth of healthy granulation tissue except over a 1.5 to 2cm of exposed bone. Orthopaedician didn't want to shorten any part of the bone.

Procedure undertaken: To ensure cover, adjacent granulation tissue was raised as a flap and transposed over

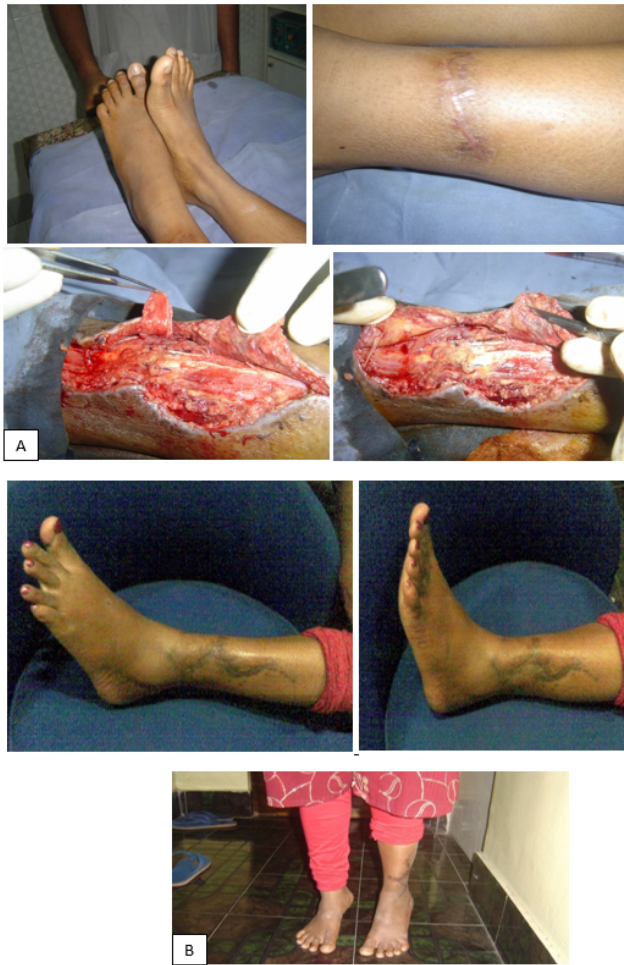

Fig. 3: A): A 15 yrs. old female presents with old injury to lower anterolateral compartment of leg with foot and toe drop. Exploration and repair of tendons were done but closure of wound was difficult with possibility of exposure of repaired site. A small local fasciocutaneous flap was raised to cover the repaired tendons to help loose closure of skin; B): Follow up of healed wound with restoration of ankle and toe dorsiflexion, patient being able to stand on toes

the exposed bone as a cover. It was fixed with 3'0' polyglactin suture. The wound was grafted with complete healing and without any shortening the amputation stump. (Figure 5)

Case 6: A 68 yrs. old male patient, smoker, alcoholic with Diabetes, hypertension, hyperlipidemia with h/o irregular treatment presented with a chronic ulcer following trauma over right Tendo Achilles. There was necrosed tissue with eschar and slough at places.

Procedure undertaken: Wound was debrided and cover ensured with an adjacent distally based fasciocutaneous flap based on peroneal artery perforator. The flap had a partial success. Patient was unwilling for any surgical procedure whatsoever while adamant on getting cured.

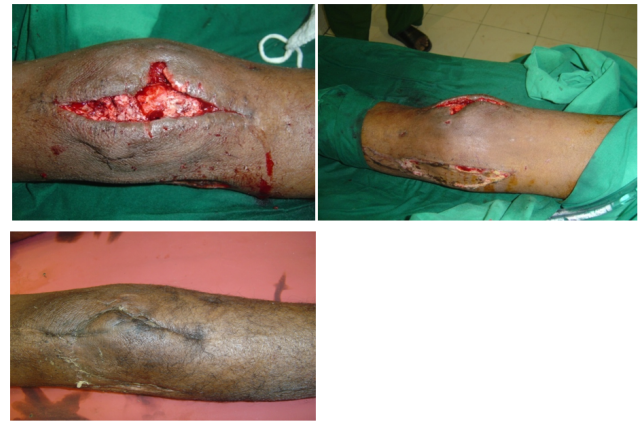

Fig. 4: Showing wound dehiscence following reduction and fixation of fracture patella. Bipedicled flaps raised from both sides to cover the wound and grafts on donor site ensured complete healing

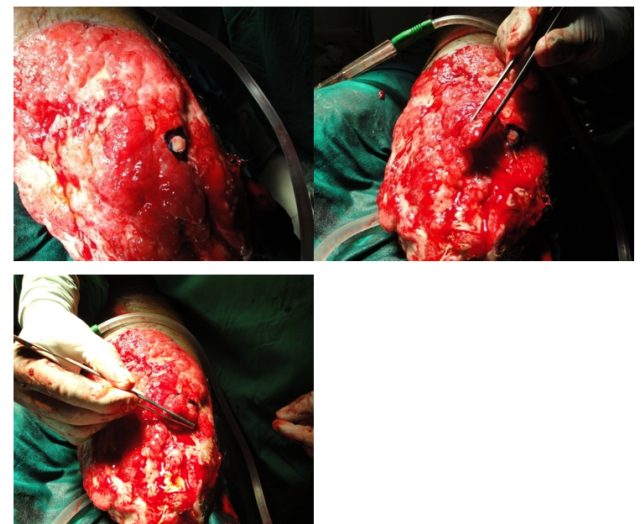


Fig. 5: Showing exposed portion of femoral condyle (marked in blue) in a large wound resulting from road traffic accident with healthy granulation tissue. Orthopaedicians refused to shorten any part of bone. So a flap of granulation tissue is used to cover the bone followed by skin graft cover

Twice a week he was subjected to application of nylon sutures and gradual tightening, a form of tissue expansion. It took about 3 months to heal (Figure 6) The surviving remnant of flap were suture tractioned to the surrounding skin. Procedure was done in local anaesthesia with reduced operative time and without of additional donor defect.

4. Discussion

In this study all 6 cases were related to lower limb, out of which 4 were of lower third of leg. Lower limb defects particularly in the distal part pose a problem in providing

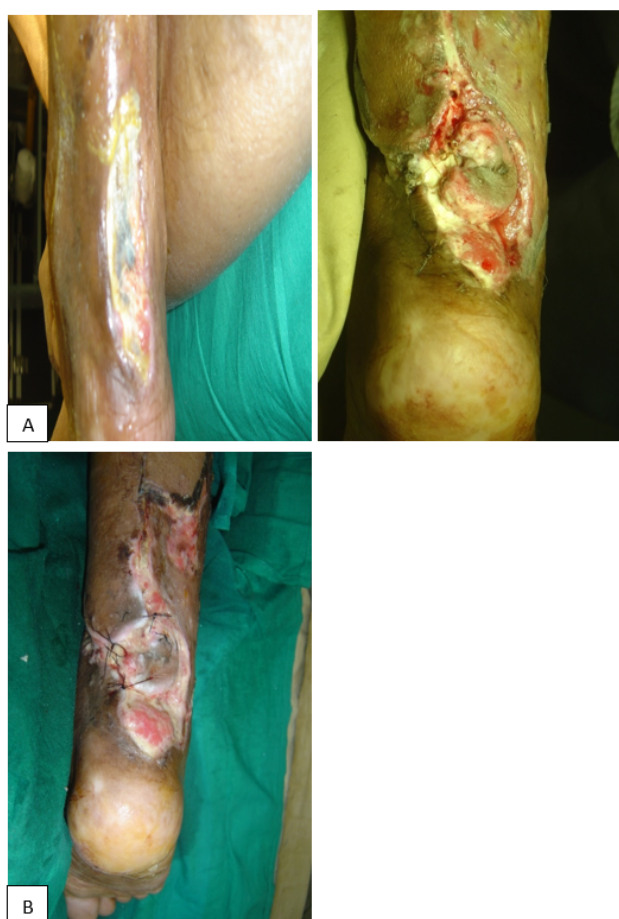

Fig. 6: A): 68 yrs. old male patient with multiple comorbidities and irregular treatment presents with eschar and over Tendo Achilles following an old injury. Debridement and a distally based fasciocutaneous flap met with partial success with areas of exposure still present

surgical cover.^{3,4} Microvascular free flaps, fasciocutaneous flaps, perforator based flaps, with additional skin grafts are the usual procedures.^{5–7} Many elderly patients are further handicapped by presence of comorbidities like Diabetes mellitus, Hypertension, Hyperlipidaemia, Hyperuricemia and local vascular problem. These simple tricky surgeries help a great deal when operating in smaller setups with limited resources or when disappointed patient and family do not consent for performing another complex operation. Tissue edema and configuration of the repair prevented an ideal closure resulting in exposure of the site of repair, in case 3. To circumvent the problem, a small local fascial flap was raised and transposed to cover the repair site. This helped to close the wound loosely keeping a small area even partially exposed. The wound healed primarily with full functional recovery. (Figure 3)

Although a variety of flaps including muscle flaps and skin flaps have been described for knee defect which have their own advantages and disadvantages.⁸ Bipedicle flap

resurfacing of patellar defect aids in quicker healing and quicker rehabilitation of the patient. As we have discussed about case no.5 granulation tissue flap provided faster and reliable closure of bone defect without causing any addition need of flap.⁹ After partial loss of flap in case 6, the surgeon has no other option, he applied gradual suture traction. Above mentioned method was found more expedient as the patient would not accept any aggressive procedures. The policy pursued involved OPD procedure with a short operation time, economically acceptable, easy postoperative care and without donor site morbidity.^{10,11}

All 6 patients demonstrated complete wound healing by final follow up, without need for further reoperations or recurrence. These procedures were indeed lifeboat in unfavourable situations for the surgeon and economical for the patient and family.

5. Conclusion

After a failed case or recurrent defect the patient and family are disappointed, and disturbed over the need for additional surgery. Decision making mandates even greater thoughtfulness. In all above mentioned cases, situations demanded simple, reliable but economic solutions. Surgeon by his depth of knowledge and huge experience was able to manage all these surgical challenges with ease providing optimal form and function following principles of plastic surgery with ingenuity. These procedure not only reduced the surgical morbidity but also hospital stay and overall cost of treatment.

6. Source of Funding

None.

7. Conflict of Interest

None.

References

1. Gottlieb LJ, Krieger LM. From the reconstructive ladder to the reconstructive elevator. *Plast Reconstr Surg*. 1994;93(7):1503–4.
2. Neligan PC. Plastic Surgery. 4th ed. London: Elsevier; 2018.
3. Hallock GG. A paradigm shift in flap selection protocols for zones of the lower extremity using perforator flaps. *J Reconstr Microsurg*. 2013;29(4):233–40.
4. Nelson JA, Fischer JP, Brazio PS, Kovach SJ, Rosson G, Rad AN. A review of propeller flaps for distal lower extremity soft tissue reconstruction: Is flap loss too high? *Microsurgery*. 2013;33(7):578–86.
5. Parrett BM, Talbot SG, Pribaz JJ, Lee BT. A review of local and regional flaps for distal leg reconstruction. *J Reconstr Microsurg*. 2009;25(7):445–55.
6. Almugaren FM, Pak CJ, Suh HP, Hong JP. Best Local Flaps for Lower Extremity Reconstruction. *Plast Reconstr Surg Glob Open*. 2020;8(4):e2774.
7. Soltanian H, Garcia RM, Hollenbeck ST. Current concepts in lower extremity reconstruction. *Plast Reconstr Surg*. 2015;136(6):815–29.

8. Winter H, Haas N. Granulation tissue flap technique in extensive wounds for covering exposed bone after tumor excision. *Dermatol Surg*. 2000;26(9):829–34.
9. Rb R, Ramkumar S, Venkatramani H. Soft Tissue Coverage for Defects around the Knee Joint. *Indian J Plast Surg*. 2019;52(1):125–33.
10. Chi D, Chen AD, Dorante MI, Lee BT, Sacks JM. Plastic surgery in the time of COVID-19. *J Reconstr Microsurg*. 2021;37(02):124–31.
11. Savas SA. Skin Traction Technique for Closure of Large and Complex Skin Defects in Special Cases . *Mid Blac Sea J Health Sci*. 2021;7(2):276–81.

Author biography

Sasanka Sekhar Chatterjee, Ex. Professor

Neelam Yadav, Ex. Post Doctoral Trainee

Cite this article: Chatterjee SS, Yadav N. Easy solutions to difficult problems in lower limbs. *Indian J Orthop Surg* 2023;9(3):168-172.