



Case Report

Isolated post-traumatic anterior radial head dislocation in adult: A very rare injury

Anu Aggrawal¹, Yogdeepsinh Jadeja², Pushkar Chawla¹, Ritabh Kumar^{1*}

¹Dept. of Orthopaedics, Indian Spinal Injuries Centre, New Delhi, India

²Dept. of Orthopaedics, Navjivan General Hospital, Amreli, Gujarat, India



ARTICLE INFO

Article history:

Received 28-05-2023

Accepted 09-11-2023

Available online 07-12-2023

Keywords:

Isolated radial head dislocation

Monteggia variant

ABSTRACT

Isolated anterior radial head dislocations are rare injuries. Few cases have been reported in the literature. Most patients are diagnosed late with restricted forearm rotations. In this report, we provide the details of an isolated radial head anterior dislocation with Mason type 1 radial head fracture in an adult.

This is an Open Access (OA) journal, and articles are distributed under the terms of the [Creative Commons Attribution-NonCommercial-ShareAlike 4.0 License](https://creativecommons.org/licenses/by-nc-sa/4.0/), which allows others to remix, tweak, and build upon the work non-commercially, as long as appropriate credit is given and the new creations are licensed under the identical terms.

For reprints contact: reprint@ipinnovative.com

1. Introduction

Isolated radial head dislocation is a rare elbow injury in adults. Radial head dislocation is usually associated with proximal ulna fracture and known as Monteggia fracture-dislocation.¹ Higher grades of radial head fractures are associated with elbow dislocation and disruption patterns. Most of the cases reported of isolated radial head dislocation are posterior.¹ Only a few cases of isolated anterior radial head dislocation have been reported in English literature so far. In this report, we provide the details of an isolated post-traumatic anterior radial head dislocation in an adult.

2. Case Report

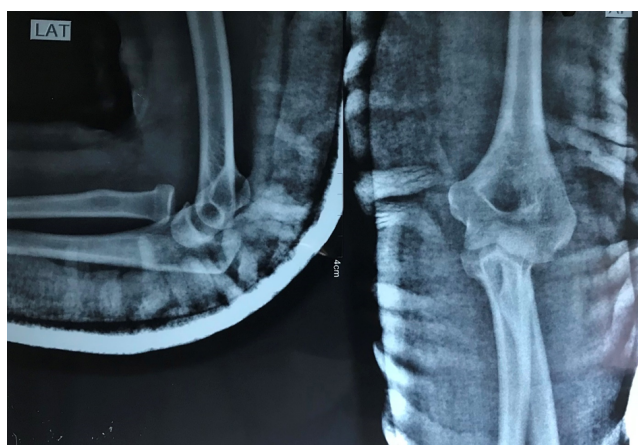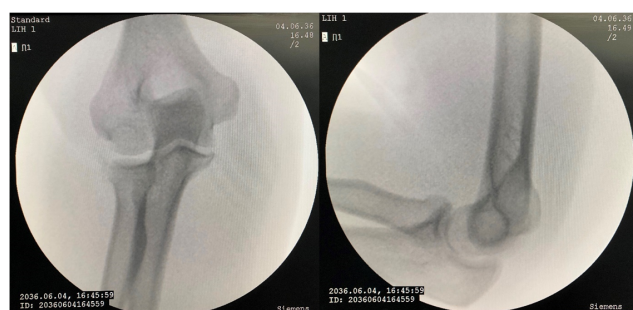
A 39-year-old lady presented in the emergency department following a history of fall 6 days back wherein she injured her left elbow. She complained of pain in the elbow region along with swelling around the elbow. She underwent manipulation under general anesthesia followed by an above elbow slab application elsewhere on the day of the injury. She complained of persistent pain in the elbow. The distal neurovascular was intact. Radial head fracture was the

clinical suspicion. Radiographs were taken in two planes. A careful review of the radiographs showed a misalignment of the radiocapitellar line. The radial head was dislocated anteriorly with fracture of the radial head (Mason type 1) (Figure 1). On examination after slab removal gross swelling in the elbow was noted. There was no obvious limb deformity. Active elbow flexion was possible from 30-90 degrees. Rotations were painful and limited. She was given pain medication and the above elbow splint re-applied. She was admitted for closed/open reduction of the dislocation under general anaesthesia.

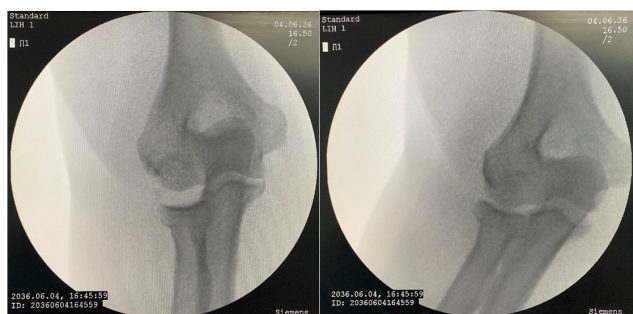
After preparation, she was taken to the operation theatre and general anaesthesia administered. Reduction was attempted with gentle traction in supination and a click sound was noted by the surgeon (Figure 2). A stable Mason type 1 radial head fracture was noted. The stability of the elbow was assessed in varus and valgus stress and found to be stable (Figure 3). The elbow was also stable in full extension and flexion. Rotations were complete and hence surgery was abandoned. A comparison with contralateral side was also done. C-arm images were taken in multiple views to confirm the reduction and stability of the dislocation and radial head fracture.

* Corresponding author.

E-mail address: anuaggrawal1990@gmail.com (R. Kumar).

**Figure 1:****Figure 2:** C-arm images of the reduced radial head in AP and Lateral view

The distal vascular status was preserved post-reduction. An above elbow slab was applied in 90 degrees flexion and full supination.

**Figure 3:** C-arm images of the elbow in valgus and varus stress

The slab was removed after 10 days and intermittent active elbow movements encouraged. At the end of six months, her movements were pain-free with terminal restriction of flexion and extension (Figure 4). The rotations were complete.

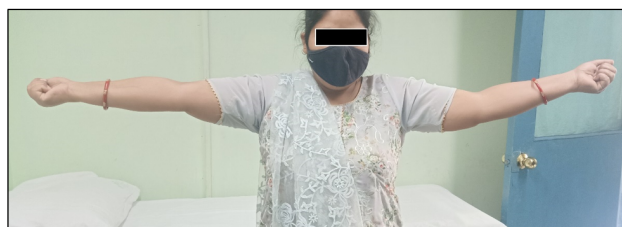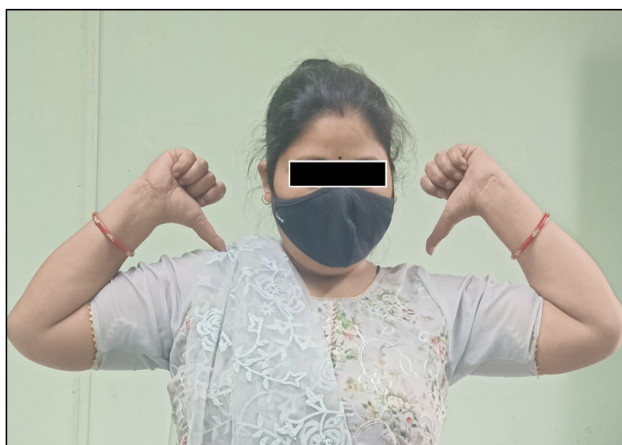**Figure 4:** Clinical picture in complete extension**Figure 5:** Clinical picture in complete flexion**Figure 6:** Clinical picture in complete pronation



Figure 7: Clinical picture in complete supination

3. Discussion

Isolated radial head subluxation is common in children and referred to as a pulled elbow or nursemaid's elbow. In adults, isolated radial head dislocation without any associated fracture or elbow dislocation is a very rare injury.^{1,2} A Monteggia variant is the next most common association with a radial head dislocation. If the injury is missed, it may lead to restricted rotations and significant functional disability.³

The mechanism of injury is still debatable. The postulated mechanism is hyper pronation of the forearm with the elbow in extension.^{1,3} Hyperlaxity may be a factor as in the present case the lady had flexible joints.

The diagnosis of an isolated radial head dislocation is very likely to be missed on the radiograph. Careful scrutiny of the x-ray with emphasis on the radiocapitellar line helped diagnose this condition. The presence of significant swelling must act as a warning sign of something amiss and a higher imaging like CT scan may be obtained when in doubt. Complete dislocation is not possible without disruption of the annular ligament (major stabilizing structure of proximal radio-ulnar joint).

The management of an acute radial head dislocation is usually non-operative with closed reduction.⁴ Assessment of stability is essential after a closed reduction. If there is doubt of instability one should proceed to the surgical treatment to make the elbow stable.¹

If the diagnosis is missed in the acute stage, closed reduction methods are not possible. Chronic missed cases require surgical methods - radial head resection and annular ligamentoplasty with or without olecranon osteotomy.⁴⁻⁸ In 2021, Bordet A et al. reported a case of a 31 years old young male with a missed diagnosis and performed surgical reduction in the form of ulnar oblique flat osteotomy with

annular ligamentoplasty.⁴

In 2019, Kansay R. et al. reported a case of an 18 years old young male with isolated anterior radial head dislocation with atypical presentation and failed closed reduction. They performed open reduction with annular ligamentoplasty and K-wire fixation of the proximal radio-ulnar joint.⁹

In the present case, closed reduction was achieved successfully with elbow traction in extension and full supination. Manual pressure over the radial head lead to the feel of a click. Post-reduction the radial head was found to be stable and the elbow flexion-extension arc was complete. The elbow was stable. The functional outcome after six months was very satisfactory.

4. Conclusion

Isolated traumatic anterior radial head dislocation in the adult is extremely rare. Clinical examination of the injured elbow and careful evaluation of the radiograph will help suspect and diagnose this injury pattern. Closed reduction is achievable early in the acute phase. The stability of the radial head and the elbow must always be assessed after reduction. The prognosis for long-term function is good if managed promptly.

5. Source of Funding

None.

6. Conflict of Interest

None.

References

1. Fonte H, Rodrigues C, Vale J, Ramos J, Castro JC. Isolated traumatic posterior dislocation of the radial head in an adult, a rare injury: a new case report. *Trauma Case Rep.* 2020;29:100345. doi:10.1016/j.tcr.2020.100345.
2. Hayami N, Omokawa S, Iida A, Kraissarin J, Moritomo H, Mahakkanukrauh P, et al. Biomechanical study of isolated radial head dislocation. *BMC Musculoskelet Disord.* 2017;18(1):470.
3. Rethnam U, Yesupalan RS, Bastawrous SS. Isolated radial head dislocation, a rare and easily missed injury in the presence of major distracting injuries: a case report. *J Med Case Rep.* 2007;1(1):38. doi:10.1186/1752-1947-1-38.
4. Bordet A, Mentec OL, Arcens M, Trouilloud P, Baulot E, Martz P. Chronic isolated radial head dislocation in adults: Technical note and literature review. *Orthop Traumatol Surg Res.* 2021;107(2):102829.
5. Bhaskar A. Missed Monteggia fracture in children: Is annular ligament reconstruction always required? *Indian J Orthop.* 2009;43(4):389–95.
6. Gyr BM, Stevens PM, Smith JT. Chronic Monteggia fractures in children: outcome after treatment with the Bell-Tawse procedure. *J Pediatr Orthop B.* 2004;13(6):402–6.
7. Datta T, Chatterjee ND, Pal AK, Das SK. Evaluation of outcome of corrective ulnar osteotomy with bone grafting and annular ligament reconstruction in neglected Monteggia fracture dislocation in children. *J Clin Diagn Res.* 2014;8(6):1–4.
8. Tan L, Li YH, Sun DH, Zhu D, Ning SY. Modified technique for correction of isolated radial head dislocation without apparent ulnar bowing: a retrospective case study. *Int J Clin Exp Med.* 2015;8(10):18197–202.


9. Kansay R, Gupta S, Soni A, Malhotra A, Garg SK. Isolated anterior dislocation of the radial head with atypical presentation in an adult: A case report. *Rev Bras Ortop (Sao Paulo)*. 2019;54(6):746–50.

Pushkar Chawla, Senior Consultant  <https://orcid.org/0000-0002-7678-8354>

Ritabh Kumar, Senior Consultant  <https://orcid.org/0000-0002-7414-7588>

Author biography

Anu Aggrawal, Senior Resident  <https://orcid.org/0000-0003-2237-3767>

Yogdeepsinh Jadeja, Consultant Orthopedic Surgeon  <https://orcid.org/0000-0002-9206-3652>

Cite this article: Aggrawal A, Jadeja Y, Chawla P, Kumar R. Isolated post-traumatic anterior radial head dislocation in adult: A very rare injury. *Indian J Orthop Surg* 2023;9(4):266-269.