

Role of distraction compression osteogenesis by ilizarov ring fixator in complex non-union of long bones

Amit Kumar Sharma^{1*}, Jayant Sharma²

¹DNB Resident, ²Guide & Associate Professor, Unique Super Speciality Centre, Indore, Madhya Pradesh

***Corresponding Author:**

Email: aksraj0909@gmail.com

Abstract

Purpose: To review the outcome of 16 patients who underwent compression distraction osteogenesis for long bone nonunion by ilizarov ring fixator.

Methods: A total of 16 patients were reviewed (13 male, 3female) of average age 46 years (17-60). All patients underwent compression distraction osteogenesis for union & bone lengthening by ilizarov ring fixator. Patients were assessed by ASAMI criteria for functional and bone outcome.

Results: Patients were followed up for a mean period of 10 months. Functional outcome was assessed Excellent=7, Good=7, Fair=2 & Bone union outcome was Excellent=5, Good=10, Fair=1.

Pin tract infection was most common problem encountered other were wire breakage, pressure necrosis, knee contracture and refracture all were managed accordingly.

No major neurovascular complication was encountered.

Conclusion: We concluded that ilizarov ring fixator is a viable option for Non-union of long bone.

Keyword: Non-union, Ilizarov, Ring fixator, Distraction, Compression, Osteogenesis.

Introduction

Gavril Abramovich Ilizarov introduced this technique in village of kurgon in Russia in 1951 for treatment of fractures primarily. He discoursed techniques like physal distraction, corticotomy lengthening, bone transport. Common basis of all these methods is known as "Theory of Tension Stress".^(1,2) Through controlled and mechanically applied tension stress he was able to show that bone & soft tissue can be made to regenerate in reliable and reproducible manner. This method can be used in (1) Limb Lengthening (2) Treatment of Non-Unions (3) Correction of Bony Deformities (4) Arthrodesis.⁽³⁻⁵⁾ Can be used in condition where no other surgical implant is useful like severe infection, skin loss or for lengthening of deformed short bones.⁽⁶⁻⁸⁾

The multiplaner circular construction and tensioned wire provide for more structural support than traditional uniplaner external non union fixator systems. This allows early weight bearing.^(9,10)

Non-Union of long bone is a challenging situation in Orthopedics. Bone grafting is used to fill defects cancellous bone for small defects,⁽¹¹⁾ vascularised fibula and allograft for large defect upto 4cm.⁽¹²⁾

In cases of complex non-unions that is infection, bone exposed, bone loss greater than 4cm, deformity, failure of internal fixation. The choice is either limb salvage by using Ilizarov fixator or amputation. Union in cases of long bones with large defect greater than 4cm needs bone transport and new bone formation by distraction osteogenesis using Ilizarov ring fixator.

Ilizarov has been successfully used in managing most of these problems. This study is to evaluate the

hypothesis that Ilizarov fixation can be efficaciously used in all cases of complex non-union.

Material and Methods

This is a prospective study carried out at our centre having a total of 16 patients with different mode of injuries as primary cause of fracture like road traffic accidents, fall from height, fire arm injury. Ilizarov with principle of compression distraction osteogenesis for union and bone lengthening was used in each patient. Every patient was described thoroughly about the complete process and proper consent was taken.

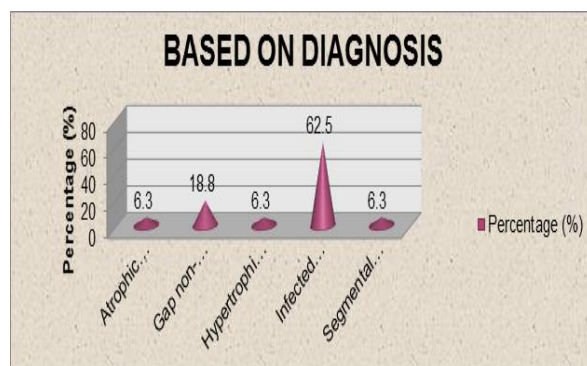
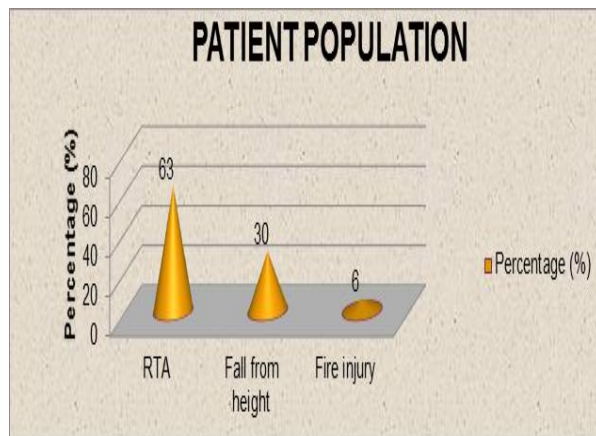
Pre-operative and post-operative X-ray were done in each cases to check correct positioning of wire and corticotomy. Metaphyseal corticotomy was used in every case in one case bifocal corticotomy was done. A proper meticulous debridement of dead sclerotic bone till fresh punctate bleeding was visible, fibrous tissue, dead necrotic bone and tissue was done when ever required. In a case where gap was less acute docking was done.

In cases of infected non-union intravenous antibiotics were used initially empirical then according to culture sensitivity for at least 3 weeks or till C-reactive protein and ESR showed improvement and then oral antibiotics. Proper dressing for wounds were done till healing on regular basis and proper pin tract care explained to patients to be done by themselves at home and a regular follow up at an interval of 3 weeks was done till maturity of bone and union. Average period of follow up was 43 weeks with a minimum of 24 weeks. Every patient was explained and educated thoroughly for how to carry on distraction at an optimum

rate of 1mm/ day in four quarters at home. Final results were assessed after removal of frame and proper physiotherapy by ASAMI (Association for the Study and Application of Methods of Ilizarov) for bone and functional results as used in several earlier studies.⁽¹³⁻¹⁵⁾

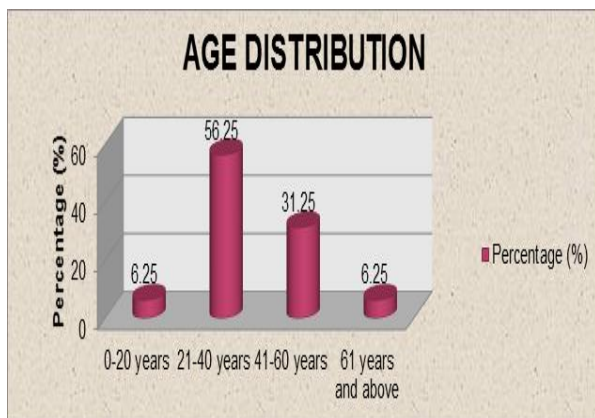
Table 1: Association for the Study and Application of Methods of Ilizarov scoring system

<p>Functional result: Excellent: Active, no limp, minimum stiffness [Loss<15° knee extension/ 15° dorsiflexion ankle], no reflex sympathetic dystrophy [RSD], insignificant pain. Good: Active with one or two of following: limp, stiffness, RSD, pain. Fair: Active with three or all of following: limp, stiffness, RSD, pain. Poor: Inactive [unemployment or inability to return to daily activities due to injury].</p>
<p>Bone result: Excellent: Union, no infection, deformity<7°, limb length discrepancy(LLD) <2.5 cm. Good: Union plus two of any of the following; absence of infection, deformity <7°, LLD<2.5 cm. Fair: Union plus any one of following; absence of infection, deformity <7°, LLD<2.5 cm. Poor: Union plus any one of following; absence of infection, deformity <7°, LLD<2.5 cm.</p>



Results

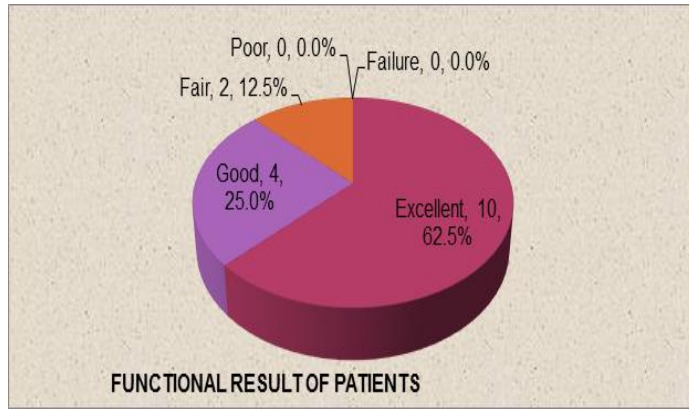
A total of 16 patients were there of which 13 male (81%) and 3 female (19%) of mean age 46 year most common bone involved was Tibia (68%), Femur (32%).



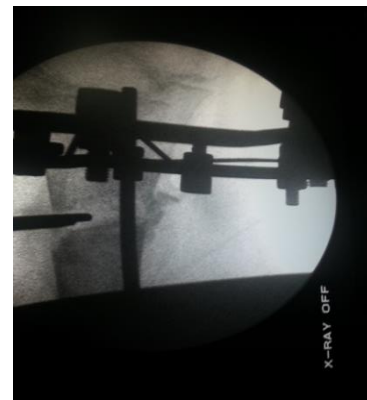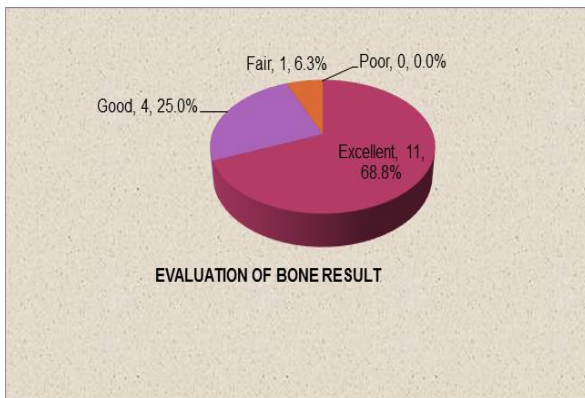
There were failed previous surgical attempts in every case except one. There was average delay of 38 weeks between initial trauma and presentation to us. Maximum cases of road traffic accident (63%), Fall from height (30%) and one case fire of injury (6%). Average period for which distraction was carried out was 55 days (8 weeks) and average new bone of 5.1cm was achieved.

According to ASAMI Criteria functional results we had were 10 excellent (62%), 4 good (25%), 2 fair (13%) and bone results were 11 excellent (68.5%) 4 good (25%), 1 fair (6.5%).

Grade	No. of Patients	Criteria	Percentage
Excellent	10	Active, no limp, minimum stiffness [Loss<15° knee extension / 15° dorsiflexion ankle], no reflex sympathetic dystrophy [RSD], insignificant pain.	62.5%
Good	4	Active with one or two of following: limp, stiffness, RSD, pain.	25.0%
Fair	2	Active with three or all of following: limp, stiffness, RSD, pain.	12.5%
Poor	0	Inactive [unemployment or inability to return to daily activities due to injury].	0%
Failure	0	Amputation.	0%

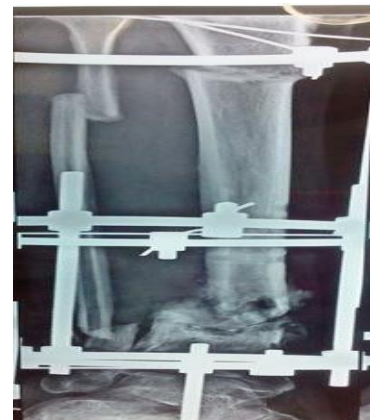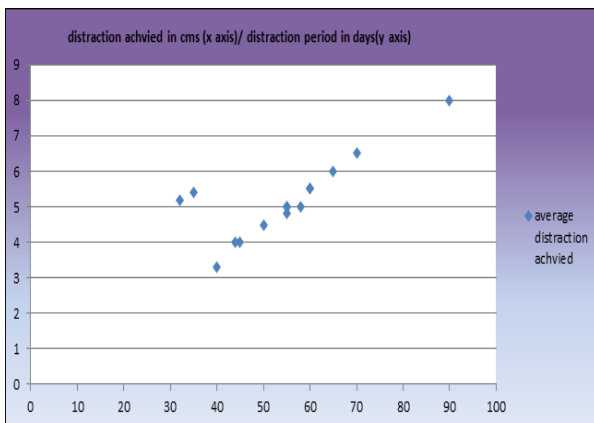


Bone result	No. of patients	Criteria	Percentage
Excellent	11	Union, no infection, deformity <7°, limb length discrepancy(LLD) <2.5 cm	68.8%
Good	4	Union plus two of any of the following; absence of infection, deformity <7°, LLD<2.5 cm.	25.0%
Fair	1	Union plus any one of following; absence of infection, deformity <70, LLD<2.5 cm.	6.3%
Poor	0	Union plus any one of following; absence of infection, deformity <70, LLD<2.5 cm.	0%

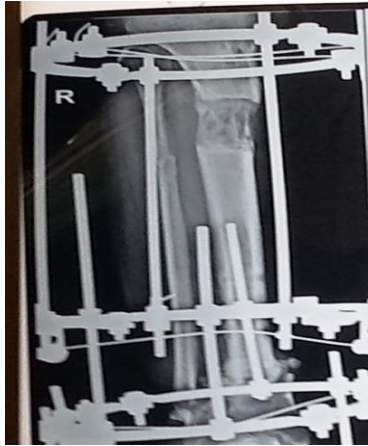

Intra-Op.

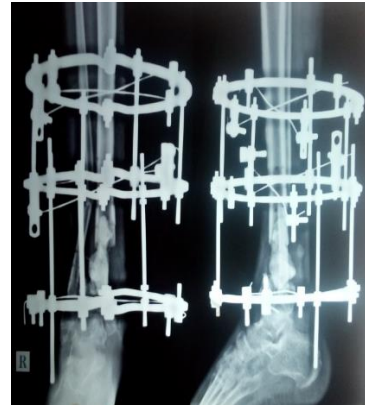Distraction achieved was plotted against distraction period on dot graph average distraction period was 54 days and average new bone formation was 5.1cm.



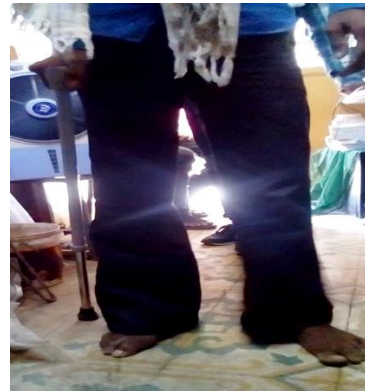1 Month



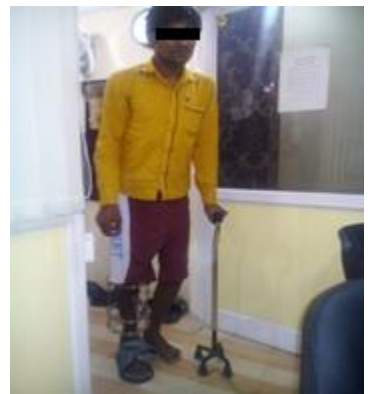3 Month



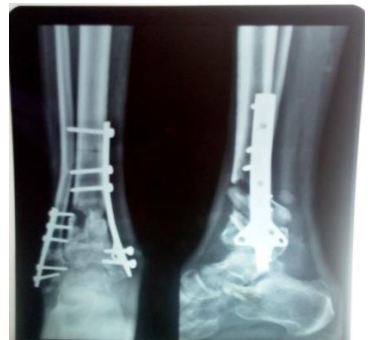2 Months



After Removal



Immediate Post Op Weight Bearing



Pre-Op

Discussion

In cases of complex non-union ilizarov offers a specialized modality of treatment which is effective in treating properly and most important thing is that patient can be mobilized in immediate post-operative period.

There are other modalities also available today's world like HEXAPOD, OCTAPOD which are computer guided patient specific spatial frames and required more skill and are expensive as per Indian patients are concerned who maximally belong to low socioeconomic groups so ilizarov fixator is quite better and good option till now.

Our study results were comparable to study carried out by **Paley et.al.**⁽¹⁶⁾ In which functional results were excellent (64%), good (28%) and fair (4%) and bone results excellent in (72%), good (20%) and fair (8%).

In another study by **Kumar (2013)** et.al.⁽¹⁷⁾ Functional results were excellent (40%), good (50%) and fair (10%) and bone results excellent in (79%), good (11%) and fair (10%).

In another study by **Khan (2015)** et.al.⁽¹⁸⁾ functional results were excellent (71%), good (17.7%) and fair (4.4%) and bone results excellent in (64%), good (20%) and fair (4.4%).

Pin tract infection (31.3%) was most common problem which we faced and it was adequately treated in each case. 2 cases had problem of angulations and

pressure necrosis. Contracture, Wire Breakage, Re-fracture occurred in one case each and were managed accordingly.

		No. of patients	Percentage
Problems	Poor regenerate	00	0%
	Angulation	02	12.5%
	Pin tract infection	05	31.3%
	Pressure necrosis	02	12.5%
Obstacles	Infection needing change of frame or wire.	00	0%
	Wire breakage	01	6.3%
True complication	Joint stiffness / contracture	01	6.3%
	Limb length discrepancy	00	0%
	Persistent infection	00	0%
	Neurological deficits	00	0%
	Refracture	01	6.3%

Conclusion

Ilizarov ring fixator can be used in cases of complex non-union efficaciously with high chances of getting excellent to good results for filling bone defect by bone transport and new inter-membranous bone formation and union at the fracture site.

References

1. Spiegelberg B, Parratt T Ilizarov principles of deformity correction, Jennings R, Ann R Coll Surg Eng 2010;92:101-5.
2. Gessmann J, Baecker H. Direct and indirect loading of the Ilizarov external fixator: the effect on the inter fragmentary movements and compressive loads. Strategies Trauma Limb Reconstr 2011;6:27-31.
3. Borzunov DY, Chevardin AV. Ilizarov non-free bone plasty for extensive tibial defects. Int Orthop 2013;37:709-14.
4. El-Mowafi H, El-Alfy B. Functional outcome of salvage of residual and recurrent deformities of clubfoot with Ilizarov technique. Foot Ankle Surg 2009;15:3-6.
5. Makhdoom A, Qureshi PA. Resistant clubfoot deformities managed by Ilizarov distraction histogenesis. Indian J Orthop 2012;46:326-32.
6. Lovisetti G, Sala F. Osteocutaneous thermal necrosis of the leg salvaged by TSF/Ilizarov reconstruction. Report of 7 patients. Int Orthop 2011;35: 121-26.
7. El-Sayed MM, Correll J. Limb sparing reconstructive surgery and Ilizarov lengthening in fibular hemimelia of Achterman-Kalamchi type II patients. J Pediatr Orthop B2010;19:55-60.
8. Hollenbeck ST, Woo S. The combined use of the Ilizarov method and microsurgical techniques for limb salvage. Ann Plast Surg 2009;62:486-91.
9. Ilizarov S. The Ilizarov method: history and scope. In: Rozbruch SR, Ilizarov S, eds. Limb Lengthening and Reconstruction Surgery. Boca Raton, FL: CRC Press; 2006; pp 15-16.
10. Burnei G, Vlad C. Upper and lower limb length equalization: diagnosis, limb lengthening and curtailment, epiphysiodesis. Rom J Intern Med 2012;50:43-59.
11. Edwards CC, Simmons SC. Severe open tibial fractures. Results treating 202 injuries with external fixation. Clin Orthop Relat Res 1988;230:98-115.
12. Tucker HL, Kendra JC. Tibial defects. Reconstruction using the method of Ilizarov as an alternative. Orthop Clin North Am 1990;21:629-37.
13. Maini L, Chadha. The Ilizarov method in infected nonunion of fractures. Injury 2000;31:509-17.
14. Dendrinis GK, Kontos S. Use of the Ilizarov technique for treatment of non-union of the tibia associated with infection. J Bone Joint Surg Am 1995;77:835-46.
15. McKee M, Yoo D. Health status after Ilizarov reconstruction of post traumatic lower-limb deformity. J Bone Joint Surg Br 1998;80:360-4.
16. Paley D, Catagni MA. Ilizarov treatment of tibial non-unions with bone loss. Clin Orthop Relat Res 1989;241:146-65.
17. Seenappa HK, Shukla MK, Narasimhaiah M. Management of complex long bone non-unions using limb reconstruction system. Indian J Orthop 2013;47:602-7.
18. Muhammad SK, Waqas Raza. Outcome of ilizarov fixator in complex non-union of long bones. JPMA 2015(Suppl. 3);65: S-147-51.