

## Chronic midfoot pain and swelling- a diagnostic dilemma?

Shuaib Ahmed<sup>1,\*</sup>, Prashant Acharya<sup>2</sup>, Arjun Naik<sup>3</sup>, Terence D'souza<sup>4</sup>

<sup>1,3</sup>Junior Resident, <sup>2</sup>Associate Professor, <sup>4</sup>Senior Resident, Dept. of Orthopaedics,

**\*Corresponding Author:**

Email: shuaibahmed99@gmail.com

### Abstract

**Introduction:** Chronic foot pain and swelling can pose difficulty in arriving at a diagnosis and appropriate treatment often resulting in inferior outcome.

**Materials and methods:** A 45 year patient with chronic foot pain was evaluated clinically and underwent blood investigations which showed elevated serum uric acid levels (9.1mg/dl). Ankle plain radiograph showed arthritic changes. All of these were pointing towards a differential diagnosis. Synovial biopsy report showed chronic gouty arthritis of foot.

**Discussion:** Chronic midfoot pain and swelling being a diagnostic dilemma must have a panel of differential diagnoses before arriving at a provisional diagnosis.

**Conclusion:** Having known the unusual presentations of gout a thorough evaluation of patient presenting with chronic midfoot pain and swelling should be done.

**Keywords:** Chronic, Foot, Pain, Swelling, Gout

### Introduction

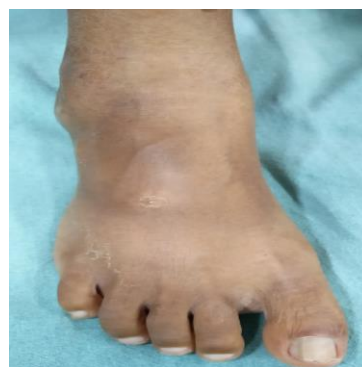In India barefoot walkers presenting with longstanding foot swelling direct the clinicians towards a differential diagnosis of fungal or tubercular infection of the foot. Tuberculosis is quite prevalent in India and hence its possibility cannot be excluded at the time of diagnosis.

The possibility of crystalline arthropathy i.e. gout which is the most common inflammatory arthropathy affecting 1-2% of the population should be included as one of the differential diagnosis. About 10% of people with hyperuricaemia develop clinical gout and continuing crystal deposition is clinically silent.<sup>(1)</sup>

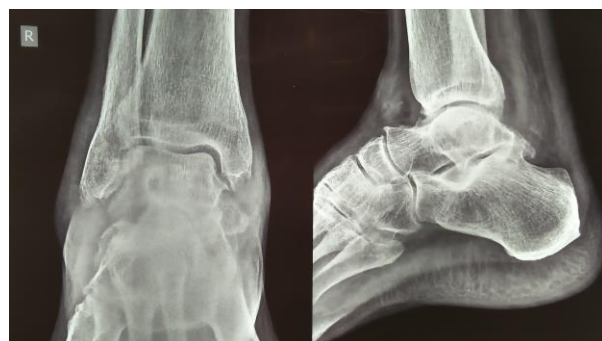### Case Report

A 45 year old male patient driver by occupation presented with complaints of chronic pain and swelling over both his feet of four years duration. Apart from a habit of barefoot walking the history was insignificant. The pain and swelling had been insidious in onset and gradually progressive. Clinical examination revealed soft tissue swelling over midfoot region without any signs of acute inflammation. There was no evidence of a past or present draining sinus. Routine blood work up was normal. Radiology revealed arthritic changes in the midtarsal joints with surrounding osteopenia. With no specific clues as to what the diagnosis was, a provisional diagnosis of Tuberculosis was made and a soft tissue biopsy was performed. In view of his habit of barefoot walking, Madura foot was also considered. To our surprise the histopathology report showed features of chronic gouty arthritis. A repeat blood work up revealed elevated serum uric acid level. A diagnosis of chronic gouty arthritis was made and the patient was put on a therapy of NSAIDs and uric acid lowering agent (Febuxostat). At 3 months follow up there was a

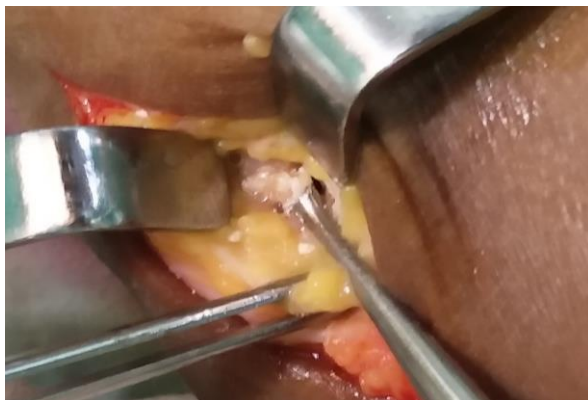subsidence in the pain and swelling, suggesting correct diagnosis and treatment.



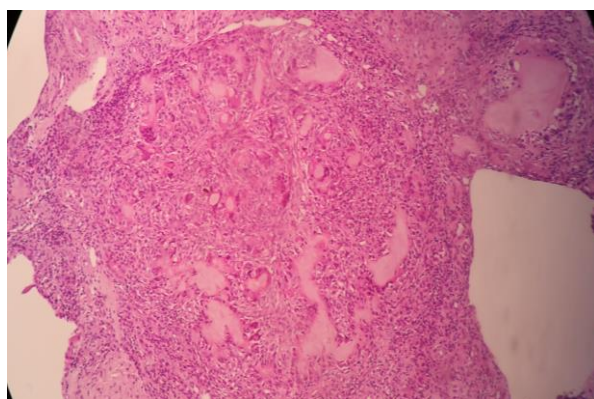
**Fig. 1: Clinical picture showing diffuse swelling in midfoot region**



**Fig. 2: Ankle plain radiograph showing arthritic changes**



**Fig. 3: Intraoperative soft tissue being secured for biopsy**



**Fig. 4: Hematoxylin and eosin stain (low power) showing tophaceous gouty deposits frequently show large pale pink acellular areas, which represent dissolved urate crystals, surrounded by histiocytes and multinucleated giant cells**

### Discussion

Tuberculosis has to be one of the differential diagnosis in any chronic bone and joint involvement because of its ability to mimic other disorders.<sup>(2)</sup> Tuberculosis can involve midtarsal and Lisfranc's joints and present with chronic midfoot pain and swelling.<sup>(3)</sup> Diagnosis is usually based on histopathology as the skeletal involvement is paucibacillary and cultures are rarely positive. A patient presenting with longstanding foot swelling often poses a diagnostic dilemma to the clinician due to its varied differential diagnosis. The first few differential diagnosis which come to mind especially in India among the barefoot walking population is fungal infection and not to forget tuberculosis.

Foot and ankle involvement is very common in Rheumatoid arthritis and in 20% patients this might be the first sign of the disease.<sup>(4)</sup> Rheumatoid arthritis causes swelling in the feet initially due to synovitis which subsequently leads to arthritis manifesting as change in the shape of feet due to arch collapse.

One of the first differential diagnosis to be considered in a patient presenting with foot swelling is

“Madura foot” or mycetoma, a chronic infective condition caused by Actinomycetes bacteria or fungi. It is endemic in tropical countries like India and commonly affects barefoot walkers.<sup>(5)</sup> It manifests with foot swelling which is slow to grow and relatively pain free, which is how our case presented. Discharging sinus with presence of colonial grains in the exudates which is pathognomonic of this condition develops much later in the disease course, and may delay diagnosis. Histopathology and microbiological studies are required for confirmation of diagnosis. When faced with such a case of chronic foot pain and swelling the differentials should include Mycetoma, Tuberculosis, Rheumatoid arthritis, chronic bacterial osteomyelitis as well as rarer causes like eosinophilic fasciitis. Gout though known for its predilection to involve 1<sup>st</sup> metatarsophalangeal joint<sup>(6)</sup> can affect midfoot joints and should be ruled out.

Eosinophilic fasciitis is also known to cause chronic swelling over the feet due to progressive induration and thickening of the skin and soft tissues. Diagnosis is to be confirmed by association of marked eosinophilia.<sup>(7)</sup>

Gout can pose a diagnostic dilemma due to its ability to present in unusual ways. Biomechanical stresses and repeated minor trauma make 1<sup>st</sup> metatarsophalangeal joint more susceptible to gouty arthritis. However it may also affect the midfoot and cause diagnostic difficulty. Typically gout presents with sudden onset pain and features of acute inflammation, which was not the case in our patient. Hyperuricemia may or may not be present during these episodes and as such diagnosis cannot be totally based on laboratory values. Thorough clinical evaluation and histopathological examination may clinch the diagnosis and help in early therapeutic intervention.

### Conclusion

In patients presenting with chronic foot pain and swelling, lack of awareness of unusual presentation of common conditions and typical presentations of uncommon conditions can lead to delay in diagnosis and treatment often resulting in inferior outcome. Since the treatment of all these conditions is totally different, arriving at a correct diagnosis is mandatory to start the correct therapy. A thorough clinical and laboratory evaluation should proceed biopsy in these patients. It is worthwhile remembering that gout can present in many unusual ways and high degree of suspicion may be the only initial factor leading to early diagnosis and treatment in atypical gouty involvement of foot.

### References

1. Vitart V, Rudan I, Hayward C, Gray NK, Floyd J, Palmer CN, et al. SLC2A9 is a newly identified urate transporter influencing serum urate concentration, urate excretion and gout. *Nat Genet* 2008;40:437-42.

2. Nayak B, Dash RR, Mohapatra KC, Panda G. Ankle and Foot Tuberculosis: A Diagnostic Dilemma. *J Family Med Prim Care*. 2014 Apr-Jun;3(2):129–31.
3. Dhillon MS, Nagi DN. *Clin Orthop Relat Res* 2002. May;(398):107-13.
4. Helliwell P, Siddle H, Redmond A. The foot and ankle in rheumatology. *Issue 8(6) Spring 2011*.
5. Kiran Alam et al. *J Glog Infect Dis* 2009. Jan-Jun;1(1):64-7.
6. Ning TC, Keenan RT. Unusual clinical presentations of gout. *Curr Opin Rheumatol* 22:181–87.
7. Hee Seon Lee et al. *Allergy Asthma Immunol Res* 2014 Mar;6(2):179-82.