

Atypical presentation of Gout masquerading as a Soft tissue Sarcoma

Surath Amarnath¹, Surath Harsha Vardhan², Mettu Rami Reddy³, I. V. Renuka^{4,*}

^{1,2}Consultant, ³Associate Professor, ⁴Profesor, ^{1,2,3}Dept. of Orthopaedics, ^{1,2}Amar Orthopaedic Hospital, Andhra Pradesh, ⁴Dept. of Pathology, ^{3,4}NRI Medical College, Andhra Pradesh, India

***Corresponding Author:**

Email: repriya56@gmail.com

Abstract

Introduction: Gout is a disorder of purine metabolism manifested by high serum uric acid levels, recurrent attacks of acute arthritis and deposition of monosodium urate crystals within and around the joints. Peri articular nodules are a challenge to both clinicians and diagnosticians especially if the nodules are large.

Case presentation: A 34 year old male patient presented to the orthopedic clinic with a large localized progressive swelling in the region of the first Metatarsophalangeal joint of foot. Magnetic resonance imaging (MRI) revealed a large well-marginated lobulated, diffuse soft mass lesion around the 1st Metatarsophalangeal joint with encasement of surrounding tendons. The differential diagnoses given were synovial sarcoma, giant cell tumor and Pigmented Villonodular synovitis. Excision biopsy was done and histopathology revealed a classical picture of gouty tophus. Subsequently blood chemistry was done and showed marked hyperuricemia (7.8mg/dl).

Conclusion: We present a case of gouty tophus masquerading as a soft tissue sarcoma. This case report serves to bring about awareness of an uncommon presentation of a common disease. Extraordinary presentations of gout, in its severe form can mimic a soft tissue tumor.

Keywords: Gout, Soft Tissue Sarcoma, Tophi, Nodules.

Introduction

Gouty arthritis was among the earliest diseases to be recognized as a clinical entity. It was first identified by the Egyptians in 2640 BC.⁽¹⁾ Podagra (acute gout occurring in the first metatarsophalangeal joint) was later recognized by Hippocrates in the fifth century BC, who referred to it as 'the unwalkable disease'. Six centuries later, Galen was the first to describe tophi, the crystallized monosodium urate deposits that can follow longstanding hyperuricemia.⁽¹⁾ Gout can affect any part of the body and tophi may be found in synovial membranes, periarticular ligaments, tendons, soft tissues, subcutaneous tissue, Achilles tendon and helix of the ear.⁽²⁾ We present A 34 year old male patient with a large localized progressive swelling in the region of the first Metatarsophalangeal joint of foot which on Magnetic resonance imaging (MRI) was reported a differential diagnosis of synovial sarcoma, giant cell tumor and Pigmented Villonodular synovitis. Histopathology revealed a classical picture of gouty tophus and later blood chemistry showed marked hyperuricemia (7.8mg/dl). We report this case to emphasize the fact that in any extra articular or subcutaneous mass in the region of joints tophaceous gout must be considered in the differential diagnosis.

Case presentation

A 34-year-old male patient presented with pain and localized progressive swelling on the foot over the first metatarsal area since one year. There was no history of trauma. Patient was a known smoker and alcoholic since 20 years. He was also a non-vegetarian. Physical examination revealed a painful well circumscribed, soft

tissue mass measuring approximately 6x5cms, which was nonmobile and located in the foot more on the medial and plantar aspect of Metatarsophalangeal joint. The patient had restriction of movements of the joint. No other swellings were seen elsewhere in the body.

Magnetic resonance imaging (MRI) revealed a large well-marginated lobulated, diffuse soft tissue predominantly low signal mass lesion around the 1st Metatarsophalangeal joint, predominantly on the plantar medial aspect, causing osseous erosions at the 1st metatarsal joint. Abductor hallucis longus tendon is seen in close proximity encased within the tumor with altered architecture. The flexor and extensor hallucis longus tendons are displaced by the tumor. (Fig. 1 A, B) The differential diagnoses given were synovial sarcoma, giant cell tumor and Pigmented Villonodular synovitis.

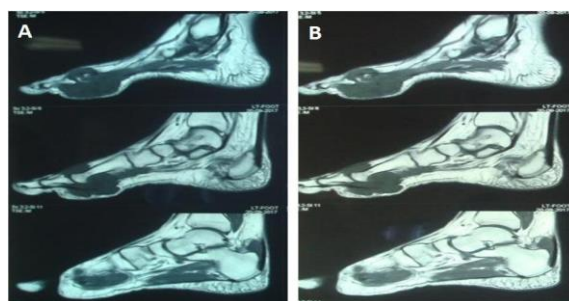


Figure 1: (A): MRI Scan showing lobulated, diffuse soft tissue predominantly low signal mass lesion around the 1st Metatarsophalangeal joint with osseous erosion; (B): MRI Scan on IV contrast showing lesion with intense enhancement and central non-enhancing areas of necrosis.

FNAC was not done as swelling was extremely painful. An excisional biopsy was planned with written audio visual consent from the patient.

Surgery findings: Under regional anaesthesia and tourniquet control a dorso-medial incision was given to gain access to the lesion. A well encapsulated mass was present without adhesions or infiltration to the surrounding tissues. The lateral aspect of the mass posed some difficulty in shelling out, resulting in breach of the capsule. Chalky white material was noticed which pointed a finger of suspicion towards gout. Enbloc removal of the mass exposed the metatarso phalangeal joint showing destruction of the articular cartilage. Since the joint was not salvageable it was arthrodesed and stabilized with a K-wire. Postoperatively, the wound healing was delayed but healed with serial dressings. Pain was reduced and weight bearing commenced after 8 weeks. At 6 months the patient is able to bear weight with minimal inconvenience due to the fusion of the metatarso-phalangeal joint. Patient is on regular follow up and doing well.

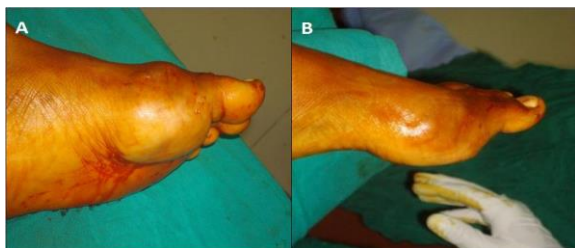

Figure 2: (A & B): Firm mass with lobulated surface located over the first metatarsophalangeal joint, predominantly on the medial and plantar surface.

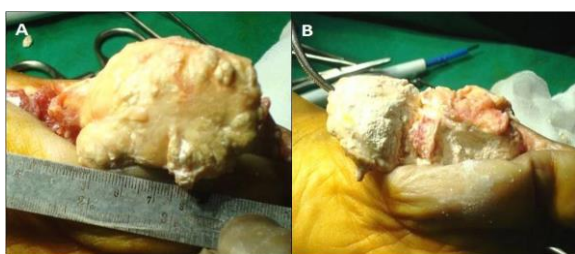


Figure 3: (A): Approximately 6x5 cm mass shelled out; (B): Cut section showing amorphous chalky white material.

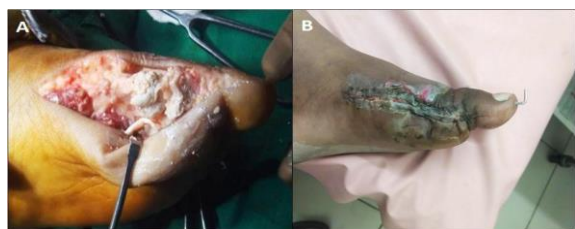

Figure 4 (A): 1st Metatarso-phalangeal joint showing destruction of articular cartilage; (B): At 2 weeks follow up

Histopathology Findings

Macroscopic: Received an irregular mass of size 7x4x3 cms which on cut section revealed a circumscribed gray white lesion of size 5x3x3cms with focal chalky white areas.

Microscopic: lesion was composed of tissue with large areas of eosinophilic fibrillary deposits surrounded by foreign body-type giant cell reaction and palisaded histiocytes (Fig. 5 & 6). Histopathology was that of gouty tophus, no evidence of any neoplasm.

On further investigation serum uric acids levels were found to be elevated (7.8mg/dl). Patient was placed on uricosuric agents and counseled regarding diet. His uric acid levels dropped to physiological limits with treatment.

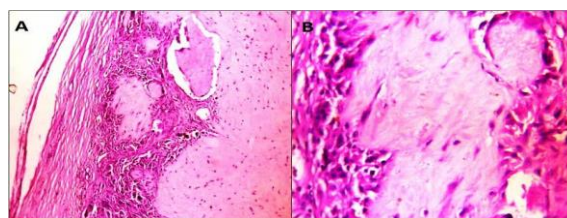


Figure 5 (A&B): Lesion composed of tissue with large areas of eosinophilic fibrillary deposits surrounded by palisaded histiocytes(H&E x 100)

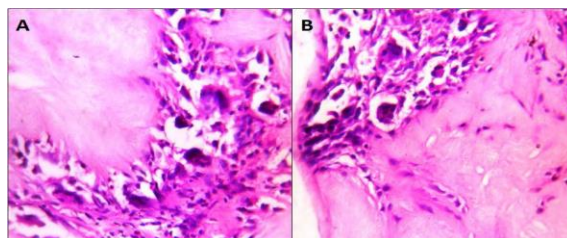


Figure 6: A&B: Urate crystals surrounded by foreign body type of giant cells (H&E x 400)

Discussion

Gout is a disorder of purine metabolism manifested by high serum uric acid levels, recurrent attacks of acute arthritis and also in soft tissues producing masses referred to as tophi.

FNAC is an easy, minimally invasive and cost effective procedure for diagnosing gouty tophus in such a scenario. Mohammad AM et al⁽²⁾ observed that demonstration of monosodium urate crystals was superior in FNAC smears versus histopathology sections in which crystals are more commonly lost during processing.

Emad Y et al⁽³⁾ used FNAC to obtain bursal fluid in an atypical presentation of gout, as olecranon bursitis. They stressed the importance of bursal fluid analysis in such an atypical presentation to look for monosodium urate crystals. The bursal fluid was also examined under polarized microscopy and monosodium urate crystals were identified in the aspirated fluid with negative birefringence which was typical for urate

crystals. In our present case FNAC was not attempted as the patient complained of excruciating pain.

Gouty tophi have been reported to mimic various conditions in other parts of the body. Mohammad AM et al⁽²⁾ reported gout presenting as multiple subcutaneous nodules on both hands and feet including great toe and lateral malleoli. Emad Y et al⁽³⁾ described acute gouty Olecranon bursitis as atypical presentation in normouricemic subjects and suggested that this mode of presentation should be taken into consideration as one of the first presentations of gouty attacks. Ozkan FU et al⁽⁴⁾ reported an uncommon case of tophaceous gout of the knee presenting as a soft tissue mass. A 57-year-old male presented with knee pain and localized progressive swelling increasing in time on the medial side of the proximal tibia. Dogan GB et al⁽⁵⁾ described the clinical and histopathological features of a case of tophaceous gout in a 45-year-old man with chronic arthritis and soft tissue lesions in both ankles and emphasized the importance of considering gout in the differential diagnosis of soft tissue lesions. A case of gout first presenting as carpal tunnel syndrome due to intra tendinous and lumbrical muscle involvement with tophi is also reported in literature by Tan G et al.⁽⁶⁾ Surgical decompression with excision of tophi and diseased muscle produced symptomatic relief. Gouty tophi are also known to mimic tumors of both benign and malignant nature.

Amber H et al⁽⁷⁾ reported an unusual case of intra articular gouty tophi of the knee joint presenting as a locked knee and radiologically mimicking a synovial sarcoma. This is quite similar to our presentation where radiological picture was akin to a neoplasm and both benign and malignant tumors were considered in the radiological differential diagnosis.

Gouty tophus has been reported to mimic a squamous cell carcinoma. Dacko A. et al⁽⁸⁾ report gouty tophus of the periungual region presenting as a hyperkeratotic lesion and whose initial clinical diagnosis favored a squamous cell carcinoma. The presence of pseudoepitheliomatous hyperplasia complicated the diagnosis.

Ultimately we conclude that Gouty tophi can occur in isolation in any musculoskeletal structure, can mimic any condition even a malignant tumor and FNAC followed by biopsy is essential to establish the diagnosis.

Consent: This is to state that the patient has given informed consent for the publication of the case report

Competing Interests: "The authors declare that they have no competing interests".

Acknowledgements and Funding: Nil

Conclusion

What makes this case interesting is that it was referred to our hospital as a soft tissue sarcoma, and imaging studies also were suggestive of a malignant soft tissue tumor. The purpose of this case report is to emphasize the knowledge of varied presentations of gout since diagnostic dilemmas can have an impact on patient treatment and care.

References

1. Nuki G, Simkin PA. A concise history of gout and hyperuricemia and their treatment. *Arthritis Res Ther* 2006;8:1-5.
2. Mohammad AM, Mohan AR, Laxminarayana B, Venishetty H, Akarapu JD, Rani HS. Unusual presentation of gout –A Rare Case Report. *IOSR-JDMS* 2016;1:65-7.
3. Emad Y, Ragab Y, El-Shaarawy N, Rasker JJ. Olecranon bursitis as initial presentation of gout in asymptomatic normouricemic patients. *The Egyptian Rheumatologist* 2014;36:47–50.
4. Ozkan FU, Bilsel K, Turkmen I, Erdil M, Soylemez S, Ozkan K. Tophi gout around the knee joint: An unusual presentation with a soft tissue mass. *International Journal of Case Reports and Images* 2013;4(11):593–596.
5. Dogan GB, Ozdamar SO, Çolak S, Bahadır B, Kuzey GM. Tophaceous Gout of the Ankle Presenting as Soft Tissue Mass: A Case Report of an Uncommon Presentation of a Common Disease. *Turk J Phys Med Rehab* 2006;52:1185-7.
6. Tan G, Chew W, Lai CH. Carpal tunnel syndrome due to gouty infiltration of the lumbrical muscles and flexor tendons. *Hand Surg.* 2003 Jul;8(1):121-5.
7. Amber H, SINGH VA, Azura M. Gouty Tophi Mimicking Synovial Sarcoma of the Knee Joint. *Turk J Rheumatol* 2012;27(3):208-211.
8. Dacko A, Hardick K, McCormack P, Szaniawski W, Davis I. Gouty tophi: a squamous cell carcinoma mimicker? *Dermatol Surg* 2002;28:636–8.