

Proximal femoral nail v/s Dynamic hip screw in treatment of intertrochanteric fracture femur

Keshav Goel^{1,*}, D.K. Taneja²

¹Senior Resident, Dept. of Orthopaedics, Vardhman Mahavir Medical College & Safdarjung Hospital, New Delhi, ²Medical Director, Dept. of Orthopaedics, Arihant Hospital & Research Centre, Indore, Madhya Pradesh, India

***Corresponding Author: Keshav Goel**

Email: drgoelkeshav@gmail.com

Abstract

Objectives: Comparison of operative management and functional outcome of femoral intertrochanteric fractures by dynamic hip screw v/s proximal femoral nail implants.

Materials and Methods: During 2013 to 2016, 50 patients with intertrochanteric femur fracture were prospectively studied. Fractures included were AO type 31 A1 & A2. 25 patients each were taken in two groups DHS & PFN. These groups were compared for functional outcomes based on parameters: Harris hip score, operative time, radiation exposure, blood loss and postoperative rate of union.

Results: The age group in both groups was comparable with mean of 72.9 years. Domestic fall was found to be the most common cause of intertrochanteric fracture femur. Among the patients, 12 had A1 type fracture while 38 of them had A2 type fracture. PFN had the mean blood loss of 111.8ml as compared to 325.6 ml in DHS group. Radiation exposure was greater in PFN than DHS surgery. PFN had the mean operating time of 116.4 min and DHS had 106.4 min. Among the DHS treated group one case had superficial infection while two cases went into non union. Of the PFN treated group Z effect was observed in one case. Although the PFN treated patients showed a better Harris Hip Score on the initial 3 month follow up, both the implants DHS & PFN had a similar functional outcome on long term follow up.

Conclusion: Any patient with intertrochanteric femur fracture AO type 31A1 & A2 treated with good surgical skill and reduction of fracture was achieved has similar results with DHS or PFN.

Keywords: Intertrochanteric fracture, Dynamic hip screw, Proximal femoral nail.

Introduction

In today's world with better medical facilities and ongoing advances in science and medical field the average life span of people has greatly increased. This has led to increasing geriatric population and their problems. One very common fracture in the older age group is Intertrochanteric fractures of femur.¹⁻³ In 1990, of the total world's incidence of hip fracture, Asia alone accounted for 26% of the cases. By 2025 this figure could rise to 37% and upto 45% by 2050.³ In the elder age group, most of the fractures are osteoporotic, resulting from a trivial fall whereas these injuries in young require high energy trauma.⁴

Intertrochanteric fractures have been known since the age of Hippocrates. Sir A Cooper (1822)⁷ gave the classification in the form of femoral extracapsular and intracapsular fractures. Since then the management of these fractures had changed from non operative to operative with the advance of science and knowledge of mankind. Non operative treatment needs prolonged bed rest and traction and are mainly reserved for patients who are unfit for surgery due to other medical comorbidities as it is associated with complications like bed sores, pneumonia, malunion etc. Operative treatment includes reduction of fracture and stable fixation. Patients could be mobilized and early weight bearing is possible after operative modalities. Implants for stable fixation have also evolved over the time from extramedullary devices like SP Nail,⁸ Jewett Nail,¹²

DHS¹⁴ to intramedullary devices like PFN, Gamma Nail. Till date, the gold standard treatment is DHS.⁵

Whereas unstable intertrochanteric fractures are associated with limb shortening, medialization of distal fragment and implant cut.¹ To overcome these complications intramedullary implants came which had the advantage of shorter lever arm, controlled fracture collapse, lesser dissection of soft tissue, shorter duration of operation and early mobilization. The recent literature has shown a dramatic increase in the number of intramedullary devices being used however this increase has not been backed up by scientific evidence but has been driven by factors like marketing by industry, surgeon preference, and reimbursement.⁶

The controversy still continues over the choice of implant for the management of intertrochanteric fracture, specifically the use of proximal femoral nail (intramedullary device) versus dynamic hip screw (extramedullary plate). Thus, this study will help us to evaluate the use and functional outcome after operative management of these fractures with either implants.

Materials and Methods

This prospective study was conducted between August 2013 to December 2016 in the Department of Orthopaedics, Arihant Hospital & Research Centre, Indore, M.P. to compare our results of treatment by dynamic hip screw v/s proximal femoral nail for intertrochanteric fractures of femur OTA/AO 31 A1 &

OTA/AO 31 A2. Both the groups were analyzed statistically & compared for:

1. Intraoperative blood loss
2. Radiation Exposure
3. Mobilization after surgery
4. Union
5. Infection
6. Intra Operative Complication
7. Duration of stay at hospital
8. Implant failure

A total of 50 patients were taken up for the study, 25 each with intertrochanteric fractures of femur AO/OTA 31A1 and 31A2 types. An informed consent was taken from the patients and their relatives after explaining to them about the study and its requirements. The inclusion criteria were all skeletally matured medically fit patients with AO31 A1 & AO31 A2 types of femoral intertrochanteric fractures. Patients with reverse obliquity patterns, subtrochanteric extension, compound or pathological fractures, medically unfit for surgery and those who did not give written consent were excluded from the study.

On arrival, the patients were resuscitated depending on their general condition. Fracture was stabilized using skin traction. A thorough preoperative assessment was done. A detailed history to ascertain the cause of fracture was taken. Radiographs were taken and the patients were then classified using Orthopaedic Trauma Association (OTA) classification into AO31 A1 and AO31A2 types. All patients were operated on an elective basis.

Prophylactic antibiotics were given half hour prior to surgery to all patients. Spinal or epidural anaesthesia was given. The patients were then placed on the

fracture table in supine position and closed reduction of the fracture was done with traction and rotation. The operating surgeon randomly selected implants DHS or PFN for the patients.

Post operatively foot end elevation was given overnight. Drain was monitored. Antibiotics were given. Blood transfusion was given depending upon intraoperative blood loss and post operative haemoglobin. Physiotherapy was started on 3rd day. Time duration from surgery to mobilization was noted. Post-operatively, partial weight bearing with help of walkers was allowed from day 3 to 6 weeks post-op whereas full weight bearing with help of walkers after 6 weeks post-op. Signs of radiological union were assessed. The duration of hospital stay of the patients was noted and they were discharged at variable intervals depending on their general condition and status of the wound. Regular follow up of all the treated patients was done at 6 weeks, 3 months, 6 months and 1 yr postoperatively. On each follow up visit clinical assessment was done using Harris Hip Score, walking ability, shortening, amount of callus formation and fixation defects.

After data collection, data entry was done into Microsoft Excel. Quantitative parametric data was represented as Mean, Standard Deviation. Mean comparison between study groups was done using Student's Unpaired 't' test and comparison of non-parametric data was done using chi-square test. P value of less than 0.05 was taken as significant. Data analysis was done with the help of MiniTab Version 17.0. The final data was presented in the form of tables and graphs.

Graph 1

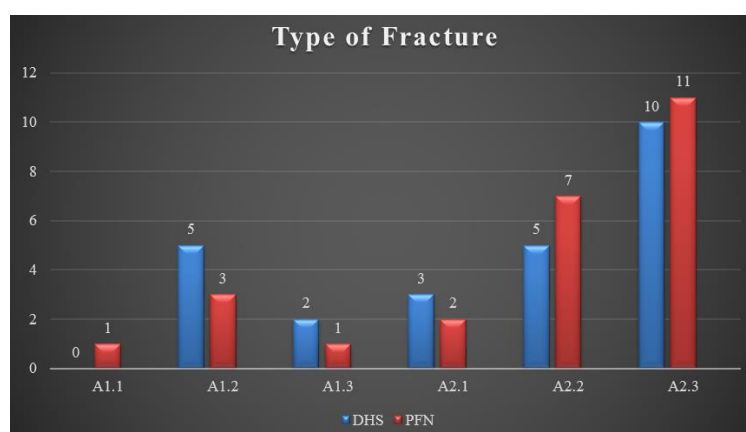


Table 1

	DHS	PFN
Operative time	106.4 ± 9.63	116.4 ± 32.67
Radiation	31.24 ± 2.37	62.92 ± 7.51
Blood loss	325.60 ± 30.97	111.80 ± 50.68
Hospital stay	5.44 ± 2.63	6.76 ± 5.91
Mobilization	2.44	3.16

HHS[3M]	29.52 ± 5.03	48.44 ± 6.33
HHS[6M]	68.48 ± 7.42	76.92 ± 6.89
HHS[1Y]	84.92 ± 10.14	88.00 ± 6.63
Infection	1	0
Non union	2	0
Z effect	0	1
Union time	16.3	15.36

Results

In our study there were 24 males and 26 females. The youngest case was 42 years old male and the oldest was a male of 97 years old. The mean age was 72.90 with standard deviation of 12.05. Students unpaired 't' test was used to compare the mean ages of DHS and PFN group. The P value obtained was > 0.05, which is statistically not significant. In our study 21 patients had fracture of left side & 29 had right sided fracture. The mechanism of injury was fall from height in 4 cases, road traffic accident in another 4 cases whereas 42 cases got injured by a trivial slip & fall at home, mostly bathroom. We classified the cases of intertrochanteric femoral fractures by AO Classification. In DHS group 7 cases were of A1 type and 18 cases of A2 type. In PFN group 5 cases were of A1 type and 20 cases of A2 type. The maximum no. of cases had AO 31A2.3 type of intertrochanteric fracture followed by AO31A2.2 type. Most of the cases were discharged within 4-5 days. In both the groups approximately 80% cases were mobilized with partial weight bearing within 5 days. The average time to mobilize in our present study in DHS group was 2.44 days and PFN group was 3.16 days. One case in the DHS group had superficial infection for which debridement was done. Non-union occurred in two cases of DHS group. Revision surgery with PFN was done in both the cases. The Z effect complication occurred in one case of the PFN group for which revision surgery was done. In our present study the mean operative time for DHS surgery was 106.40 min and PFN surgery was 116.4 min. (P value > 0.05, statistically not significant). The mean blood loss in the DHS group was 325.6 ml whereas the mean in PFN group was 111.8 ml i.e. more blood loss in DHS surgery (P < 0.05, statistically significant). There was a greater radiation exposure in PFN group (mean 62.92) as compared to the radiation exposure in the DHS group (mean 31.24), which is statistically significant with a P value < 0.05. The time to union was determined by the time when fracture line is no longer visible radiologically. In our present study approximately 50% cases showed union within 16 weeks of surgery by DHS or PFN. 2 cases in DHS group went into non union. The final functional outcome after 12 months assessed using Harris Hip Score showed excellent results in 11 patients in both the groups while a poor result was seen in 5 cases in the DHS and 1 case in the PFN group. Statistical difference was assessed using the Chi-square test. P value

obtained was > 0.05, which is statistically not significant.

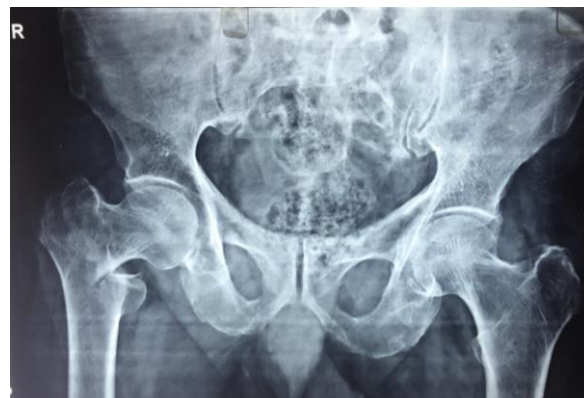

Fig. 1: Pre op DHS

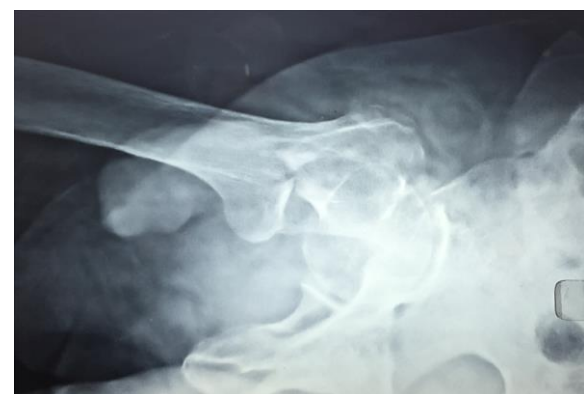

Fig. 2: Pre op Lat DHS

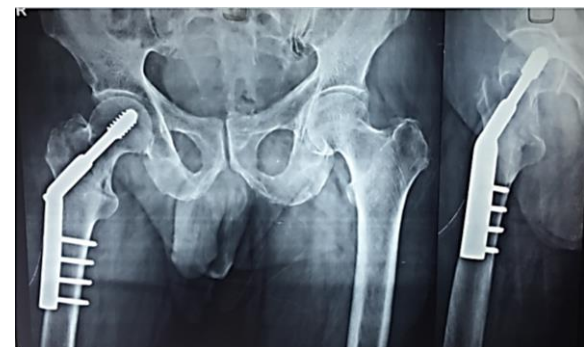


Fig. 3: Post op

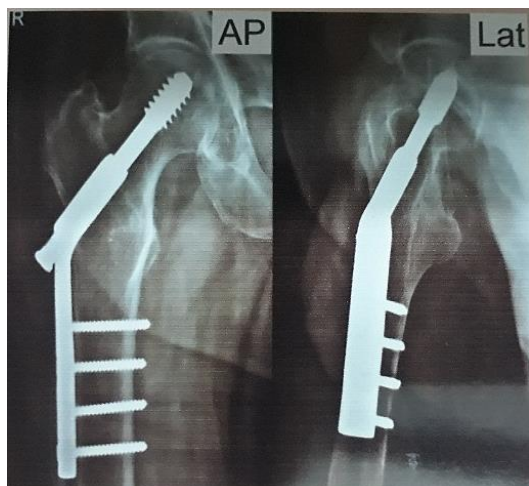


Fig. 4: Fol up

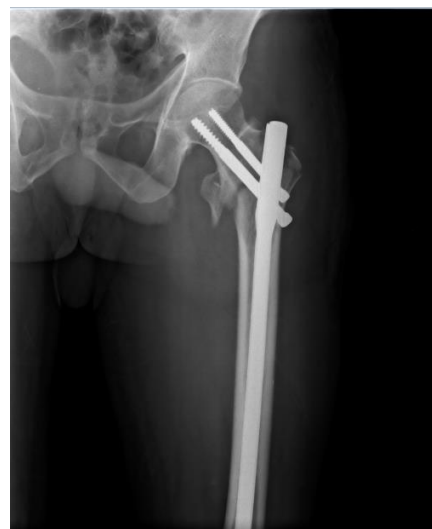

Fig. 7: Post op AP

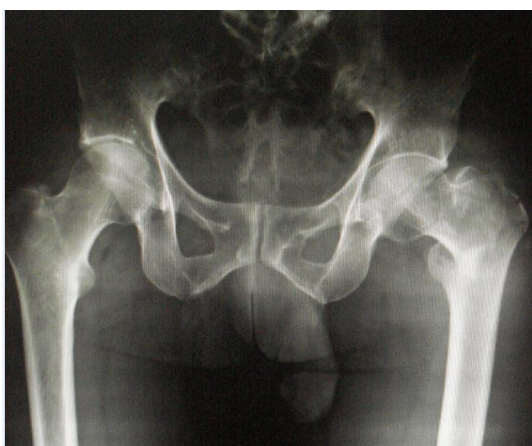


Fig. 5: Pre op AP PFN

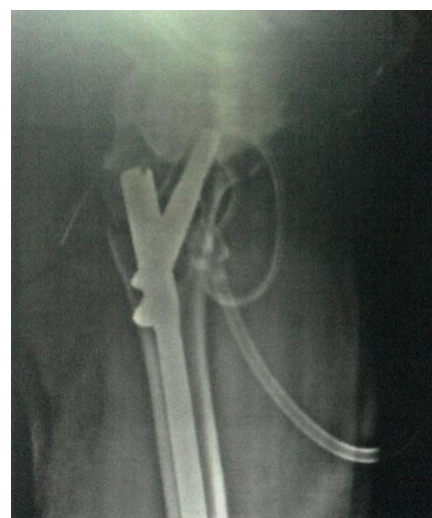

Fig. 8: Post op Lat

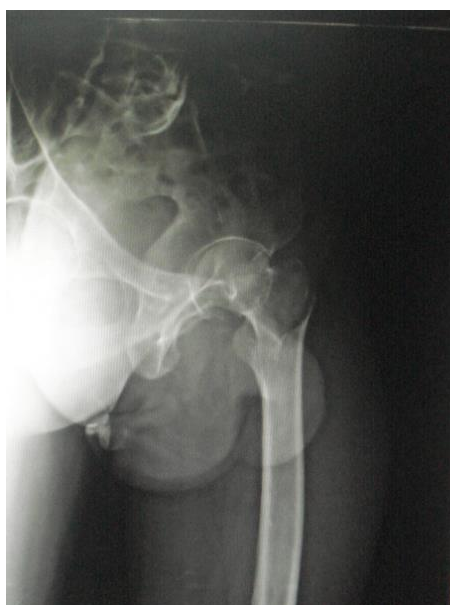

Fig. 6: Pre op PFN

Discussion

The intertrochanteric femur fractures are often difficult to be reduced and fixed in their anatomical position. The aim of management of these fractures have changed over the years with the advance of science from non operative to operative measures to achieve early mobilization and less bedridden complications. Implants for the internal fixation are also being continuously evolved in course of time from fixed nail plate devices to sliding hip screw plates to intramedullary devices.

Since 1960's the gold standard for the operative management of such fractures has been Dynamic Hip Screw (DHS) but lately from 1990 there has been a change of trend towards intramedullary devices. Dynamic Hip Screw works on the principle of controlled collapse of fracture.¹⁴ It has complications like varus collapse at fracture, shortening of femoral neck, rotational instability and implant failure.^{27,29,30} Intramedullary devices (Proximal femoral nail) are

close to the mechanical axis of femur so moment arm is less in them leading to less tensile stress thus behaving as load sharing devices.²⁴ It has disadvantages like Z effect, implant back out, not suitable for medial comminution and high learning curve.³⁶ Thus the best treatment for these fractures still remains controversial.

Intertrochanteric femoral fractures with reverse oblique pattern and subtrochanteric extension showed high failure rates, complications and requirement of revision surgeries with dynamic hip screw, therefore the use of Proximal femoral nails is superior in such cases.^{33,35}

Age, Sex & Mechanism of Fracture: In our study both DHS and PFN patients were comparable in terms of age and sex. The mean age for DHS patients was 70.64 years and for PFN group was 75.16 years. The mean age for both the groups combined was 72.90 years. The main reason for fracture was trivial fall at home (mostly in the bathroom) in the patients above 60 yrs of age while younger patients had road traffic accident (RTA) and fall from height (FFA) as the major cause for femoral fractures. Cummings and Nevitt in 1994.⁴⁸ explained the reason for this as inadequate protective reflexes, reduced energy below critical threshold, inadequate local shock absorbers e.g. muscle and fat around hip and inadequate bone strength at the hip on account of osteoporosis or osteomalacia in the older age group.

Operative Time: The average intraoperative time in DHS group was 106.40 min with standard deviation of 9.63 min and that in PFN group was 116.4 min with standard deviation of 32.67 min. Though this difference was not statistically significant ($p=0.149$), it could be due to PFN being relatively new method with less experience in the technique especially in the earlier cases. Pajarinen et al²⁷ showed more intraoperative duration in PFN than DHS while Saudan et al²⁶ and Kumar et al³³ a lesser duration in PFN as compared to DHS.

Blood Loss: On comparing the blood loss in our study we found higher blood loss with DHS group which was statistically significant. This could be accounted to larger incision and more soft tissue dissection leading to intramuscular bleed and a higher blood loss in cases of DHS group. Saudan et al,²⁶ Pajarinen et al,²⁷ Kumar et al³³ have all shown significantly higher blood loss in DHS surgery.

Radiation: We found that the mean radiation exposure in DHS patients was 31.24 with standard deviation of 2.37 and that in PFN patients was 62.92 with standard deviation of 7.51. The radiation exposure was more in PFN patients which was statistically significant ($p<0.05$). The study by Kumar et al³³ showed radiation exposure to be 40 in DHS group and 70 in PFN group, difference being statistically significant which correlates with our study.

Complications: We have not faced any intra-operative complications in any of the two groups. After weight

bearing collapse of fracture was seen in 4 cases of DHS group while 2 cases of the same went into non union. Infection was seen in only one case in the DHS group. It was superficial for which debridement was done on the 3rd post op day. The patient was continued on 3 weeks of intravenous antibiotics. The implant was left in place. Z effect complication was seen in a single case of the PFN group. Revision surgery was required for 3 cases in the DHS group whereas only 1 case in the PFN group was revised.

Hospital Stay and Mobilization: Average hospital stay was comparable in the two groups. Most of the patients were mobilized within 5 days of surgery whether treated by DHS or PFN.

Union: Radiological union was achieved within 16 weeks in approximately 50% cases in both the groups and in between 16-24 weeks in most of the remaining cases. In DHS group, 2 cases (8%) went into non union and none in the PFN group. Saudan et al²⁶ found 7 (36.8%) non union cases in DHS group and 1 (5%) in PFN group.

Functional Result: The patients were followed up and the two groups were compared for the final functional outcome at the end of 1 year. The average Harris Hip Score was assessed, the score being 84.92 with standard deviation of 10.14 in the DHS group and 88.00 with standard deviation of 6.63 in the PFN group (statistically not significant). 11 cases (44%) in both the groups showed excellent results followed by good results in 7 cases of DHS and 11 cases of PFN. Poor results were seen in 5 cases of DHS and a single case of PFN. The result indicates no difference in the functional outcome between the two surgeries.

Conclusion

DHS remains the best treatment and implant of choice due to its ease of procedure, low rate of complications and favorable results. Its biomechanical properties which provide control compression at fracture site improves fracture healing.⁴⁷ But its larger exposure, more blood loss and operative time with complications like varus collapse, implant cut out and increased infection rate has led to the use of alternate implants. Factors like fracture comminution, incorrect placement of screw, failure of fixation device and osteoporosis usually leads to implant failure. Central placement of screw with the optimal Tip Apex Distance²² in the femoral head (both AP and lateral views) is the key for successful DHS surgery.

The PFN has gained wide popularity in the recent years as it has shown to withstand higher static and cyclical loading being biomechanically stronger than DHS.^{42,47} It acts as buttress in preventing medialization of shaft. In experienced hands it has shown less surgical exposure, less operative time, less blood loss and early return to pre-morbid conditions. But it also has its limitations with high learning curve, high implant cost and complications like Z effect and reverse Z effect.

For good results with PFN it is necessary to reduce the fracture before placing the implant. It should be entered just medial to tip of the greater trochanter. The derotation screw should be parallel and 10 mm shorter than the compression screw to avoid Z effect.

Finally, biological internal fixation of intertrochanteric fracture reduces intraoperative morbidity of the patients. Both DHS and PFN are equally good surgeries for Intertrochanteric femoral fractures AO/OTA 31A1 and 31A2 types if done with expertise. Anatomical reduction, good surgical technique and correct screw placement is the key to success. Intra operative technical difficulties associated with PFN can be reduced by thorough knowledge and understanding of both the anatomy and implant.

Conflicts of Interest: None.

References

- Carter DR, Hayes WC. The compressive behavior of bone as a two-phase porous structure. *J Bone Joint Surg Am.* 1977;59(7):954-62.
- Gullberg B, Johnell O, Kanis JA. World-wide projections for hip fracture. *Osteoporos Int.* 1997;7(5):407-13.
- Melton LJ, Kearns AE, Atkinson EJ, Bolander ME, Achenbach SJ, Huddleston JM. Secular trends in hip fracture incidence and recurrence. *Osteoporos Int.* 2009;20(5):687-694.
- Russell TA. Intertrochanteric fractures. Chapter 48. In: Bucholz RW, Heckman JD, Court-Brown CM, Tornetta P (ed.) *Rockwood And Green's Fractures in Adults*, 7th Ed. Philadelphia: Lippincott Williams & Wilkins, 2010, pp. 1597-1641.
- Kulkarni G S, Limaye R, Kulkarni M, Kulkarni S. Intertrochanteric fractures. *Indian J Orthop* 2006;40:16-23
- Anglen JO, Weinstein JN; American Board of Orthopaedic Surgery Research Committee. Nail or plate fixation of intertrochanteric hip fractures: changing pattern of practice. A review of the American Board of Orthopaedic Surgery Database. *J Bone Joint Surg Am.* 2008;90(4):700-7.
- Cooper AP. *A Treatise on dislocations and fractures of the joints.* London, England: Longman, Hurst, Rees, Orme and Brown; 1822.
- Petersen S. Treatment of fractures of the neck of the femur by internal fixation. *Surg Gynecol Obstet.* 1937;64:287.
- Thornton L. The treatment of trochanteric fracture of the femur: two new methods. *Piedmont Hospital Bulletin.* 1937;10:21-37.
- Boyd HB, Griffin LL. Classifications and treatment of Trochanteric fractures. *Arch Surg.* 1949;58:853-866.
- Evans E. The treatment of trochanteric fractures of the femur. *JBJS.* 1949;31B:190-203.
- Jewett EL. One piece angle nail for trochanteric fractures. *J Bone Joint Surg Am.* 1941;23(4):803-10.
- Cleveland M, Bosworth Dm, Thompson Fr, Wilson HJ Jr, Ishizuka T. A ten-year analysis of intertrochanteric fractures of the femur. *J Bone Joint Surg Am.* 1959;41-A:1399-408.
- Clawson DK. Trochanteric fractures treated by the sliding screw plate fixation method. *J Trauma.* 1964;27:737-52.
- Sarmiento A. Avoidance of Complications of Internal Fixation of Intertrochanteric Fractures Experience With 250 Consecutive Cases. *Clinical Orthopaedics & Related Research.* 1967;53:47-60.
- Dimon JH, Hughston JC. Unstable intertrochanteric fractures of hip. *J Bone Joint Surg Am.* 1967;49(3):440-50.
- Harrington KD, Johnson JO. The management of comminuted unstable intertrochanteric fractures. *J Bone Joint Surg Am.* 1973;55(7):1367-6.
- Dhal A, Verghese M, Bhasin VB. External fixation of intertrochanteric fractures of femur. *J Bone Joint Surg Br.* 1991;73-B(6):955-8.
- Halder SC: The Gamma nail for peritrochanteric fractures *JBJS.* 1992;74-B:340-4.
- Leung KS1, So WS, Shen WY, Hui PW. Gamma nails and dynamic hip screws for peritrochanteric fractures. A randomised prospective study in elderly patients. *J Bone Joint Surg Br.* 1992;74(3):345-51.
- Parker MJ, Palmer CR. A new mobility score for predicting mortality after hip fracture. *J Bone Joint Surg Br.* 1993;75-B(5):797-8.
- Baumgaertner MR, Curtin SL, Lindskog DM, Keggi JM. The value of the tip-apex distance in predicting failure of fixation of peritrochanteric fractures of the hip. *J Bone Joint Surg Am.* 1995;77(7):1058-64.
- Bartl R, Hofer F. Placement of anti-rotation screw using a fixed parallel bore guide device in dynamic hip screw management of hip para-articular femoral fractures. *Unfallchirurgie.* 1996;22(2):85-7.
- Simmermacher RK, Bosch AM, Van der Werken C. The AO/ASIF-proximal femoral nail (PFN): a new device for the treatment of unstable proximal femoral fractures. *Injury.* 1999;30(5):327-32.
- Hoffmann R, Schmidmaier G, Schulz R, Schütz M, Südkamp NP. Classic nail versus DHS. A prospective randomised study of fixation of trochanteric femur fractures. *Unfallchirurg.* 1999;102(3):182-90.
- Saudan M, Lübbecke A, Sadowski C, Riand N, Stern R, Hoffmeyer P. Peritrochanteric fractures: is there an advantage to an intramedullary nail?: a randomized, prospective study of 206 patients comparing the dynamic hip screw and proximal femoral nail. *J Orthop Trauma.* 2002;16(6):386-93.
- Pajarinen J, Lindahl J, Michelsson O, Savolainen V, Hirvensalo E. Peritrochanteric femoral fractures treated with a dynamic hip screw or a proximal femoral nail. A randomised study comparing post-operative rehabilitation. *J Bone Joint Surg Br.* 2005;87(1):76-81.
- Kulkarni GS, Limaye R, Kulkarni M, Kulkarni S. Intertrochanteric fractures. *IJO.* 2006;40(1):16-23.
- Zhao C, Liu DY, Guo JJ, Li LP, Zheng YF, Yang HB, Sun JH. Comparison of proximal femoral nail and dynamic hip screw for treating intertrochanteric fractures. [Article in Chinese]. *Zhongguo Gu Shang.* 2009;22(7):535-7.
- Zou J, Xu Y, Yang H. A comparison of proximal femoral nail antirotation and dynamic hip screw devices in trochanteric fractures. *J Int Med Res.* 2009 ;37(4):1057-64.
- Parker MJ, Handoll HH. Gamma and other cephalocondylic intramedullary nails versus extramedullary implants for extracapsular hip fractures in adults. *Cochrane Database Syst Rev.* 2010;8(9):CD000093.
- Barton TM, Gleeson R, Topliss C, Greenwood R, Harries WJ, Chesser TJ. A comparison of the long gamma nail with the sliding hip screw for the treatment of AO/OTA 31-A2 fractures of the proximal part of the femur: a

- prospective randomized trial. *J Bone Joint Surg Am.* 2010;92(4):792-8.
33. Kumar R, Singh RN, Singh BN. Comparative prospective study of proximal femoral nail and dynamic hip screw in treatment of intertrochanteric fracture femur. *Journal of Clinical Orthopaedic and Trauma.* 2012;3(1):28-36.
 34. Kam NK, Jain A, Nepal P, Singh MP, Das N. A Prospective Randomized Control Trial Comparing Proximal Femoral Nail and Sliding Hip Screw in The Management of Trochanteric Fracture of The Femur. *Health Renaissance.* 2011;9(1):7-11.
 35. Bhakat U, Bandyopadhyaya R. Comparative Study between Proximal Femoral Nailing and Dynamic Hip Screw in Intertrochanteric Fracture of Femur. *Open Journal of Orthopaedics.* 2013;3:291-5.
 36. Huang X, Leung F, Xiang Z, Tan PY, Yang J, Wei DQ, Yu X. Proximal Femoral Nail versus Dynamic Hip Screw Fixation for Trochanteric Fractures: A Meta-Analysis of Randomized Controlled Trials. *The Scientific World Journal.* 2013;2013:805805.
 37. Aktseles I, Kokoroghiannis C, Fragkomichalos E, Koundis G, Deligeorgis A, Daskalakis E. Prospective randomised controlled trial of an intramedullary nail versus a sliding hip screw for intertrochanteric fractures of the femur. *Int Orthop.* 2014;38(1):155-61.
 - Weinlein JC. Fractures and dislocations of the hip. Chapter 55. In: Canale ST, Beaty JH (ed) *Campbell's Operative Orthopaedics*, 12th Ed. Missouri: Mosby Elsevier 2013, p. 2725-75.
 38. Trueta J, Harrison MH. The normal vascular anatomy of the femoral head in adult man. *J Bone Joint Surg Br.* 1953;35-B(3):442-61.
 39. Harty M: The Calcar femorale and femoral neck. *J Bone Joint Surg Am.* 1957;39-A(3):625-30.
 40. Griffin JB: The Calcar Femorale Redefined. *Clin Orthop Relat Res.* 1982;(164):211-4.
 41. Curtis MJ, Jinnah RH, Wilson V, Cunningham BW. Proximal femoral fractures: a biomechanical study to compare intramedullary or extramedullary fixation. *Injury.* 1994;25(2):99-104.
 42. Singh M, Nagrath AR, Maini PS. Changes in trabecular pattern of the upper end of the femur as an index of osteoporosis. *J Bone Joint Surg Am.* 1970;52(3):457-67.
 43. Marsh JL. OTA fracture classification. Compendium citation: Fracture and Dislocation classification compendium – 2007: Orthopaedic Trauma Association Classification, Database and Outcomes Committee. *J Orthop Trauma.* 2007;21(Suppl.10):S1-S163.
 44. Muller ME, Allgower M, Schneider R, Willenegger II. Manual of internal fixation: techniques recommended by the AO-ASIF group, 3rd Ed. Berlin: Springer-Verlag, 1991.
 45. Gotfried Y. The lateral trochanteric wall: a key element in the reconstruction of unstable peritrochanteric hip fractures. *Clin Orthop Relat Res.* 2004;425:82-6.
 46. Kaufer H, Matthews LS, Sonstegard D, Arbor A. Stable Fixation of Intertrochanteric Fractures: A biomechanical evaluation. *J Bone Joint Surg Am.* 1974;56(5):899-907.
 47. Cummings SR, Nevitt MC. Non-skeletal determinants of fractures: the potential importance of the mechanics of falls. Study of Osteoporotic Fractures Research Group. *Osteoporos Int.* 1994;4 Suppl 1:67-70.
 48. Wu CC, Shih CH, Lee MY, Tai CL. Biomechanical analysis of location of lag screw of a dynamic hip screw in treatment of unstable intertrochanteric fracture. *J Trauma.* 1996;41(4):699-702.
 49. Ward FO: *Human Anatomy*, London, Renshaw, 1838.
 50. Kuntschner G. Intramedullary surgical technique and its place in orthopaedic surgery. *JBJS.* 1965;47-A:809-18.
 51. Ender J, Simon-Weidner R. Die Fixierung der trochantener brüche mit runden elastischen Kondylennageln. *Acta Chir Austria.* 1970;1:40.

How to cite this article: Goel K, Taneja DK. Proximal femoral nail v/s Dynamic hip screw in treatment of intertrochanteric fracture femur. *Indian J Orthop Surg.* 2018;4(3):249-255.