

Hoffa's fat pad disease: A study

Maruthi CV^{1,*}, Venugopal N²

¹Assistant professor, Department of Orthopaedics,
Chamarajanagar Institute of Medical Sciences, Chamarajanagar, Chamarajanagar, Karnataka, India

²Professor, Department of orthopaedics, MVJMC, Hoskote, Bangalore, India

***Corresponding Author:**

E-mail: orthocvmaruthi@gmail.com

ABSTRACT

Introduction: German surgeon by name Albert Hoffa in 1904 described the condition which was producing severe anterior knee pain was called Hoffa's fat pad disease. This disease is commonly encountered in athletes after the second decade. The lowest age present in the literature with symptomatic Hoffa's fat pad disease is ten years. Most common pathology in Hoffa's fat pad disease is impingement of fat pad between anterior margin of tibia and intercondylar notch of femur. Here we are done an attempt to know the aetiology, diagnosis and management of the Hoffa's fat pad disease.

Materials and methods: 150 cases of knee joint pain were evaluated in our institute. 107 cases were suffering from medial margin pain, twenty nine cases from lateral margin, seven over and adjacent to ligamentum patella, three from inferior pole of patella, three from tibial tuberosity and one had pain at superior pole of patella. We studied seven patients suffering from Hoffa's fat pad disease from April 2011 to December 2014 in our hospital. Inclusion criteria were age group between ten to sixty years irrespective of sex suffering from anterior knee pain with tenderness and swelling over and adjacent to the ligamentum patella. The exclusion criteria were age less than ten and more than sixty, pain at the suprapatellar region, inferior pole, superior pole of patella, at tibial tuberosity only, along medial and lateral margin of knee, popliteal fossa were excluded from our study. We have done a study to know the causes, how to diagnose the problem and management.

Conclusion: Hoffa's disease is common after second decade, rare in children. Usually it is seen in athletes. Squatting, running, climbing stairs, trauma and postsurgical scarring are the causes encountered in our study. Diagnosis is by history, clinical examination and radiological investigations like X-ray and Magnetic resonance imaging. Conservative management is the first line of treatment for three to four months and if it fails most of them were treated by complete excision of Hoffa's fat pad through anterior arthrotomy.

Keywords: Hoffa's disease, Anterior knee pain, X-Ray, MRI, Arthrotomy.

Access this article online	
Quick Response Code:	Website:
	www.innovativepublication.com
	DOI: 10.5958/2395-1362.2015.00033.X

INTRODUCTION

In 1904 Albert Hoffa a German surgeon was first to describe the condition of the knee joint with anterior knee pain and it was called Hoffa's Fat pad disease.¹Hoffa's disease is associated with chronic anterior knee pain, below the patella². Most of the patients present in the fifth decade³. Hoffa's fat pad disease is also seen in athletes after second decade. The youngest patient reported in the literature is ten years suffering from Hoffa's fat pad disease. The common pathology is impingement of fat pad between femoral intercondylar notch anterior margin of tibia and patella. We have done a study to know the aetiology, diagnosis and management for the disease.

MATERIALS AND METHODS

150 cases of knee joint pain were evaluated in our institute. 107 cases were suffering from medial margin pain, twenty nine cases from lateral margin, seven over and adjacent to ligamentum patella, three from inferior pole of patella, three from tibial tuberosity and one had pain at superior pole of patella. We studied seven patients suffering from Hoffa's fat pad disease from April 2011 to December 2014 in our hospital. Inclusion criteria were age group between ten to sixty years irrespective of sex suffering from anterior knee pain with tenderness and swelling over and adjacent to the ligamentum patella. The exclusion criteria were age less than ten and more than sixty, pain at the suprapatellar region, inferior pole, superior pole of patella, at tibial tuberosity only, along medial and lateral margin of knee, popliteal fossa were excluded from our study. We have done a study to know the causes, how to diagnose the problem and management.

Table 1 and 2.

Table 1: Demographic factors and clinical features

SL. No	Age in yrs	Side	Symptoms	Duration in months	Cause	Flexion extension arc(In Degrees)	Swelling size (In Cms)
1	10	right	Pain and Swelling	4	Squatting, Running	10-90	5x4
2	17	right	Pain and swelling	3	Running,	10-100	4x3
3	23	right	Pain and swelling	2	Trauma	15-100	3x3
4	28	right	Pain and swelling	5	climbing stairs	10-90	5x5
5	34	right	Pain and swelling	1	Trauma	10-90	3x2
6	39	right	Pain and swelling	4	Squatting climbing stairs	10-90	5x4
7	52	left	Pain and swelling	3	Post-surgical, Climbing stairs	20-80	5x3

Table 2: Investigations and treatment for Hoffa's fat pad disease

SL. No	Age in yrs	Sex	X Ray Prominent soft tissue shadow between inferior pole and tibial articular margin.	MRI T1W shows enlarged infrapatellar pad of fat with reduced signal intensity and T2W shows hyperintensity in the same region	Conservatively management	Surgery
1	10	Male	Present	Present		surgery
2	17	Male	Present	Present		surgery
3	23	Male	Present	Present	conservative	
4	28	Male	Present	Present		surgery
5	34	Male	Present	Present	conservative	
6	39	Male	Present	Present		surgery
7	52	Male	Present	Present		surgery

In our study all were males one was in the age group of 10 years, one in 17 years and remaining all were above second decade. In our entire cases right knee was affected except in post-surgical case left knee. In all the symptoms were pain and swelling in the anterior knee. On examination there was tenderness over and adjacent to the patellar tendon, swelling was more prominent between inferior pole of patella and anterior tibial articular margin during full knee extension (Fig 1). Hoffa's test, a test where the pressure applied on either side of patellar tendon in a flexed knee with gradual extension causes apprehension in the patient, which was positive in all our seven cases. Knee movements were restricted in all our patients. The aetiology in most our cases is climbing stairs, running and sitting in squatting position and post-surgical as an arthroscopic debridement for the osteoarthritis of knee joint. All the patients were subjected to the X-ray examination which shows prominent shadow between the inferior

pole of patella and anterior tibial margin (Fig 2), and In MRI T1W shows enlarged infrapatellar pad of fat with reduced signal intensity and T2W shows hyper intensity in the same region (Fig 3). In our study five patients were managed by surgery as they were resistant to conservative treatment for four months duration. They were managed by open arthrotomy technique under spinal anaesthesia (Fig 4), as in our institute we were not having the facility of arthroscopic surgery and two by conservative management, in the form of rest and anti-inflammatory therapy. After excision of the pad of fat, tissue was sent for histopathological examination, which revealed inflammatory changes in the tissue excised in all five cases. All surgically managed patients were relieved of symptoms by two weeks post-surgery and able to perform activities of daily living.

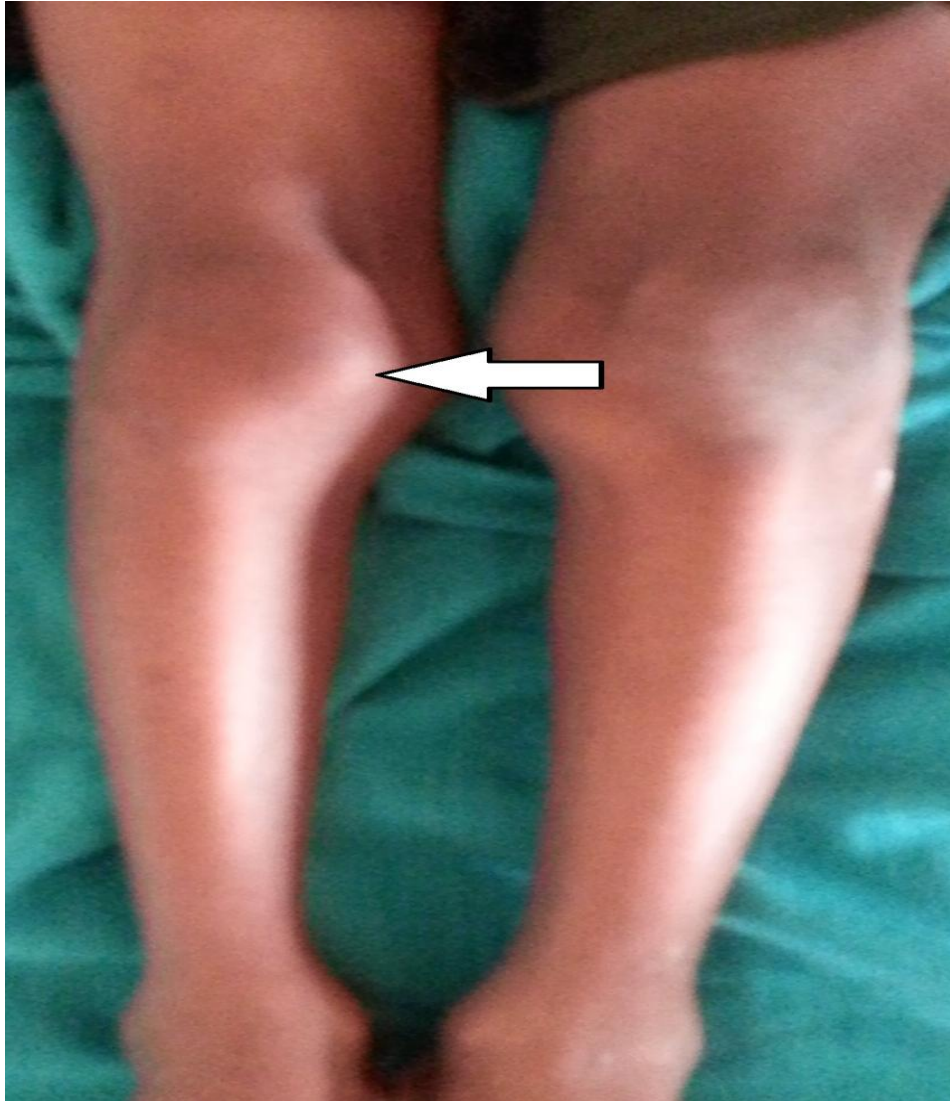

Fig-1

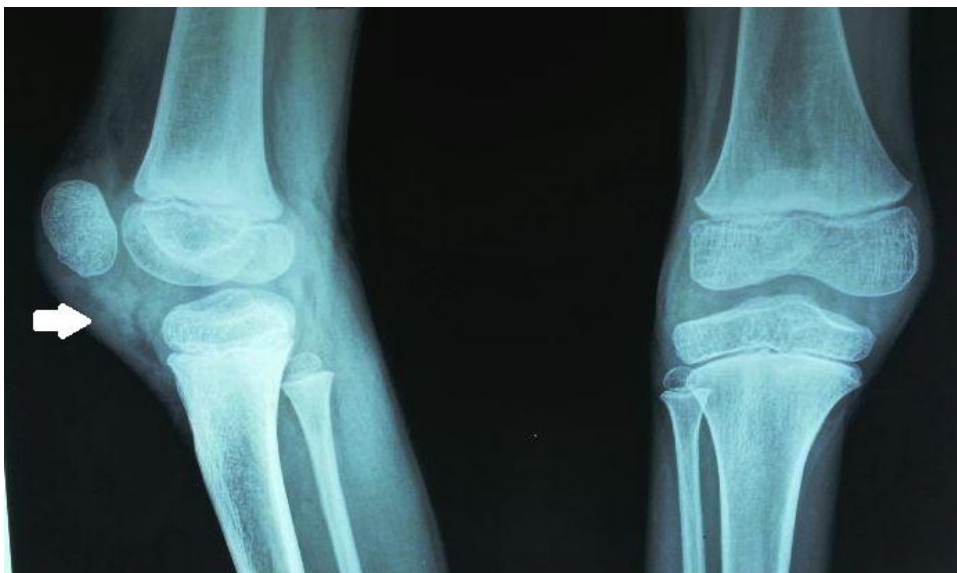

Fig-2

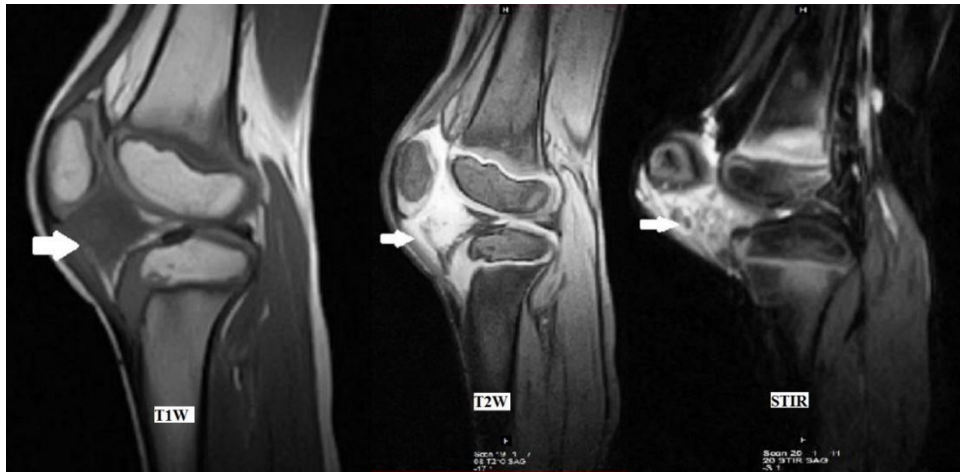

Fig-3

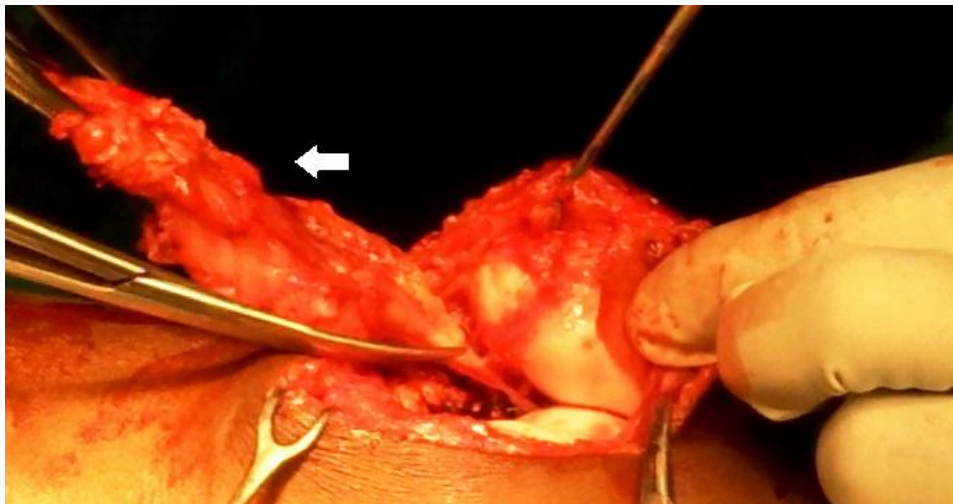


Fig-4

DISCUSSION

There are three fat pads near anterior aspect of the knee. Two in the suprapatellar that is one within the quadriceps and another one anterior to the femur just proximal to the articular cartilage. Usually suprapatellar one's are not prone for disorders. The most common clinically significant fat pad in the anterior aspect of the knee joint is infrapatellar fat pad, first described by Albert Hoffa hence it is named as Hoffa's fat pad disease. Which is a small pyramidal shaped, extrasynovial and intracapsular structure present in the infrapatellar region. The fat pad is richly innervated by neurovascular tissue [4]. The most common and usual function of the fat pad is, it prevents abnormal stresses over the patella during extreme movements of the knee joint [5]. The clinical presentation of the Hoffa's fat pad disease is pain, swelling, limp and difficulty in walking. The examination of the knee joint, show tender swelling in the infrapatellar region, along anterior aspect of the knee. And Hoffa's test was positive in all patients suffering from Hoffa's fat pad disease. The diagnosis

is confirmed by X-ray examination of the knee joint in anteroposterior views, shows soft tissue shadow in the infrapatellar region. And MRI examination of the knee joint is necessary to confirm it is Hoffa's fat pad disease. The differential diagnosis of the condition is lipoma, villonodular synovitis, osteochondroma, synovitis, synovial chondromatosis, ganglion cyst, chondroma and Hoffa's fat pad disease. The differentiating feature of infrapatellar bursitis from Hoffa's disease is the presence of tenderness along the lower part of ligamentum patella and MRI shows hyper intensity within the lower part of ligamentum patella in T2W images. In Sinding Larsen disease, there will be tenderness and swelling at the junction of inferior pole of patella and ligament patella. The chondromatosis arising in Hoffa's fat pad disease is differentiated from Hoffa's fat pad disease by the presence of ovoid solitary lesion in Magnetic Resonance Imaging and the histopathological features are similar to extraarticular synovial chondromatosis. Ganglion cyst of the Hoffa's fat pad is a cystic swelling along anterolateral aspect of knee

with Magnetic resonance imaging features of High signal intensity in T2W images and confirmed by histopathological features of ganglion. Haemangioma arising Hoffa's fat pad disease is diagnosed by Magnetic resonance imaging showing Hyperintensity in T2W and isointensity in T1W images and histopathology showing features of haemangioma. The acute trauma, extremes of knee flexion and extension in kicking and jumping, post surgical scar after arthroscopic debridement also a causative factor for the disease[6,7]. The x-ray examination of the knee joint show a shadow in the infrapatellar region and magnetic resonance imaging examination show in T1W images reduced signal intensity of the enlarged fat pad and hyper intensity in T2W images[8, 9]. The treatment of the condition is conservative using nonsteroidal anti-inflammatory drugs in, rest, ice therapy [10,11]. If the patients are not responding to the conservative management for three to four months are managed by excising the fat of pad through arthroscopy or by anterior arthrotomy [12]. In our study we managed five cases suffering from Hoffa's fat disease by arthrotomy and excision of the fat pad. After excising the tissue, it was sent to histopathological examination, confirms the diagnosis as the excised tissue was showing signs of inflammation [13]. Hoffa's fat pad disease histopathologically show synovial proliferation with chronic nonspecific perivascular inflammatory cell infiltrate, predominantly composed of lymphocytes.

CONCLUSION

Hoffa's disease is common after second decade, rare in children. The disease is commonly seen in athletes. Squatting, running, climbing stairs, trauma and postsurgical scarring are the other causes encountered in our study. Diagnosis is by clinical examination and Magnetic resonance imaging. Conservative management is the first line of treatment and if it fails most of them need complete excision of Hoffa's fat pad by arthrotomy.

REFERENCES

- Hoffa A. The influence of adipose tissue with regard to pathology of the knee joint. JAMA. 1904;43:795-796..
- Rafael Burgomeister Lourenco, Marcelo Bordalo Rodrigues. WHICH IS YOUR DIAGNOSIS? Radiol Bras.2007;40(3):IX-X.
- Michael R Carmount, Sian Davies, Daniel Gey Van Pittius and Robin Rees Accelerated para-articular osteochondroma formation within the knee: a case report Cases J 2008, 1:6.
- Drago JL, Johnson C, McConnell J. Evaluation and treatment of disorders of the infrapatellar fat pad. Sports Med. 2012; 42:51-67.
- BohnsackM, Hurschler C, Derirtas T, Rijnmann O, Stukenborg-Colsman C, Wirth CJ. INfrapatellar fat pad pressure and volume changes of the anterior compartment during knee motion: possible clinical consequences to the anterior knee pain syndrome. Knee SurgSportsTraumatol Arthroscopy.2005; 13:135-141.
- Witvrouw E, Lysens R, Bellemans J, Cambier D, Vanderstraeten G. Intrinsic risk factors for the development of anterior knee pain in an athletic population. A two-year prospective study. Am J Sports Med. 2000 Jul-Aug; 28(4):480-9.
- Chung CB, Skaf A, Roger B, Campos J, Stump X, Resnick D. Patellar tendon-lateral femoral condyle friction syndrome: MR imaging in 42 patients. Skeletal Radiol. 2001 Dec; 30(12):694-7.
- Saddik D, McNally EG, Richardson M, MRI of Hoffa's fat pad. Skeletal radiol. 2004; 33:433-444.
- L.V. von Engelhardt, E. Tokmakidis, M. Lahner, A. Dávid, P. Haage, B. Bouillon, et al. Hoffa's fat pad impingement treated arthroscopically: related findings on preoperative MRI in a case series of 62 patients. Arch Orthop Trauma Surg, 130 (2010), pp. 1041-1051 www.clinicalsportsmedicine.com (Chapter 24)
- Moriri G, Chiodi E, Centanni F, Gattazzo D. Hoffa's disease of adipose tissue; MRI vs Surgical findings. Radiol Med (torino) 1998;95:278-85.
- Kumar D, Alnand A, Beacon JP. Impingement of infrapatellar fat pad (Hoffa's disease): results of high-portal arthroscopic resection. Arthroscopy. 2007 Nov;23(11):1180-1186.
- BJF Dean, JJ Mathews, DW Reed, H Pandit, E McNally, NA Athanasou et al. The Surgical Management of Hoffa's Fat Pad Tumours: J Bone Joint Surg Br. 2010;92-B no SUPP III 417.