

# Treatment of displaced intracapsular neck fractures in active elderly patient: A Prospective overview of Osteosynthesis versus Prosthesis in 46 patients

Satyendra Phuljhele<sup>1</sup>, Rajendra Kumar Ahire<sup>2\*</sup>, Harshal Sakale<sup>3</sup>

<sup>1</sup>Prof and HOD, <sup>2,3</sup>Assistant Prof., Dept. of Orthopaedics, PT JNMCM RAIPUR

**\*Corresponding Author:**

E-mail: ahire.rk@gmail.com

## ABSTRACT

**Introduction:** This paper determines if Osteosynthesis or Prosthesis replacement should be the treatment of choice, in active elderly patient with unstable intracapsular neck femur fracture.

**Material and Methods:** A prospective analysis of the results of 46 patients that were performed in Pt. J.N.M. Medical College and associated Dr. B.R.A.M. Hospital Raipur (C.G.) over a period of 2 year was undertaken. The minimum period of follow-up was 2 years.

**Results:** Out of these 46, 31 patients were treated with internal fixation (Richard's compressive hip screw with supplementary cancellous screw fixation) and 15 patients were treated with Hemiarthroplasty (Austin Moore Unipolar Endoprosthesis). Overall, the average age of patients was 62.5 years. The mean age for internal fixation was 59 years and that of Hemiarthroplasty was 66 years. 61% of the patients were between 55-65 years of age group. Overall 29 patient (63%) were male and 17 patient were female (37%). Union occurred in 89% of cases in internal fixation. Overall, the functional outcome in internal fixation group was satisfactory with excellent/ good result found in 78% of cases, while in Hemiarthroplasty group it was 63%. Osteosynthesis group has less complication rate like pain, infection, fracture of shaft of femur, shortening and mortality than Hemiarthroplasty group.

**Conclusion:** Osteosynthesis is justified as a primary treatment of intracapsular hip fracture even in displaced type in active elderly patient aged 55-65 years. Prosthesis replacement should be used in cases where neck is absorbed, in failed Osteosynthesis and in Non-union.

**Keywords:** Neck femur, Elderly, Osteosynthesis, Prosthesis

Access this article online	
<b>Quick Response Code:</b>	<b>Website:</b>
	www.innovativepublication.com
	<b>DOI:</b>
	10.5958/2395-1362.2015.00036.5

## INTRODUCTION

Majority of femoral neck fractures occurs in elderly patients with osteopenic bone by trivial strains, but no age is immune to it. The incidence of hip fractures rises with increasing age, doubling for each decade beyond 50 years of age<sup>5</sup>. Tradition held that displaced intracapsular fractures in elderly patients were treated by reduction and internal fixation in the Scandinavian countries, whilst for much of the rest of Europe and America femoral head replacement was used. This fracture was termed the unsolved fracture, because of this controversy<sup>1</sup>. This is reflected by the increasing tendency to abandon treatment by reduction and fixation, and to replace the femoral head with prosthesis. This policy, which amount to a confession of failure, would be fully justified if every subcapital failed to unite. But non-

union does not always occur, and many such fractures heal with modern methods of treatment<sup>3</sup>.

Orthopaedic surgeons vary in their management of displaced intracapsular fractures of the hip in healthy older patients<sup>4</sup>. Although internal fixation is recommended for most non-displaced fracture of the femur, the optimal treatment for displaced fracture of the femoral neck is controversial. Option for operative treatment of displaced fracture of the femoral neck include: reduction and Internal fixation; Unipolar Hemiarthroplasty; Bipolar Hemiarthroplasty; and total hip Arthroplasty<sup>6</sup>.

In selecting a treatment for these fractures it is of utmost importance and priority to select the method that incurs the lowest mortality and morbidity and yet allows and permits early mobilization and rehabilitation to previous activities and independence. The aim of this study is to determine the functional, clinical outcome of two different types of surgical treatment in a displaced intracapsular fracture of femur with particular reference to physiological active patient where the controversy is to its maximum.

## MATERIAL AND METHOD

This study was carried out in department of Orthopaedics, Pt. J.N.M. Medical College and associated Dr. B. R. Ambedkar Memorial Hospital Raipur (C.G.), prospectively from 2006 to 2008 for the treatment of fracture intracapsular neck femur. All the patients of fracture intracapsular neck femur with special reference to 55-65 year of age group were included in this study. The detailed history of mode and duration of injury was recorded. History of preexisting pain in hip, difficulty in walking and associated diseases was also recorded. Patient's general condition was assessed and detailed systemic examination was done to exclude any concomitant disease. Affected limb was examined for deformity and shortening. Investigation like hematological, biochemical, Electrocardiogram and Roentgenogram of chest was done to assess the patient for surgery and anaesthesia. X-ray pelvis with both hip-AP view was taken to assess the type of fracture as per Garden's classification. X-ray of the affected hip with thigh- AP view in 15 degree Abduction and 10 degree internal rotation was taken to assess the position of neck and extent of osteoporosis. X-ray of affected hip with thigh lateral view was taken to assess posterior comminution.

Inclusion criteria for internal fixation (Richard's compressive hip screw with supplementary cancellous screw) is (a) all Garden's grade 1-4 intracapsular fracture neck femur (b) trauma-surgery duration less than 3 weeks. Inclusion criteria for Hemiarthroplasty (Austin Moore unipolar Endoprosthesis) (a) unstable intracapsular fracture neck femur garden's grade 3-4 (b) trauma-surgery duration more than 3 weeks. (c) absorption of neck.

**Preoperative Treatment:** Above knee skin traction or proximal tibial skeletal traction was applied in all the cases while waiting for surgery for relieving pain, to check the extreme rotation, and to correct the deformity.

### Procedure:

#### A) STEPS OF OPERATION (Hemiarthroplasty)

Under Spinal /epidural anaesthesia, a semi-prone position was given and a modified Gibson's approach was used. Appropriate size of unipolar component was determined by measuring the excised femoral head through template. Neck was cut with motorized saw then medullary cavity was reamed, keeping the entry point posterior and lateral over greater trochanter. A trial fitting of the prosthetic head was always made in the acetabulum. Prosthesis was seated into the shaft with the help of impactor. Reduction of prosthetic head was done. The stability of the prosthetic replacement was checked.

The wound was closed in layers over a negative suction drain.

#### B) STEPS OF OPERATION

(Richard's compression Hip screw with supplementary cancellous screw fixation). The patient was kept in supine position on the radiolucent fracture table. Reduction was done by Leadbetter technique and checked under image both in AP and cross table lateral view paying special attention to cortical contact medially and posterior. Lateral approach to proximal shaft and trochantric region was used. Precortex drilling of lateral cortex was done with the help of 4.5 mm drill bit at a point which is approximately 2cm below the vastuslateralis ridge or tip of lesser trochanter. Then a threaded guide-wire (3.2mm) was inserted with the help of angle guide under image intensifier. The position of guide wire should be just inferior to the central sector in AP view and central in lateral view. We attempted to place the DHS preferably slightly below the centre, to achieve firm engagement in the dense calcar femorale and also for rotational cancellous screw fixation proximal to it. The tip of the guide wire should be within 10 mm of the articular surface of head. The lag screw length of the guide wire was measured with the help of measuring gauze and then guide wire was advanced to the subchondral region to provide temporary stability during reaming. Reaming is done with the help of triple reamer followed by taping. The measured lag screw was inserted through guide wire with the help of insertion wrench. Then the side plate (2 hole / 3 hole) is advanced into the lag Screw and the plate is secured to the shaft with plate clamp or bone holder. After drilling 4.5mm cortical screw was tightened. Now traction was released and the top screw was tightened over lag screw. Then a 2.4mm threaded pin was passed under image guidance proximal to the lag screw in AP view and centrally in lateral view. Drilling was done with the help of 6.5mm cannulated drill bit, tapped and finally an appropriate size of cannulated cancellous screw with washer was tightened. In post operative care, Active quadriceps drill was started and sitting of the patient allowed with active movement of Ankle and toes started from 2<sup>nd</sup> day. Non weight bearing ambulation with walker was started and stitches were removed on 10<sup>th</sup> post operative day. After 3 weeks partial weight bearing and after 6 weeks full weight bearing ambulation was started. Patient was followed every month for first three months followed by every three monthly for one year. Subsequently 6 monthly follow up was done. Patients who did not return up on the given date were contacted personally or by questionnaire or by telephone.

At the time of each follow up, patients were followed both clinically and radiologically (AP and lateral view) to see fracture related and implant

related complications. Evaluation of the function of the hip was done by Oxford Hip Score (OHS). Results were graded as per as oxford hip score- Excellent- 12-20, Good-21-30, Poor -31-60.

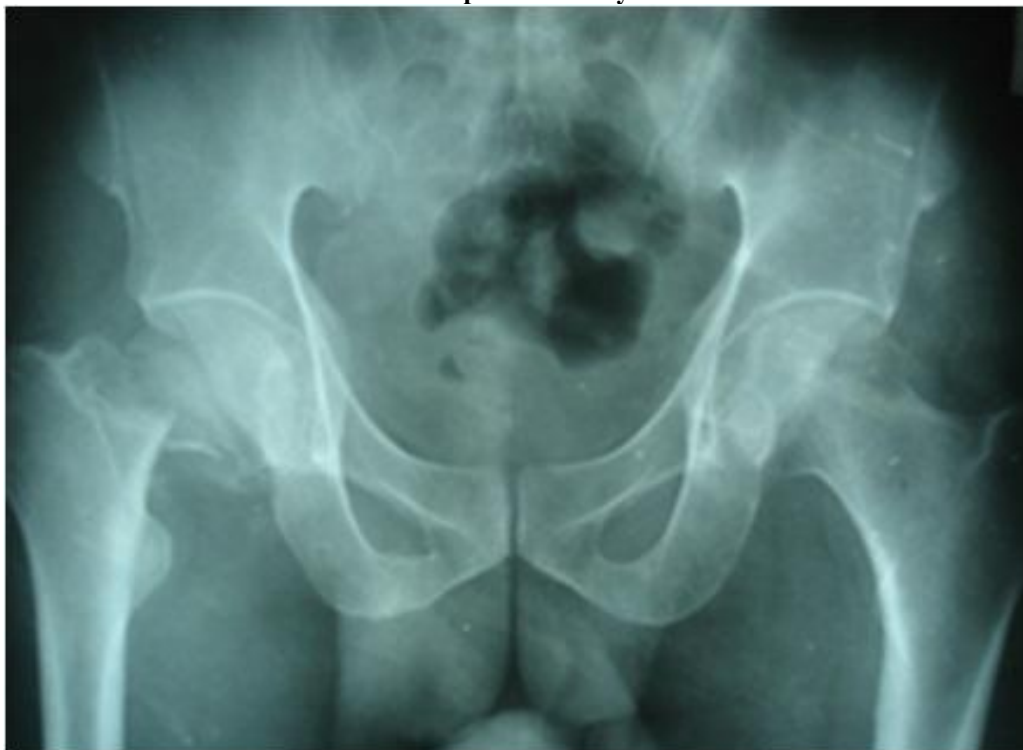## RESULTS

From year 2006 to 2008, 46 patients with intracapsular neck fracture were treated in our institute. Out of these 46 patient 31 were treated with internal fixation(Richard's compressive hip screw with supplementary cancellous screw fixation) and 15 patients were treated with Hemiarthroplasty (Austin Moore Unipolar Endoprosthesis). The mean age for internal fixation was 59 years and that of Hemiarthroplasty was 66 years. 61% of the patients were between 55-65 years of age group. Overall 32 patient(69.5%) were male and 14 patient were female (30%). The incidence of subcapital type of fracture is 76.32% (35 cases), basal type is 15.2% (7 cases) and transcervical type is 8.69% (4 cases). In Internal fixation group stable type fracture (Garden's grade 1& 2) is found to be 36% and unstable fracture (Garden's grade 3&4) is found to be 64%, whereas in Hemiarthroplasty group all patients were garden's grade 4. Maximum patients were treated within a 10 days of trauma in internal fixation group (range 2-18 days), whereas in Hemiarthroplasty group trauma-surgery interval ranges 12 days to 4.5 months. The

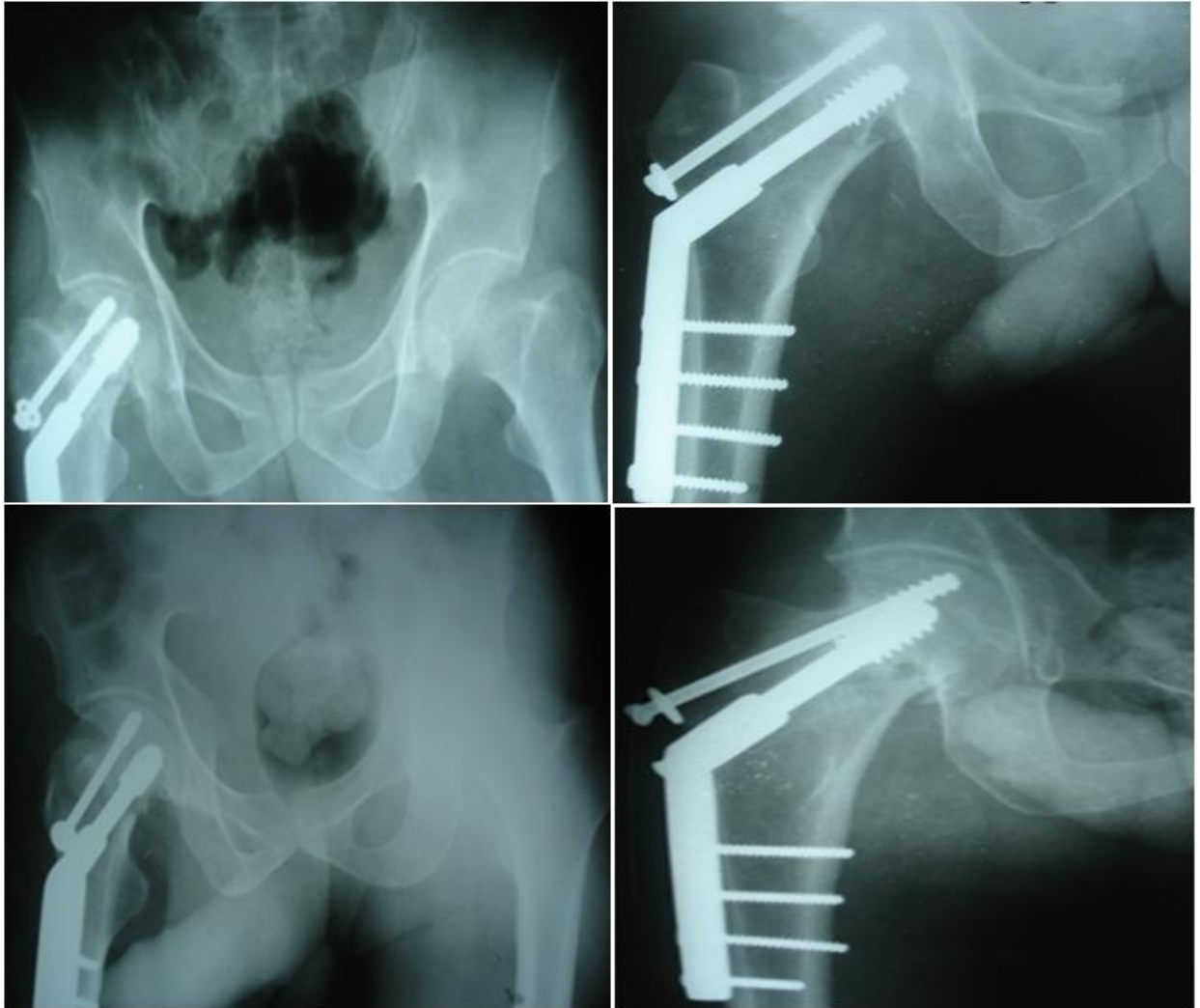most common mode of trauma was fall over hard surface (59%). The most common size of implant used- prosthesis of 43 sizes, Richard's plate of 135 degrees short barrel with 2 holes, DHS of size 85mm and cancellous screw of size 80 mm. The average period of hospital stay in internal fixation group is 18 days whereas in Hemiarthroplasty group is 27 days. Union (maintained reduction, no persistence of fracture line, trabecular line formation) occur in 89% of cases at 6 months of follow up. Non union occurred in 11% of cases due to failure of implant and there are no cases of delayed union. Overall results of functional outcome(OHS score) is satisfactory (excellent and good) for internal fixation group is 77% and for Hemiarthroplasty is 66%. In internal fixation group- superficial wound infection occur in 2 cases (6.45%) and no deep wound infection occurs, implant failure with DHS cut out occur in 2 cases (6.4%) and none of the patient have shortening. In Hemiarthroplasty group-fracture of the shaft of femur (Intra-operative) occur in 1 cases (6.6%), dislocation occur in 2 cases (13%), superficial wound infection occur in 3 cases(20%) and deep wound infection occur in 2 case (13%), acetabular erosion occur in 1 case(6.6), stem loosening occur in 2 patient(13%) and shortening of limb occur in 4 cases (26.6%).

### Case 1: OSTEOSYNTHESIS DONE IN 4 YRS MALE

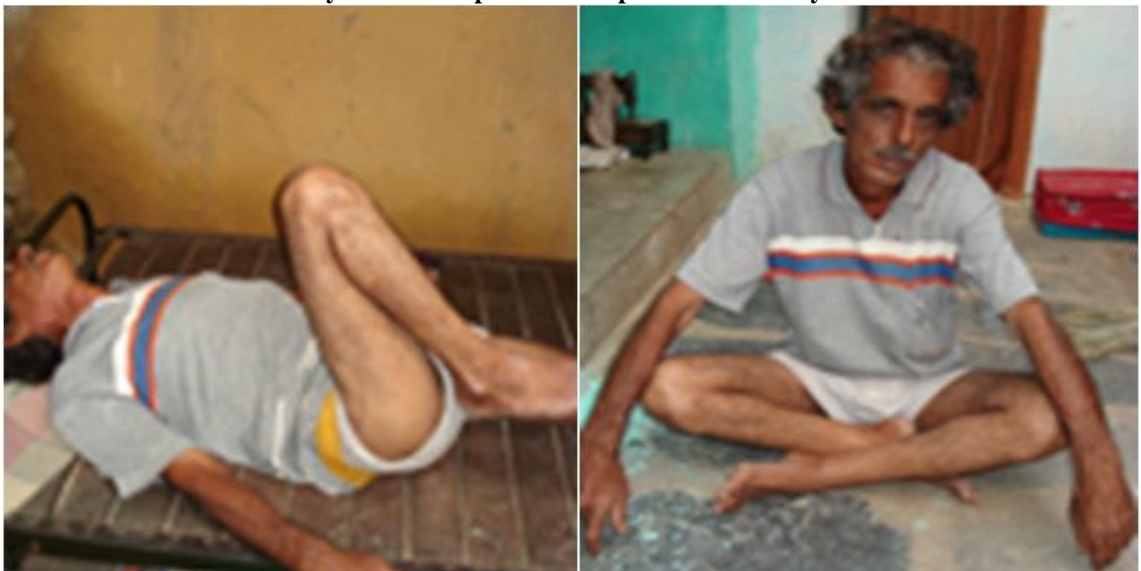#### Preoperative X-ray

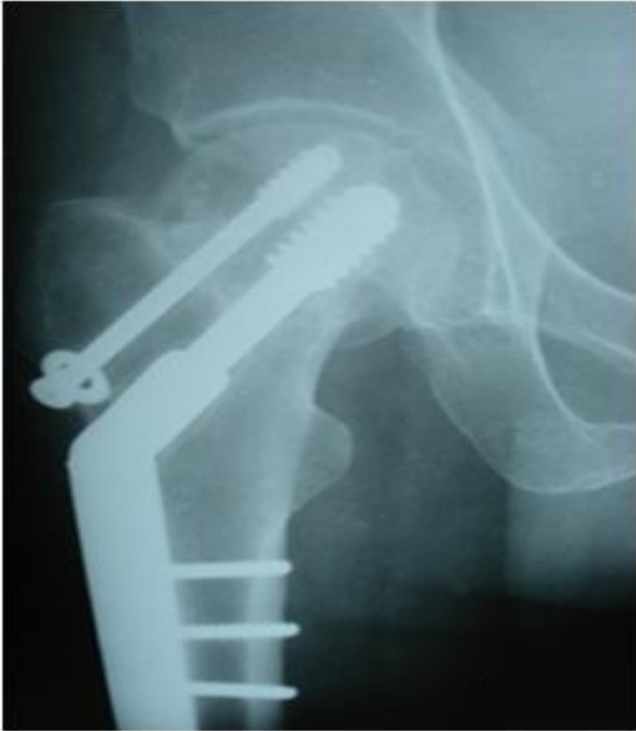

**Immediate Post-Operative [Osteosynthesis with DHS and Derotation Screw Done and 3 Months Postoperative**



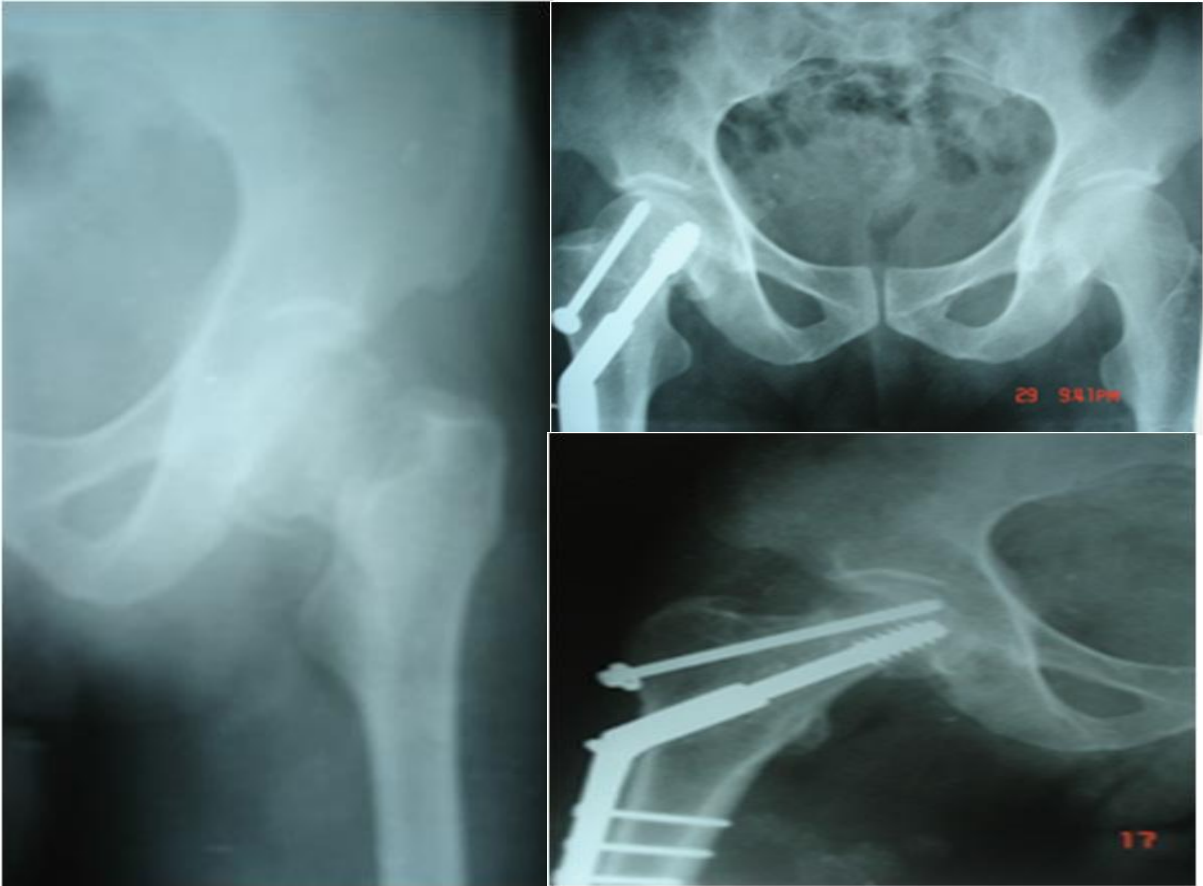
**1 year follow up functional pictures and x rays**



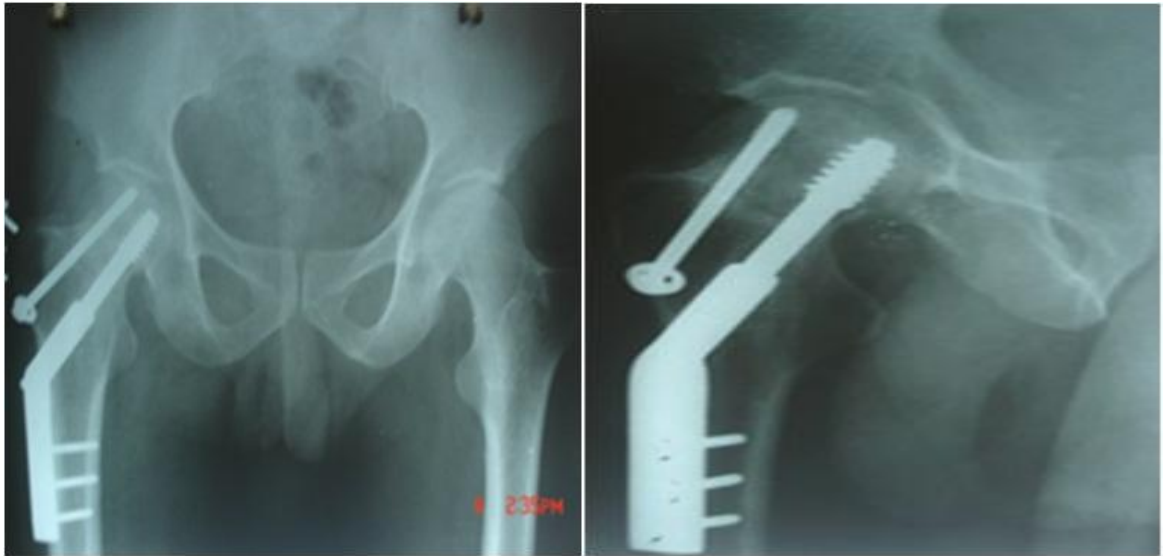

Case 2:OSTEOSYNTHESIS

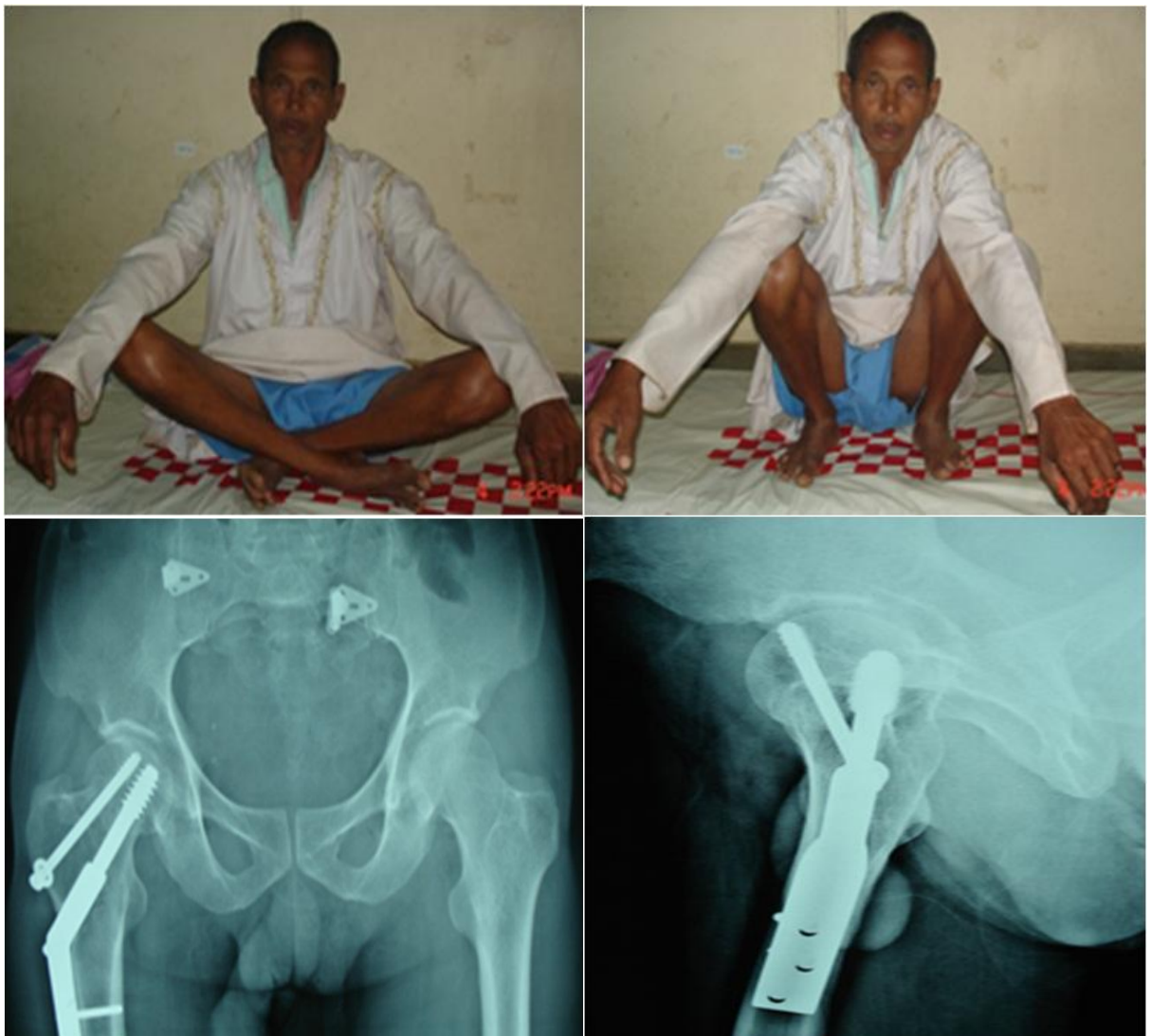PREOPERATIVE AND POSTOPERATIVE XRAYS



**3 MONTHS FOLLOW UP**

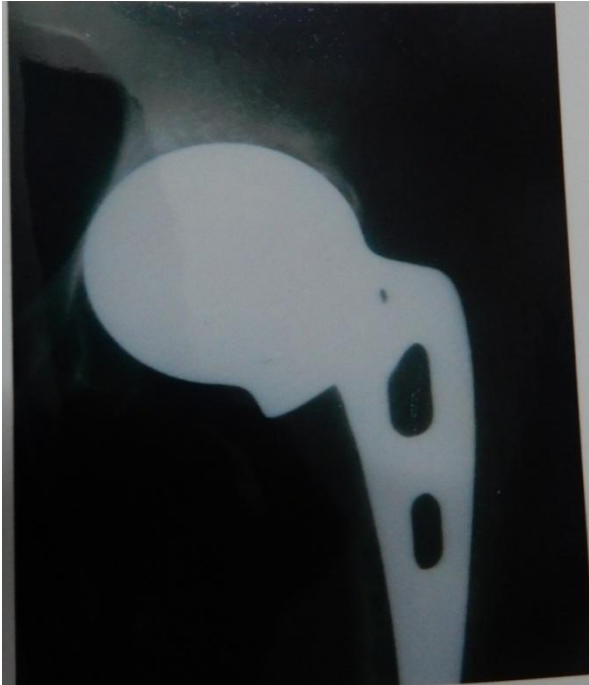

**1 YEAR FOLLOW UP XRAYS AND FUNTIONAL PICTURES**

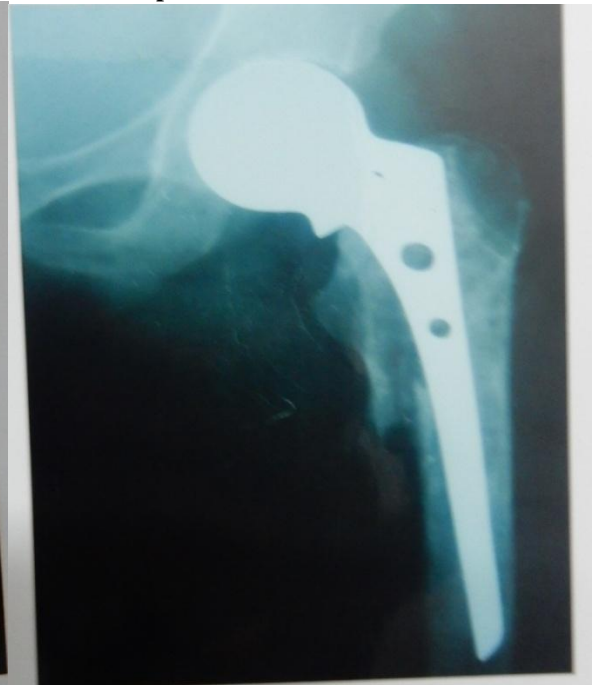

### COMPLCATION OF OSTEOSYNTHESIS AND HEMIARTHOPLASTY

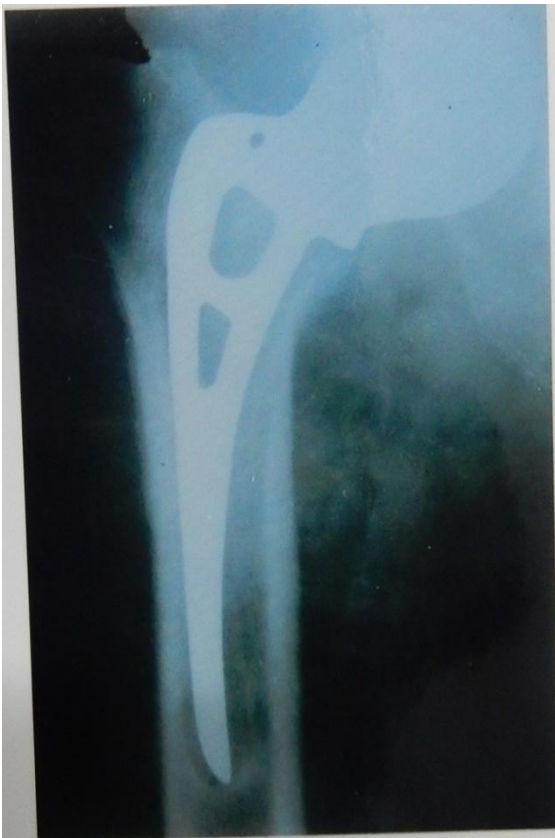Acetabular Erosion



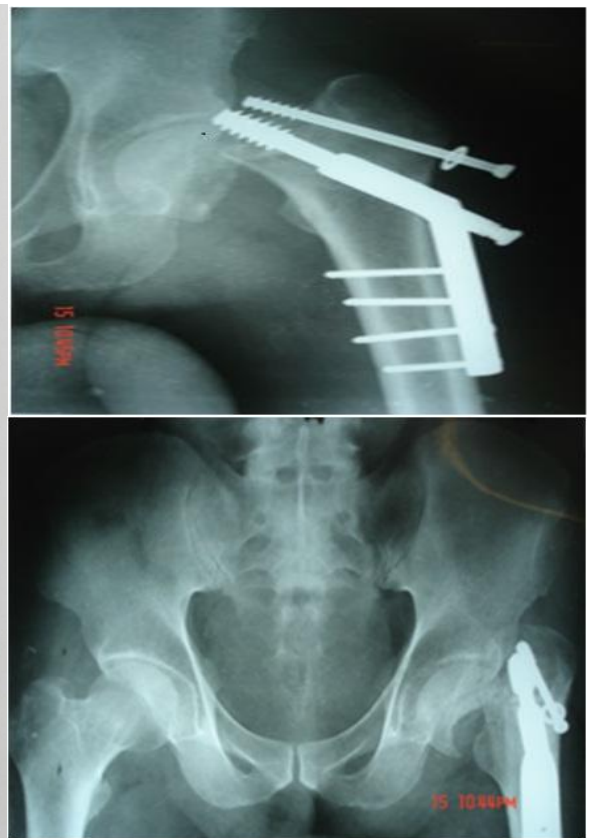
Periprosthetic Fracture



LOSSENING OF STEM



IMPLANT CUT OUT



## DISCUSSION

Osteosynthesis; however seems to have regained popularity as reported by Bohler J. (1978) and Vanlingen (1981). "The choice of treatment presents no heart searching problem to those who are satisfied that primary prosthetic replacement is the only way to deal with subcapital fractures; nor does it disturb those who believe that internal fixation is the operation of choice"<sup>7</sup>. Nevertheless, the struggle to find the best treatment in relatively younger patient continues as it did in yesteryears. One of the study objectives was to determine if Osteosynthesis or Endoprosthesis replacement should be the treatment of choice, in active elderly people with even unstable fractures.

In case of displaced femoral neck fractures, it is fracture healing and revascularization of the femoral head fragment that provides the stability of an osteosynthesis of the femoral neck<sup>8</sup>. DHS with additional lag screw as compared to other method of Osteosynthesis procedures, guarantee the ability to withstand stress, comply better with dynamic principle and ensure rotational stability of the femoral head fragment. Efforts were focused on saving the femoral head in active elderly patients.

Overall, the average age of the patients was 62.5 years. 61% of the total patients were between 55 to 65 years of age group. The mean age of the patient in internal fixation group was 59 years and that of Hemiarthroplasty group was 66years, which is lower than reported by A.B. Van Vugt et al<sup>9</sup>. In their study the mean age in internal fixation group was 75.3years and in Hemiarthroplasty group it was 76 years. There were seven women (22.5%) internal fixation group and seven women (46.6%) in Hemiarthroplasty group, which is much lower than reported by Rogmak C etal<sup>10</sup> with 78% in internal fixation group and 80% in Arthroplasty group.

According to anatomical classifications, the incidence of subcapital type of fracture is 76.32% (35 cases), basal type is 15.2% (7 cases) and transcervical type is 8.69% (4 cases). George J. etal reported transcervical to be the most common type of fracture in a series of 73 patients<sup>17</sup>. As per Garden's classification, in internal fixation group Stable type fracture (Garden's grade I & II) is found to be 36% and unstable fracture (Garden's grade III & IV) is found to be 64%, whereas in Hemiarthroplasty group all patients were garden's grade IV. Majority of the fractures were caused by trivial trauma like slipping over floor or by low intensity strain. This is the most common cause of fracture in elderly patients<sup>10</sup>.

The maximum number of cases operated in internal fixation group were within a week (trauma – surgery interval) and average period of hospital stay was 18 days while in Hemiarthroplasty group it was more than 3 weeks (trauma-surgery Interval) and 27 days respectively; which was significantly shorter in

internal fixation group similar to the study reported by Rogmark C etal<sup>1</sup>.

Common size of implants used in internal fixation group was 135 degree Richard's compression plate short barrel with 2 holes; DHS of size 85 mm and cancellous screw size was 80 mm. Common size of prosthesis used in Hemiarthroplasty group was 43mm, which is smaller than used in Langen (1978) Series. This could be due to comparatively smaller structure frame of Indian population.

**Complications:** There was no intra-operative complication in internal fixation group while in Hemiarthroplasty group, 1 (6.6%) case of unicortical fracture of shaft femur occurred during reduction and weight bearing was delayed for 6 weeks in these cases. Immediate post operative complications in internal fixation group was failure of reduction in 1 case (3.2 %) which was later on converted to Hemiarthroplasty; while in Hemiarthroplasty group, 1 patient (6.6%) had dislocation of hip while shifting the patient post-operatively, which was again closely reduced and limb was immobilized over Thomas splint in abduction and external rotation. In this patient, also weight bearing was delayed for 4 weeks. David Oliver etal reported 4% cases of dislocation in Hemiarthroplasty Series<sup>14</sup>. Ahmed Kaabneh etal reported fracture only in 1% of cases<sup>12</sup>.

We have found only 2 patients (6.45%) of operative wound infection (superficial) in internal fixation group. Both of them completely healed after daily dressing and antibiotic coverage. In Hemiarthroplasty group we found 5 patients (33%) of operative wound infection (3 cases of superficial infection and 2 cases of deep infection). Superficial infection healed completely but the deeper one took longer period to heal and surgery (debridement) was done. M. J. Parker etal in their Cochrane database of systemic reviews, stated that risk of deep wound infection were significantly less for internal fixation as compared with arthroplasty<sup>11</sup>.

Postoperative pain was more in Hemiarthroplasty group as compared to internal fixation group because of more soft tissue dissection; which is similar to the study reported by Ahmed Kaabneh etal<sup>12</sup>. Delayed complications in Hemiarthroplasty group- Acetabular erosion occurred in one case (6.6%), stem loosening in 2 cases (13%) and shortening of the limb in 4 cases (26.6%). JT Johnson etal in their study group of 239 patient, reported acetabular erosion in 2% cases<sup>15</sup>. David Oliver, Richard Griffith et al reported 5% of cases of loosening of prosthesis in a study group of 674 patients<sup>14</sup>. In internal fixation group, we found -DHS cutout in 2 cases (6.4%), which were later on converted to Hemiarthroplasty. Ahmedkaabneh et al<sup>12</sup>



reported DHS cutout in 3% of cases. In our study, there were more cases (4 versus 0 case) of limb shortening in Hemiarthroplasty group, which was more in internal fixation group as reported by M.J. Parker et al<sup>13</sup>. Higher percentage of complications in the present study is probably because of smaller number of cases in the Hemiarthroplasty group.

Overall results of functional outcome by Oxford Hip Score (OHS) is satisfactory (excellent and good) for internal fixation group is 77% and for Hemiarthroplasty is 66%. JNS Davison et al<sup>16</sup> reported no difference by OHS between Sliding hip screw, cemented Thompson Hemiarthroplasty and cemented monk bipolar Hemiarthroplasty. They also reported the more important outcome of mortality and final function of the limb however favors internal fixation.

M. Masson et al<sup>2</sup> concluded although either fixation of the bone or replacement with an artificial hip may be used for specific fracture of the thigh bone near the hip joint, both procedures have their own inherent complications.

## CONCLUSION

From this study it is concluded that DHS with supplementary cancellous screw fixation with early weight bearing gives good result in intracapsular hip fracture in active elderly patient, provided done with meticulous technical skill even in displaced type (Garden grade III & IV). Thus saving the head by Osteosynthesis has less complication rate like pain, infection, fracture of shaft of femur, shortening and mortality than Hemiarthroplasty. However, the reoperation rate is more in Osteosynthesis group mainly because of shorter length of follow up.

The overall outcome assessment including the complications, the status of activity of daily living (ADL) and hip function according to Oxford Hip Score (OHS) is better in Osteosynthesis group. Thus we conclude that osteosynthesis is justified as a primary treatment of intracapsular hip fracture even in displaced type in active elderly patient aged 55-65 years and in good physical condition. Endoprosthesis replacement should be used in cases where neck is absorbed, in failed Osteosynthesis, Non-union or where the physical activity of the patient has been limited in pre- fracture period.

**Limitations:** more number of cases with at least average follow up of 3-5 years is required for final assessment considering commonly encountered complication like avascular necrosis and non-union.

**Conflict of Interest:** None

**Acknowledgement:** None

## ABBREVIATIONS

AP- Anterior to posterior

OHS- Oxford hip score

## REFERENCES

1. Rogmark C, Carlsson A, Johnell O, Sernbo I: A prospective randomised trial of internal fixation versus arthroplasty for displaced fractures of the neck of the femur. *J Bone Joint Surg Br.* 2002 Mar; 84(2):183-8.
2. Masson M, Parker MJ, Fleischer S, Internal fixation versus arthroplasty for intracapsular proximal femoral fractures in adults: *Cochrane Database Syst Rev.* 2003;(2):CD001708.
3. Garden R.S., Preston, Stability and union in subcapital fractures of the femur: *J Bone Joint Surg Br.* 1964 Nov; 46:630-47.
4. Keating JF, Grant A, Masson M, Scott NW, Forbes JF, Randomized comparison of reduction and fixation, bipolar hemiarthroplasty, and total hip arthroplasty. Treatment of displaced intracapsular hip fractures in healthy older patients: *J Bone Joint Surg Am.* 2006 Feb; 88 (2):249-60.
5. Lee KB, Howe TS, Chang HC, Cancellous screw fixation for femoral neck fractures: one hundred and sixteen patients: *Ann Acad Med Singapore.* 2004 Mar; 33 (2):248-51
6. Healy WL, Lorio R: Total hip arthroplasty: optimal treatment for displaced femoral neck fractures in elderly patients. *Clin Orthop Relat Res.* 2004 Dec ;( 429):43-8.
7. R. S. Garden, *Injury* 1977, vol9, 5-7 : Selective surgery in medial fractures of the femoral neck: a review .
8. F.A. Bonnaire, A.T. Weber:-Analysis of fracture gap changes, dynamic and static stability of different osteosynthetic procedures in the femoral neck: *Injury* December 2002, Vol 33, supp 3, page 24-32.
9. A. B. Van Vugt, W. M. Oosterwijk, R. J. A Goris: Osteosynthesis versus endoprosthesis in the treatment of unstable intracapsular hip fractures in the elderly. *Archives of Orthopaedic and Trauma Surgery (Impact Factor: 1.31).* 12/1993; 113(1):39-45.
10. Christodoulou NA, Dretakis EK. Significance of muscular disturbances in the localization of fractures of the proximal femur. *Clin Orthop Relat Res.* 1984;187:215-7. [PubMed]
11. Parker MJ, Livingstone V, Clifton R, McKee A: Closed suction surgical wound drainage after orthopaedic surgery. *Cochrane Database Syst Rev.* 2007 Jul 18;(3):CD001825.
12. A Kaabneh, J Jeffery. *Is Outpatient Follow-up for Fractured Neck of Femur Necessary?* The Internet Journal of Orthopedic Surgery; 2006: Vol. 4, No. 2.
13. Parker MJ, Khan RJ, Crawford J, Pryor GA: Hemiarthroplasty versus internal fixation for displaced intracapsular hip fractures in the elderly. A randomized trial of 455 patients' 2002 Nov; 84(8):1150-5.
14. David Oliver, Richard Griffith David Oliver, Richard Griffiths, James Roche, Specialist Registrar, and Opinder Sahota, Hip fracture, *BMJ Clin Evid.* 2010; 2010: 1110
15. Johnson JT, Crothers ON: Nailing versus prosthesis for femoral-neck fractures: A critical review of long-term results in two hundred and thirty-nine consecutive private patients; *JBJS Am.* 1975 Jul; 57(5):686-92.
16. J. N. S. Davison, S. J. Calder, G. H. Anderson, G. Ward, C. Jagger, W. M. Harper, P. J. Gregg; Treatment

- for displaced intracapsular fracture of the proximal femur A PROSPECTIVE, RANDOMISED TRIAL IN PATIENTS AGED 65 TO 79 YEARS, *J Bone Joint Surg [Br]* 2001;83-B:206-12.
- 17 George J. Haidukewych, Walter S. Rothwell, David J. Jacofsky, Michael E. Torchia, and Daniel J. Berry ,Operative Treatment of Femoral Neck Fractures in Patients Between the Ages of Fifteen and Fifty Years *J Bone Joint Surg Am* Volume 86(8):1711-1716 August 1, 2004.
- 18 Leadbetter GW: A treatment for fracture of the neck of the femur. Reprinted from *J Bone Joint Surg* 20:108-113, 1938; *ClinOrthopRelat Res.* 2002 Jun ;(399):4-8.
- 19 Dickson J. A.: The unsolved fracture, a protest against defeatism. *J.B.J.S. Am*, 1953; 35-A(4): 805-22
- 20 Lausten GS, Vedel P, Nielsen PM: Fractures of the femoral neck treated with a bipolar endoprosthesis. *ClinOrthopRelat Res.* 1987 May; (218):63-7.
- 21 Thierry Pauyo, Justin Drager, Anthony Albers, and Edward J Harvey: Management of femoral neck fractures in the young patient: A critical analysis review; *World J Orthop.* 2014 Jul 18; 5(3): 204–217.
- 22 RAU, FREDERICK D. M.D.; MANOLI, ARTHUR II, M.D.; MORAWA, LAWRENCE G. M.D.: Treatment of Femoral Neck Fractures With the Sliding Compression Screw; *Clinical Orthopaedics& Related Research*:March 1982 - Volume 163 - Issue - ppg 137-140.