

“Treatment of Comminuted Unstable Inter-Trochanteric Fracture in Elderly Patients with Cemented Bipolar Prosthesis”

Choudhari Pradeep^{1,*}, Agrawal Anuj², Gurjar Abhishek³

¹Professor and Unit Head, ²Asst. Professor, ³Postgraduate Resident,
Department of Orthopaedics & Traumatology,
Sri Aurobindo Institute of Medical College & Post Graduate Institute Indore, M.P.

***Corresponding Author:**

Email: pchoudhari@rediffmail.com

ABSTRACT

Introduction: Unstable intertrochanteric fractures in osteoporotic bones are difficult to treat. Conservative treatment with traction and prolonged immobilization lands up with many complications and often fatality. Rate of failure in internal fixation, with dynamic hip screws or intramedullary nail has been found high, especially in osteoporotic bones. The weak and porotic bone tolerates screws poorly so cut out is the major problem in internal fixation. The aim of this study was to assess the efficacy of cemented hemiarthroplasty in the management of proximal femoral fractures in elderly patients with severe osteoporosis.

Material and Methods: 25 patients (11 males and 14 females) above 65 years of age with unstable intertrochanteric fractures who underwent bipolar arthroplasty were prospectively evaluated. Trans-trochanteric approach was used in all patients. Greater trochanter encirclage was done in all patients. Harris hip score was used for the clinical evaluation. The minimum follow up period was one year.

Results: In our study 25 cases were taken, which had a mean age 73.44 ± 7.11 years. The mean Harris hip score at one year was 80.54 ± 19.74 . Excellent to good results were obtained at one year in 17(68%) cases and fair in 4 (16%) cases, poor in 2 (8%). Death of two patients occurs due to age related factors. Mean hospital stay was 14.24 ± 10.46 days. There was one case of superficial infection and one case of dislocation which were managed conservatively. Mean hospital stay was 14.24 ± 10.46 . Radiological follow-up showed no case with loosening of the prosthesis, break in the cement or sinking of the prosthesis.

Conclusion: Cemented bipolar hemiarthroplasty through trans-trochanteric approach give good result in a majority of elderly patient with unstable intertrochanteric fracture. It has advantage of an early ambulation and less hospital stay, as compared to the internal fixation. Also, the patient rehabilitation is easy and fast and none of the patient required any revision surgery. But the follow up period in our study is not enough to make any clinical recommendations though it can serve as a critical analysis to stimulate future research. Further long term studies are required.

Access this article online	
Quick Response Code:	Website: www.innovativepublication.com
	DOI: 10.5958/2395-1362.2015.00038.9

INTRODUCTION

Intertrochanteric fractures have been recognized since the time of Hippocrates and are a common problem in the older age. Aitken suggested that degree of osteoporosis in fracture influences fracture type¹. Gallagher et al suggested that, with increase in the life expectancy, the incidence of Intertrochanteric fractures has sharply risen among the geriatric population².

Traditionally trochanteric fractures are treated by open reduction & internal fixation without considering significance of fracture type, age of the patient or associated co-morbidities. Standard internal fixation devices used in elderly patients with trochanteric fractures, have a high rate of complications as Baumgaertner et al found 20% of implant failure in trochanteric fractures³. Barrios C et

al suggested that independent of the type of implant, patients with unstable trochanteric fractures with osteoporosis were at high risk of implant failure⁴. The weak and porotic bone tolerates screws poorly so cut out is the major problem in internal fixation⁵. Many a times patient spends a long time in bed, following standard internal fixation, which complicates the recovery. Complications like deep vein thrombosis (20%) & hypostatic pneumonia (19.4%) are high⁷. Hip fractures are associated with high mortality among elderly after internal fixation that is 15-20 % in first 3-6 month & 30% at 12 month⁸. Percentage of patients requiring a second operation is 30-40%⁹.

Bipolar hemiarthroplasty offers a durable and versatile solution for trochanteric fractures in the elderly. It can be done as a primary procedure or secondary to failure of conservative or operative treatment, offering an advantage of rapid return of function with a pain free stable hip with 4-5% need for revision surgery as compare to 30-40% with traditional internal fixation⁹.

MATERIAL AND METHODS

25 patients underwent cemented bipolar hemiarthroplasty between July 2013 to March 2015 who had sustained comminuted inter-

trochanteric fractures in osteoporotic bones. All patients who were operated by primary author by trans trochanteric approach. We selected this approach as in all our cases greater trochanter and lateral wall was fractured so in all cases femoral head was approached through the fracture site. We had kept certain inclusion and exclusion criteria for our study, Both sexes of age- More than 65 years, those classified as AO/OTA type 31- A2.2 and 2.3 of Inter-trochanteric Fractures, no concomitant fracture or other injury in the ipsilateral limb, no head injury or other injury and excluded the patient with any trans cervical, sub capital, basic cervical or sub trochanteric fractures, stable inter trochanteric fractures, associated or the previous fracture at same site, those with adjacent long bone fracture, associated vascular injury and patient less than 65 yrs of age

Surgical Procedure

All surgeries were performed using standard aseptic precautions. Surgeries were performed under hypotensive epidural anesthesia. Intravenous antibiotic were given 1 hr. prior to surgery. Position of the patient & draping. Straight lateral position with the patient lying on the unaffected side. Lateral skin incision: With hip in 20-30 degree flexion, straight incision was taken centered over greater trochanter. Hip joint was exposed with Harding's approach. Fractured femoral head with neck was extracted by flexion & external rotation at hip joint, preserving the greater & lesser trochanter attached to the soft tissues. Head size measured. We prepared femoral medullary canal by sequential broaches in flexed & externally rotated hip. Trial implants were placed & hip was reduced to decide the final implants sizes. After removing the trial implants thorough wash given with pulse lavage. Cement restrictor was placed in the medullary canal 2 centimeters below the tip of femoral stem. Canal was dried using hydrogen peroxide soaked roller gauze. Cementing was done with cement gun. Placement of femoral stem was done. Hip joint was reduced & closure done in layers using negative suction drains.

Rehabilitation

All the patients operated, were started with physiotherapy. All patients were trained for quadriceps strengthening exercises immediately. Full weight bearing walking was started from post-op day

1 with the help of walker for first 6 weeks post-operative. Thereafter patients started full weight bearing with support of a stick. Patients were instructed to avoid activities involving squatting and cross legged sitting for the rest of their life as a precautionary measure to avoid dislocation of the bipolar hemiarthroplasty. Patients were followed up regularly at 6 weeks, 12 weeks, 6 months and one year post-operatively.

RESULTS

Statistical Analysis was done by the Mini Tab version 17. Patients were evaluated, 3 months post-operatively and then at final follow up using Harris Hip score¹⁰. We had 25 patients included in our study with 14 female and 11 male patients. 98 % patients had suffered the injury due to trivial trauma like fall from chair/bed, slip in bathroom or in house on floor. Rest 2 % of patients had suffered from major trauma like fall from significant height, road traffic accident or fall from stairs.

Table1: shows that we had total of 25 patients with mean age of 78 years. Our mean operative time was 61.35 minutes with mean blood loss of 67.48 ml. We had operated all the patients within first two weeks of trauma with mean time between injury and operation being 3.5 days. All the patients were mobilized immediately on next day of surgery so the recovery and rehabilitation was quick with mean post-operative stay in hospital being 14.24 days. Mean Harris hip score at 3 months follow up and final follow -up showed significant improvement from pre-op mean of 13.28 to that of 73.37 and 80.54 respectively. Of 25 patients we had 24 % patients with excellent Harris hip score, 44% patients with good Harris hip score, 16% patients had fair and 8% patients had poor scores.

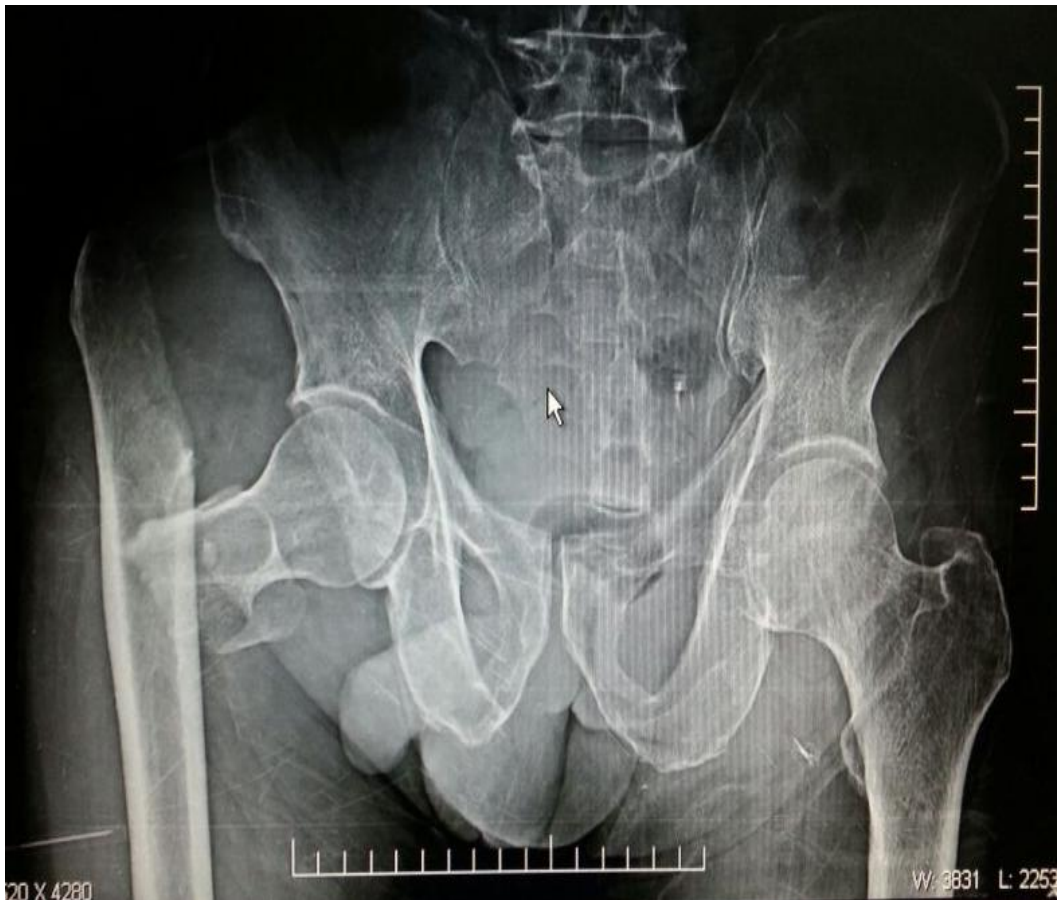Table2: Show that postoperatively 3 patients had shortening of the operated limb of which 2 had less than 2 centimeters, so they were given a heel raise. They walked with the help of a cane. 1 patient had shortening more than 2cm: he had a slight limp and used support of quadruple walker while walking. One patient had infection and one patient had dislocation both where managed conservatively. One patient had non union of greater trochanter which was left alone as she was neither symptomatic nor willing for revision surgery.

Table1: Demographic variables among the 25 cases

	Mean	Min	Max
AGE (YEARS)	73.44 ± 7.11yrs	65 yrs	90 yrs
HARRIS HIP SCORE:3 months	73.37	51	84
HARRIS HIP SCORE: FINAL FOLLOW UP	80.54	59	92
BLOOD LOSS (ML) OPERATIVE TIME (MIN)	67.48 ± 46.25 ml	30ml	250ml
STAY IN HOSPITAL POST-OP (DAYS)	14.24 ± 10.46 days	1-5 days	More than 15 days
Operative time	63.00 ± 19.14	45 min	140min

Table2: Post operative complications among 25 patient

	IMMEDIATE	Delayed	Measure taken
INFECTION	1	None	Conservatively
SHORTENING	3	-----	2 patients had shortening less than 2 cm so heel raise, 1 patient had shortening more than 2 cm so shoe platform with quadruple walking stick while walking.
DISLOCATION	-----	1	Conservatively
NON UNION OF GREATER TROCHANTER		1	The patient was left alone as she was neither symptomatic nor willing for revision surgery.

**Fig. 1**

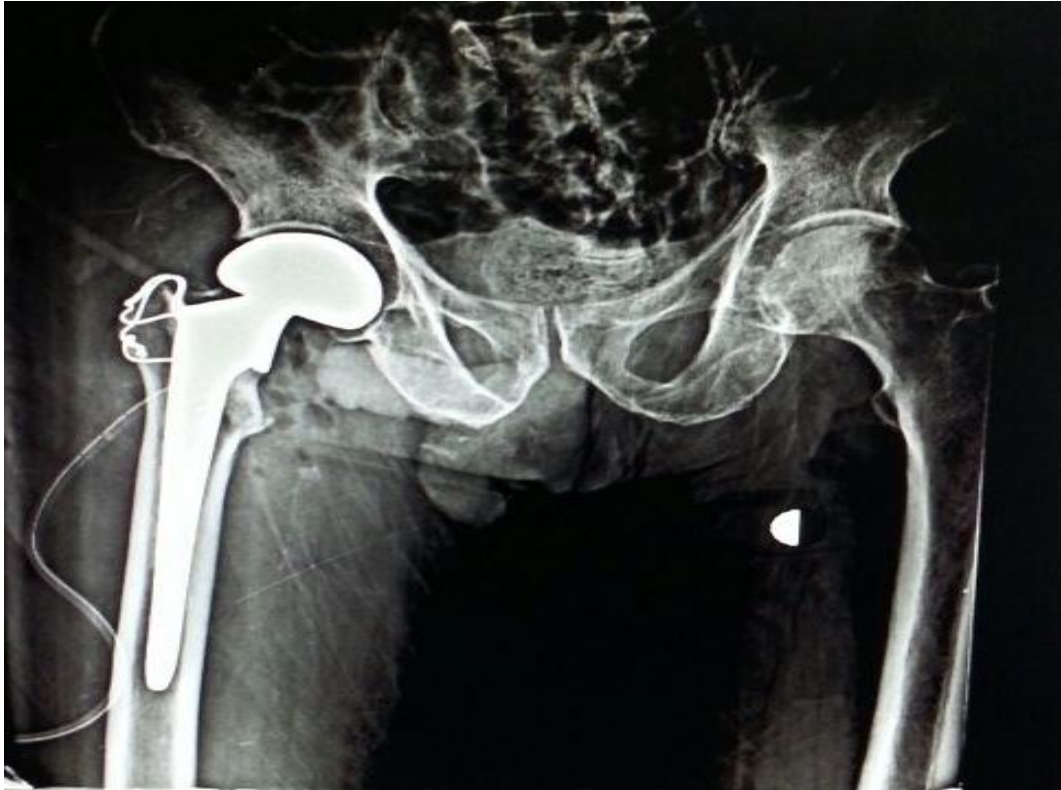


Fig. 2

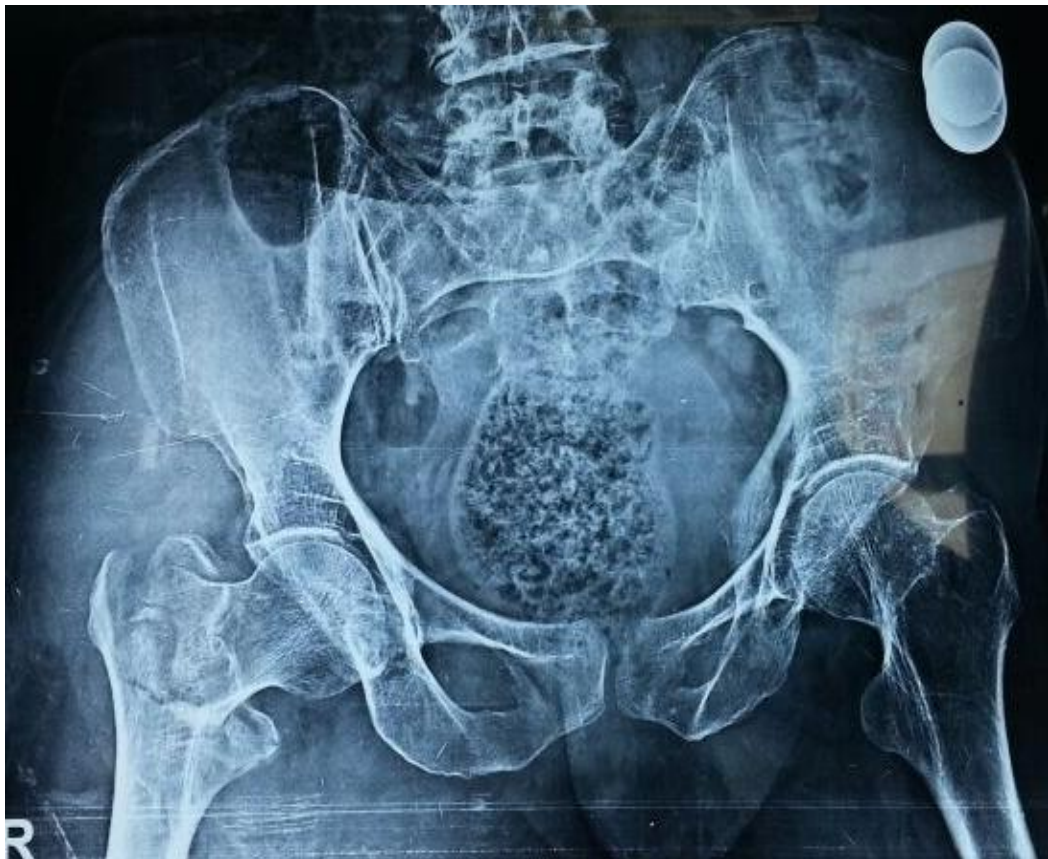

Fig. 3

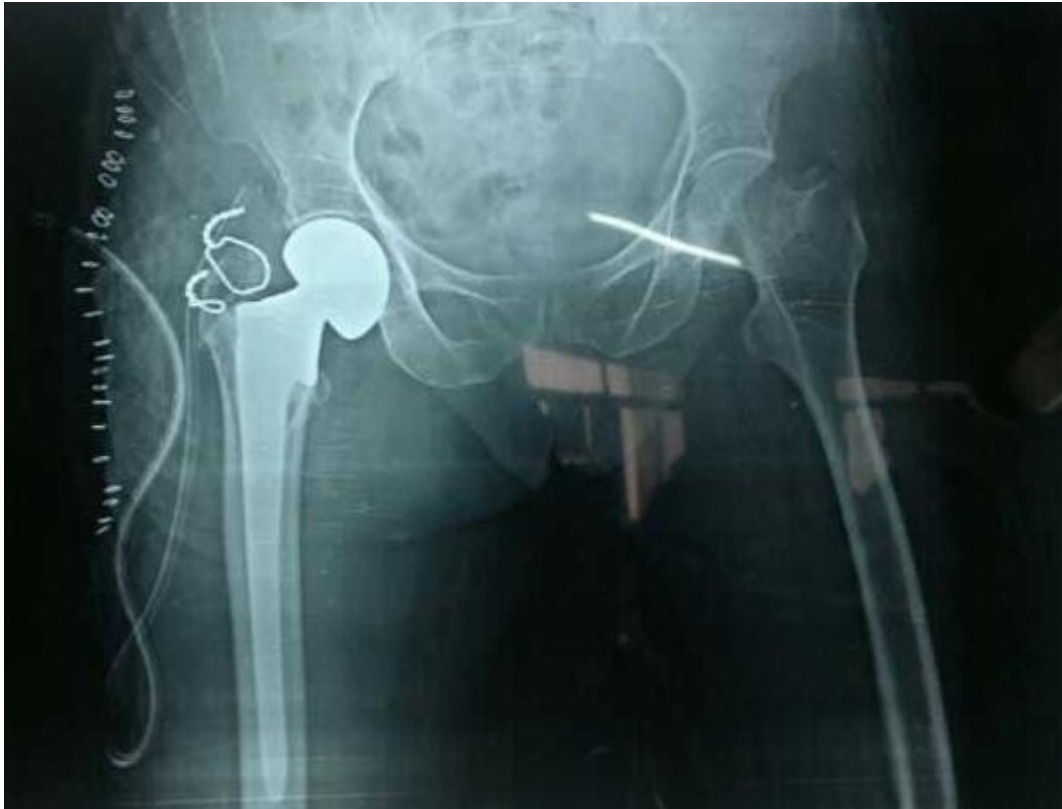

Fig. 4

DISCUSSION

Hip fractures are the most common cause of morbidity and mortality¹¹. Internal fixation has drastically reduced the mortality associated with intertrochanteric fractures;¹² however, early mobilization is still avoided in cases with comminution, osteoporosis, or poor screw fixation.^{13,14} Primary hemiarthroplasty offers a modality of treatment that provides adequate fixation and early mobilization in these patients thus preventing postoperative complications such as pressure sores, pneumonia, atelectasis, and many other.¹⁵

The earliest comparison of internal fixation and hemiarthroplasty was done by Haentjens et al. showing a significant reduction in the incidence of pneumonia and pressure sores in those undergoing prosthetic replacement.¹⁶ Hemiarthroplasty patients were allowed full weight bearing significantly earlier than the internal fixation patients. The Indian perspective regarding the use of primary arthroplasty as a modality of treatment for severe comminuted unstable intertrochanteric fractures is being commented on by few authors,^{17,18} our study also show that there were no such case of bed ridden complications. In our study postoperatively 3 patients had shortening of the operated limb of which 2 had less than 2 centimeters, so they were given a heel raise. They walked with the help of a cane. 1 patient had shortening more than 2cm: he had a slight limp

and used support of quadruple walker while walking. In comminuted intertrochanteric femur fracture, it is difficult to measure exact length so minor shortening can be a complication. There is no faulty technique or cement subsidence.

Conflicting reports about postoperative mortality in cases with primary hemiarthroplasty are cited in the literature. Kesmezacare *et al.*¹⁹ reported postoperative mortality in 34.2% after a mean of 13 months and in 48.8% after a mean of 6 months in patients treated with internal fixation and endoprosthesis, respectively. Other studies have shown no differences in postoperative mortality in two groups.^{20,21} In our study only 2 patients out of the 25 died (8%) within 6 months of surgery due to unrelated causes .

Rodop et al.²² in a study of primary bipolar hemiarthroplasty for unstable intertrochanteric fractures in 37 elderly patients obtained 17 excellent (45%) and 14 good (37%) results after 12 months according to the Harris hip-scoring system. A total of 18 out of 23 patients in our study had a good to excellent result (71%). If the patients with a fair result were also included, the percentage goes up to 91%. Thus the results of this modality of treatment are definitely promising.

CONCLUSION

Cemented bipolar hemiarthroplasty through trans-trochanteric approach give good result in a majority of elderly patient with unstable intertrochanteric fracture. It has advantage of an early ambulation and less hospital stay, as compared to the internal fixation. Also, the patient rehabilitation is easy and fast and none of the patient required any revision surgery. But the follow up period in our study is not enough to make any clinical recommendations though it can serve as a critical analysis to stimulate future research. Further long term studies are required.

BIBLIOGRAPHY

1. Aitkin JM. Relevance of osteoporosis in women with fracture of the femoral neck. *Br Med J* 1984;288:597-601.
2. Gallagber JC, Melton LJ, Riggs BL, et al. epidemiology of fracture of proximal femur in Rochester Minnesota. *Clinical orthopadics & Related Research* 1980;150:163-171.
3. Baumgae MR, Solberg BD et al implant failure in patient with proximal fracture of the femur treated with sliding screw device. *J bone joint surg Br.*1997;79:969-971.
4. Barrio l.A Brostrom A Stark et al healing complication after internal fixation of trochanteric hip fractures the prognostic value of osteoporosis *J Orthop Trauma* , Volume 7 , Issue 5 1993, p.438.
5. Irfan Sultan Sheikh. Intertrochanteric femur fracture in elderly treated with bipolar vs dhs – A prospective study- *Journal of Medical Thesis*, Volume 2, Issue 2, May-Aug 2014, Page 45-49.
6. Parker MJ & AL-Rashid M. Anticoagulation management in hip fracture patient on warfarin. *Injury* 2005 nov,36(11): 1311-5.
7. Rae pj, Hodgkinson jp, Maedows TH, davies DRA hargadon EJ. Treatment of displaced subcapital fractures with the charnley- hastings hemiarthroplasty. *J Bone joint surg (B)* 1989; vol 71-B, no.3, may 1989:478-482.
8. Christopher G. Moran Russell T Wenn, Manoj Sikand & Andrew M Taylor. Early mortality after hip fracture: Is delay before surgery important? *J Bone & Joint Surg (Am)*. 2005;87:483-489.
9. Keating JF, Grant A, Masson M, Scott NW, Forbes JF. Randomized comparison of reduction & fixation, Bipolar Hemiarthroplasty, & Total Hip Arthroplasty. *J Bone & Joint Surg (Am)* 2003 feb 88 (2) 249-60.
10. Campbell's operative orthopaedics, Editor S. Terry Canale MD. Tenth Edition.
11. Before 1930, treatment of intertrochanteric fracture was basically conservative, i.e. Russell's traction, skeletal traction, counterpoised suspension and well leg traction.
12. White BL, Fisher WD, Laurin CA. Rate of mortality for elderly patients after fracture of the hip in the 1980's. *J Bone Joint Surg Am.* 1987;69:1335-40.
13. Wolfgang GL, Bryant MH, O'Neill JP. Treatment of intertrochanteric fracture of the femur using sliding screw plate fixation. *Clin Orthop Relat Res.* 1982;163:148-58.
14. Sernbo I, Johnell O, Gentz CF, Nilsson JA. Unstable intertrochanteric fractures of the hip: Treatment with Ender pins compared with a compression hip-screw. *J Bone Joint Surg Am.* 1988;70:1297-303.
15. Haentjens P, Casteleyn PP, Opdecam P. The Vidal-Goalard megaprosthesis: An alternative to conventional techniques in selected cases? *Acta Orthop Belg.* 1985;51:221-34.
16. Haentjens P, Casteleyn PP, De Boeck H, Handelberg F, Opdecam P. Treatment of unstable intertrochanteric and subtrochanteric fractures in elderly patients. Primary bipolar arthroplasty compared with internal fixation. *J Bone Joint Surg Am* 1989;71:1214-25.
17. Stern MB, Goldstein TB. The use of the Leinbach prosthesis in intertrochantric fractures of the hip. *Clin Orthop Relat Res.* 1977;128:325-31.
18. Rosenfeld RT, Schwartz DR, Alter AH. Prosthetic replacements for trochantric fractures of the femur. *J Bone Joint Surg Am.* 1973;55:420.
19. Kesmezacar H, Ogut T, Bilgili MG, Gokay S, Tenekecioglu Y. Treatment of intertrochanteric femur fractures in elderly patients: internal fixation or hemiarthroplasty. *Acta Orthop Traumatol Turc.* 2005;39:287-94.
20. Haentjens P, Casteleyn PP, De Boeck H, Handelberg F, Opdecam P. Treatment of unstable intertrochanteric and subtrochanteric fractures in elderly patients. Primary bipolar arthroplasty compared with internal fixation. *J Bone Joint Surg Am.* 1989;71:1214-25.
21. Stappaerts KH, Deldycke J, Broos PL, Staes FF, Rommens PM, Claes P. Treatment of unstable peritrochanteric fractures in elderly patients with a compression hip screw or with the Vandeputte (VDP) endoprosthesis: A prospective randomized study. *J Orthop Trauma.* 1995;9:292-7.
22. Rodop O, Kiral A, Kaplan H, Akmaz I. Primary bipolar hemiprosthesis for unstable intertrochanteric fractures. *Int Orthop* 2002;26:233-7.