

Femoral Neck fracture in young patients, managed by osteosynthesis using Primary double angle barrel plate combined with valgus intertrochanteric osteotomy- Long term result

SPS Gill^{1,*}, Dinesh Kumar², Manish Raj³, Pulkesh Singh⁴, Jasveer Singh⁵, Rakesh Vishwakarma⁶

¹Associate Professor and HOD, ^{2,4,5}Assistant Professor, ²Lecturer⁶JR, Department of Orthopaedics, UP Rural Institute of Medical Science and Research, Saifai, Etawah, Uttar Pradesh, India

***Corresponding Author:**

E-mail: simmygill@gmail.com

ABSTRACT

Introduction: Femoral neck fracture at any age always shows relatively higher rate of complications like non union, avascular Necrosis of femoral head, loss of fixation, screw cut-out and delayed secondary osteoarthritis. These fractures in physiologically old age are managed by replacement of femoral head. In Femoral neck fractures in young adult the main aim is to preserve the natural head and these cases are managed by Multiple cancellous screw, Cannulated Cancellous Screw (CCS) with fibular graft either free fibular or vascularised fibular graft. Replacement surgeries in these cases are a difficult choice as young age and also high cost of implants. Also in these patients it is difficult to restrict squatting for lifelong due to social culture and lack of toilets. Now days also preferences are given to head sparing surgeries and osteosynthesis. We use primary double angle barrel plate with intertrochanteric valgus osteotomy for the management of femoral neck fracture in young adults.

Material and method: Cases were selected from the patients attending in Orthopaedics OPD and emergency trauma centre of UPRIMS & R, Saifai, Etawah from May 2006 to August 2013. During this period total 44 cases of fracture neck femur were selected for primary fixation with double Angle Barrel Plate (DABP). Out of 44 cases 30 were female and 14 were male with age range from 18 yrs to 48 yrs and average age of 42 yrs. Average duration from injury to operative procedure was 1.3 weeks (10 Days) and range from 2 days to 15 weeks. These cases were operated by Double angle barrel plate with intertrochanteric valgus osteotomy and long term result evaluated using Modified Askin and Bryan criteria

Result: Out of 44 cases operated 42 cases followed up to the average duration of 48 months and all these 42 cases show good (18) to Excellent (20) results after 4 yrs according to Harris hip score. 4 cases shows fair result and other secondary procedure were required in these cases. Complication seen during follow up were avascular necrosis in 7 cases and out of these 7, 4 cases given poor result as these were also shown loosening of fixation and crew cut out. Out of 42 cases 38 cases were able to perform squatting after 4 yrs of follow up and also there were no radiological sign AVN of head at all. Loss of reduction and screw cut out seen in two cases and these were in poor outcome group.

Discussion: Fracture neck femurs are not rare presentation in developing countries. Various modalities of treatment are fibular graft, ileac bone graft, multiple screws with fibular graft, muscle pedicle graft. We in our series done primary osteotomy combined with double angle barrel plate (DABP) achieved excellent to good results in 90% cases. Primary osteotomy with double angle barrel plate is a good alternative for the management of femoral neck fracture in young patients.

Access this article online	
Quick Response Code:	Website: www.innovativepublication.com
	DOI: 10.5958/2395-1362.2015.00040.7

INTRODUCTION

Femoral neck fractures in all age group are difficult to manage due to higher rate of complications. Fracture neck of femur in young adult have relatively higher incidence of complications like non union¹, avascular Necrosis (AVN) of femoral head², loss of fixation, screw cut-out and delayed secondary osteoarthritis³. In India any injury around hip in rural area tends to be managed by local bone setters using local massage and manipulation. These massage and manipulation of injury around hip area have relatively less adverse effect on inter-

trochanteric fracture but adversely affects the final outcome of the intra-capsular fracture of femur. These manipulations often leads to loss of neck stock and smoothening of fracture margin, decrease in size of proximal fragment and osteonecrosis⁴. Situations like this in young adult leads to difficulty in fixation by simple cancellous screw because of lack of compression surface area and short proximal segment. Replacement surgeries^{5,6,7} in these cases are a difficult choice as these patients are generally of low socio economical status and also in these patients it is difficult to restrict squatting for lifelong due to social-culture habits. Fresh fracture of femoral neck in young adults are generally managed by osteosynthesis using cancellous screws alone, Cannulated Cancellous Screw (CCS) with fibular graft, DHS with derotation screw in basal neck fractures. Now days also preferences are given to head sparing surgeries and osteosynthesis.

At our medical institute we managed these cases by primary trochanteric osteotomy and fixation

the fracture and osteotomy site by double angle barrel plate(DABP). Operative procedure is modified for better fixation and less soft tissue damage. Collapse femoral head with any previous history of hip disease and arthritic hip cases were not included for osteosynthesis.

MATERIAL AND METHOD

This study was conducted in the Department of Orthopaedics of UPRIMS & R, Saifai, Etawah a 1000 bedded Multispecialtytertiarylevel Medical collage situated in rural setup in North India. These cases were selected from the patients attending ourOrthopaedics OPD and emergency trauma centre from May 2006 to August 2013. During this period total 48 cases of fracture neck femur came to our department. Out of these 48 cases 44 cases qualify our inclusion criteria of current study.

Inclusion criteria of current study are-

- Fracture neck femur, displaced intracapsular fracture
- Fracture duration 0 days to up to 3 weeks since injury to presentation in orthopaedic department
- Age of patients \leq 55yrs
- Medically fit for anaesthesia point of view

ExclusionCriteria are-

- Fracture Neck femur un-displaced fractures (managed by Cannulated canceous Screw (CCS))
- Age > 55 yrs, Managed by fibular grafting
- Previous any surgery around hip area also excluded

Out of 44 cases 30 were female and 14 were male with age range from 18yrs to 48 yrs and average age of 42 yrs. Average duration from injury to operative procedure was 1.5weeks (10 Days) and range from 0 days to 2 weeks. Patients were kept on skin traction. Preoperative radiological assessment done with X-ray Pelvis with bone hip in internalrotation AP view and lateral view of fractured site. All these cases were investigated on routine manner and posted for elective procedure as soon as possible depending on anaesthesia fitness.

Informed consent was taken from every patient with proper explanation of the procedure and probable short term and long term complications. Ethical clearances for the procedures were taken from the ethical committee of our Institute. Fractures were classified using Pauwels' classification^{8,9} and angle of fracture line recorded according to the classification.

Operative procedure(Modified): All cases were operated on fracture table with the help of image intensifier. Indirect reduction done by traction and rotation of the lower limb combined with manual

lateral traction at upper thigh in some cases. Reduction checked on C arm and maximal possible reduction accepted in all cases without going for open reduction. This reduction is temporarily fixed with thick k wire passed percutaneously from proximal part of trochanter to femoral head missing the neck of femur. Now trochanter exposed from lateral incision and guide wire for Richard screw inserted from most prominent part of the trochanter to inferior part of the head of femur and position checked in AP and Lat view. Second guide wire for Cannulated Cancellousscrew(CCS) was inserted parallel to first guide wire 1.5 cm proximal to the first guide wire. Second guide wire passed to superior part of the neck to head of femur to give the space for Richard screw. Cannulated drill passed over second proximal guide wire and then proper size cannulated Cancellous 6.5mm screw passed over guide wire to superior part of head and partially tightened to proximate the both fragments. Double reamer passed over first guide wire and Richard screw of proper length passed so that it remains 5 mm inside the lateral wall of trochanter to allow the coupling screw to give compression. Double angle barrel plate(DABP) was passed over Richard screw and coupling screw tightened to give compression at fracture site. Partially loosen the coupling screw so that it allows rotation of the plate. Plate rotated along the long axis of femur. At this point distal end of the plate will be at distance from the femur and plate proximal to angle will be in contact of trochanter. At the angle of plate femur is marked by drill bit under direct vision and also with the help of C arm. This mark was taken as proximal horizontal osteotomy site of femur. Plate now rotated upwards so that osteotomy site can be exposed and with the help of oscillating saw horizontal cut were taken from marked area up to medial cortex. Medial cortex left intact. The length of the wedge is not fixed in all cases. This is depends on the diameter of the femur of that particular case. To determine the wedge length, plate rotated back along the long axis of femur. With the help of depth gauge or scale the horizontal diameter of the femur at the site of horizontal osteotomy taken(X mm). Plate is marked at X mm from the angle of the plate to distally. From this marked point on plate the gap between plate and femur lateral cortex noted (Y mm). This Y mm is the length of the wedge we have to taken from proximal horizontal osteotomy site. Oblique osteotomy done Y mm distal to the proximal osteotomy upward so that wedge closed over medial cortex. Medical cortex left intact during osteotomy. Now wedge of the bone removed by osteotome or kockerforcep. Now plate rotated back to long axis of femur and centered. Lowman's clamp applied between distal end of plate and femur. Gradual closure of the Lowman's screw done to proximate the plate toward femur and closing of wedge checked on

Image intensifier. Traction is released and CCS and coupling screw tightened. Plate fixed to lateral surface of femur with cortical screws using dynamic compression method to give compression at osteotomy site. One 6.5 mm cancellous screw passed through proximal most hole of plate proximal to angle of plate toward inferior part of neck parallel to Richard screw. Wound closed in layers over the drain.

During post operative period, IV antibiotics given for 3 days. Drain removed after 24 to 48 hrs. Radiographs were taken once post operative pain permits. X-ray Pelvis with both hip in internal rotation and lateral view of operated hip. Post operative radiograph assessed and compared with pre operative radiograph with relation to change in angle of fracture line. Patient kept on non weight bearing and non weight bearing physiotherapy of knee and hip joint advised for 6 weeks. Cases were followed up every 4 weeks for three month followed by every 6 weeks for next 6 month and then every 8 weeks for 3 years. Post operative weight bearing was allowed after 6 weeks of osteotomy. First partial weight bearing was allowed using walker and after 6 weeks gradual increase in weight bearing allowed. Cases were also assessed Radio logically during each follow up. During follow up any loss of reduction, varus collapse, screw cut-out, non-union and avascular Necrosis noted. During follow up the functional outcome of cases were recorded and final outcome assessed using **Modified Ask in and Bryan criteria**¹⁰. Final outcome recorded after 4 years of follow up and result graded as Excellent, Good and Fair group. We operated total 44 cases of neglected fracture of neck of femur in young adult during the period of Aug 2006 to August 2012.

RESULTS

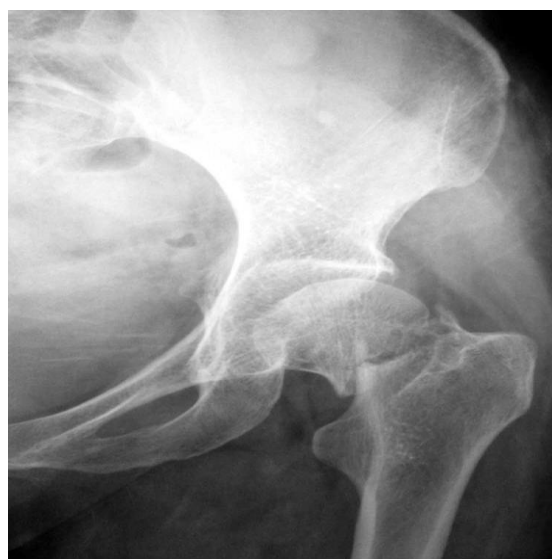The final outcomes of procedure were assessed periodically and final outcome assessed at 4yrs of operation. The final outcome assessed using **Modified Ask in and Bryan's criteria**¹⁰.

Modified Ask in and Bryan criteria.

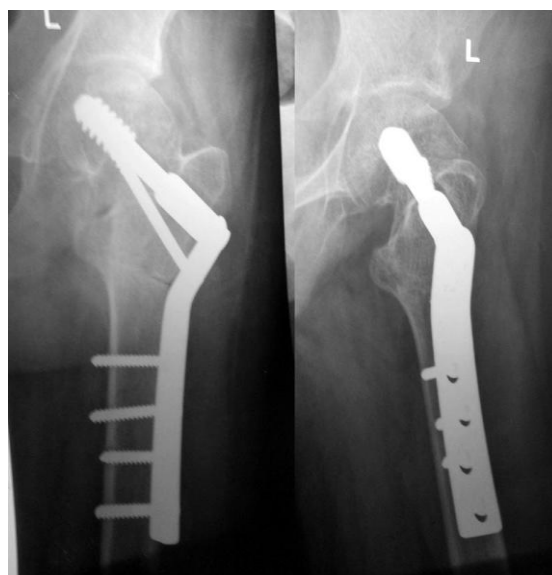Excellent	No pain, near normal gait, <20% restriction of ROM, normal activity.
Good	Mild pain & limp, 20-40% restriction of ROM, mild restriction of activity.
Fair	Continuous pain, marked restriction of ROM and activity, need walking aid.

In accordance to this criteria cases evaluated with respect to presence of pain, Gait of the patient, need of walking aid, Range of motion of hip Joint(ROM) and activity of daily life. Out of 44 cases operated 42 cases followed up to the average duration of 48 months. Out of total 42 cases, 38 cases show good(18) to Excellent(20) results after 4 yrs. 4 cases

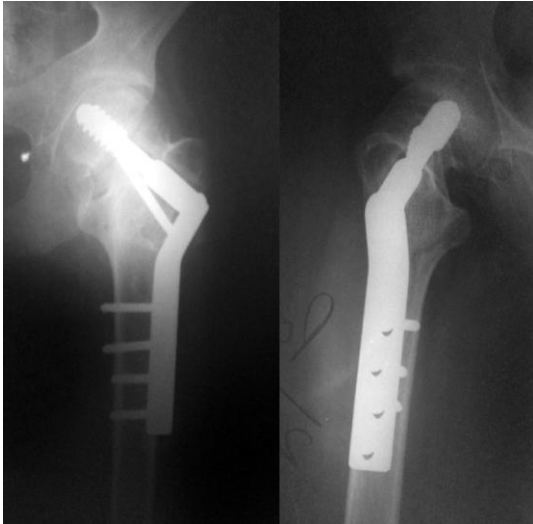unable to continue with same implant due to loss of reduction, neck collapse and non-union. Revision surgery require in these 4 days. During follow up avascular necrosis were seen in 7 cases. Out of these 7cases, 4 cases given poor result due to lose of reduction, head collapse combined with Avascular necrosis(AVN). Out of 7 cases of Avascular necrosis (AVN), 3 cases goes into union. During follow up they threecases shows reversal of Avascular Necrosis (AVN) of femoral head.Out of 42 cases 38 cases were able to perform squatting after 4yrs of follow up and also there were no radiological sign Avascular Necrosis (AVN)of head at all. Loss of reduction and screw cut out seen in two cases and these were in poor outcome group.



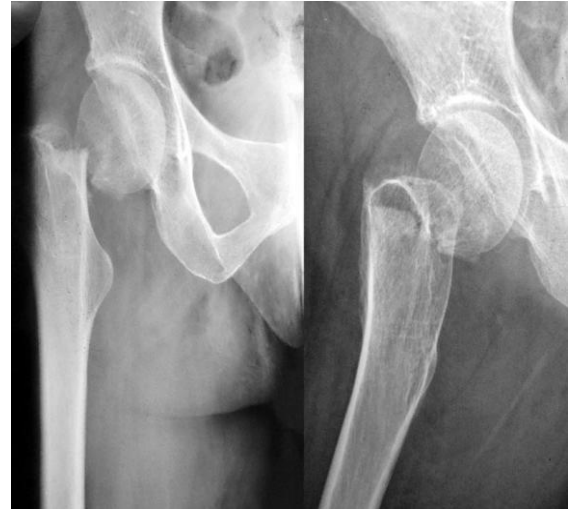Case 1.1 Preoperative X-ray showing femoral Neck Fracture



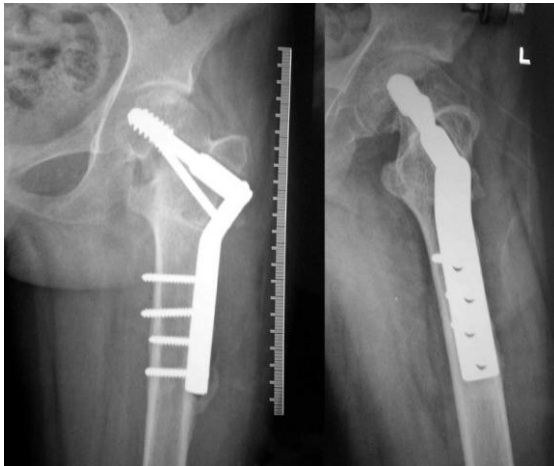
Case 1.2 Post Operative Follow up X-ray at 4 weeks showing DABP and osteotomy site visible



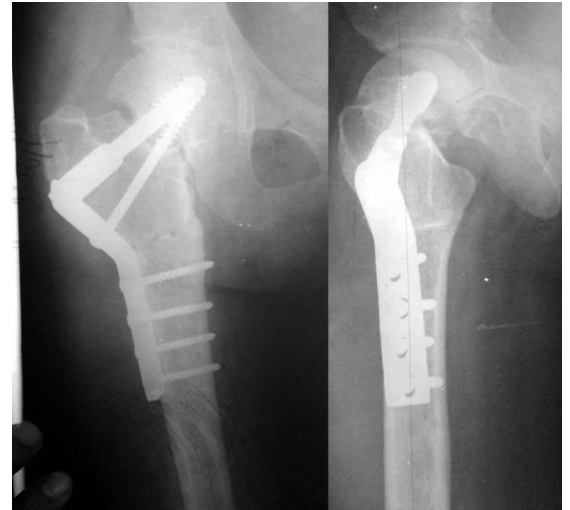Case 1.3 Post Operative Follow up X-ray at 8 weeks showing DABP and osteotomy site united



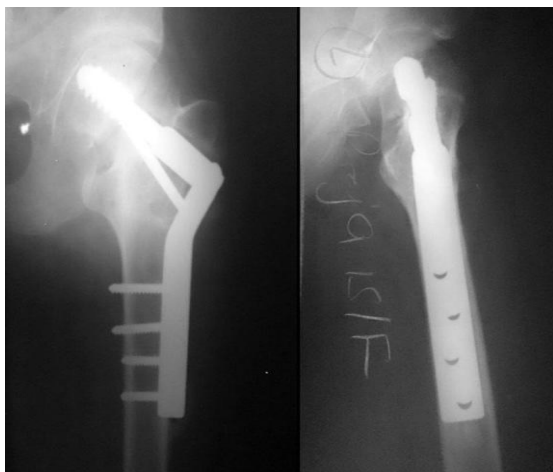
Case 2.1 Preoperative X-ray showing femoral Neck Fracture



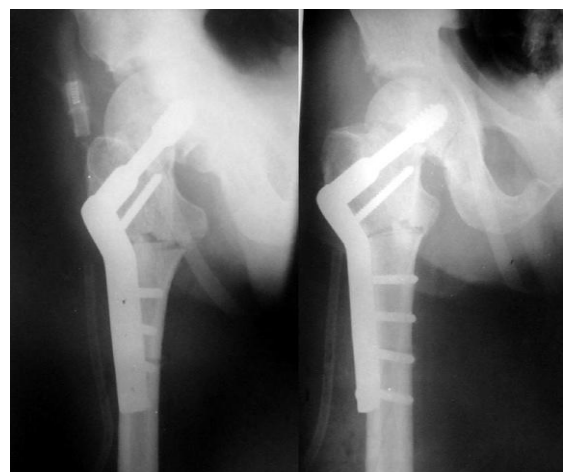Case 1.4 Post Operative Follow up X-ray at 12 weeks showing DABP. Osteotomy and fracture neck united



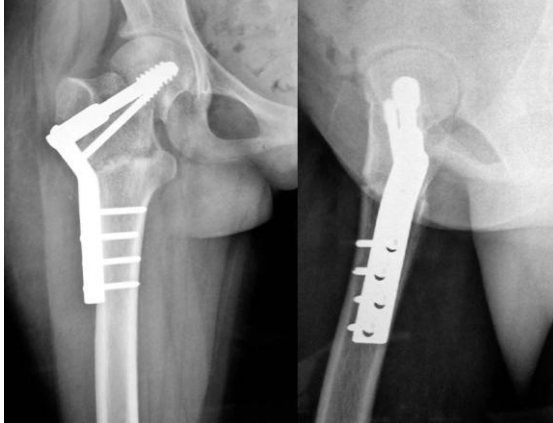
Case 2.2 Post Operative Follow up X-ray at 4 weeks showing DABP and osteotomy site visible



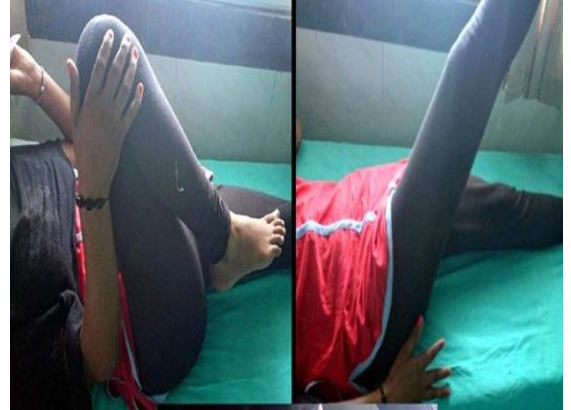Case 1.5 Post Operative Follow up X-ray at 20 weeks showing DABP. osteotomy and fracture neck united and consolidated



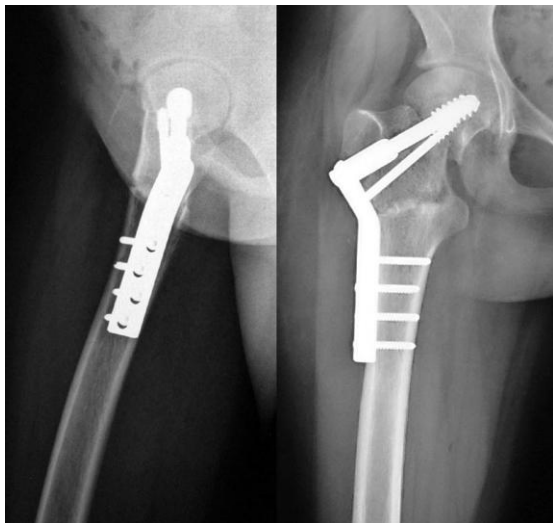
Case 2.3 Post Operative Follow up X-ray at 8 weeks showing DABP and osteotomy site visible



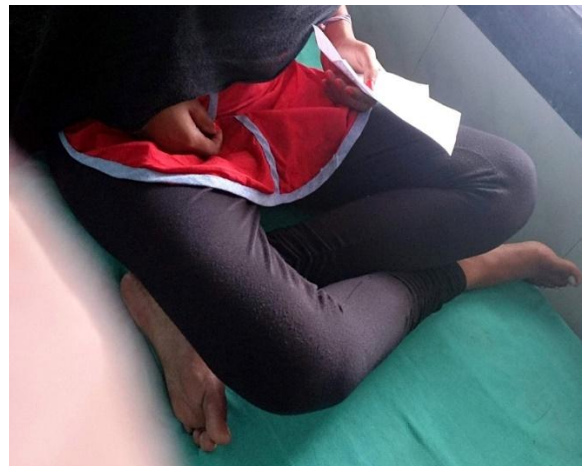Case 2.4 Post Operative Follow up X-ray at 12 weeks showing DABP and osteotomy site uniting



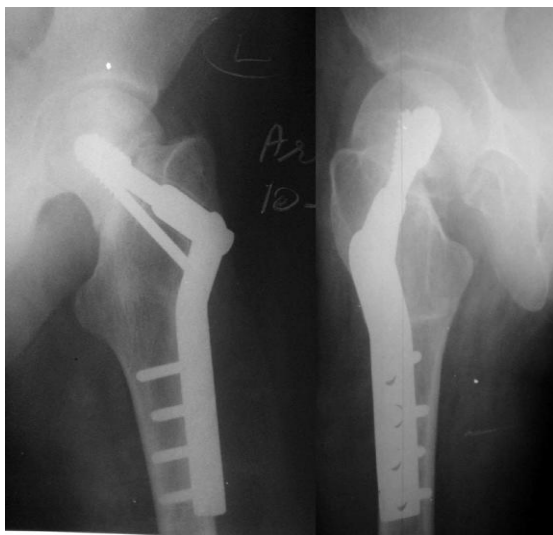Clinical picture showing hip Movements



Case 2.5 Post Operative Follow up X-ray at 20 weeks showing DABP and osteotomy Uniting



Clinical picture showing hip Movements and cross legged sitting



Case 2.6 Post Operative Follow up X-ray at 28 weeks showing DABP. Osteotomy site and fracture united

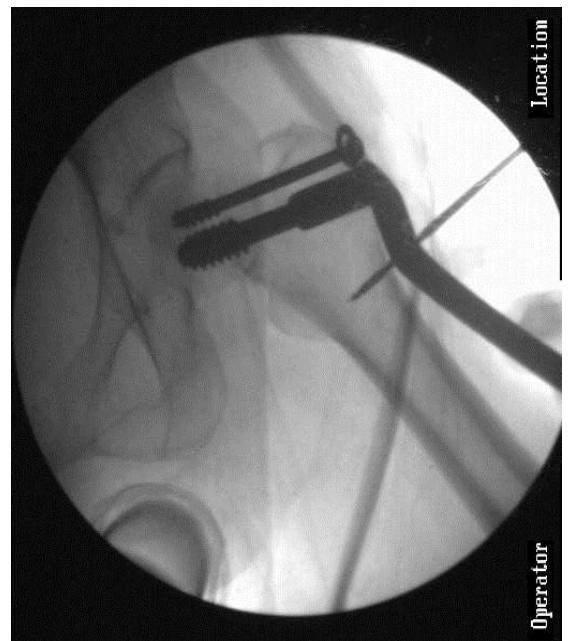

Image view 1 Insertion of Richards Screw and CCScrew, Marking Osteotomy site at the angle of plate.

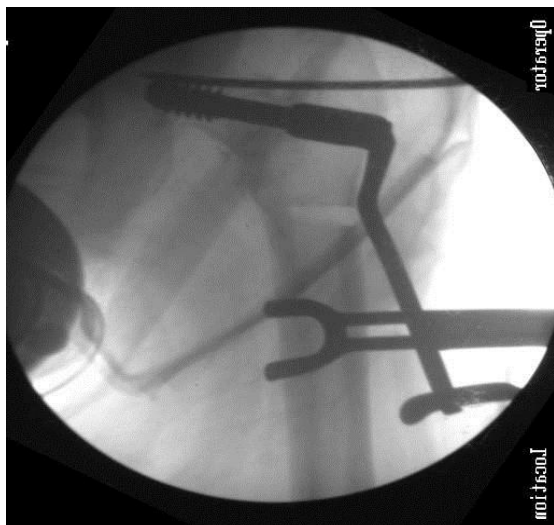


Image view 2 -wedge Osteotomy done at the site of plate bent. Lowman's clamp applied

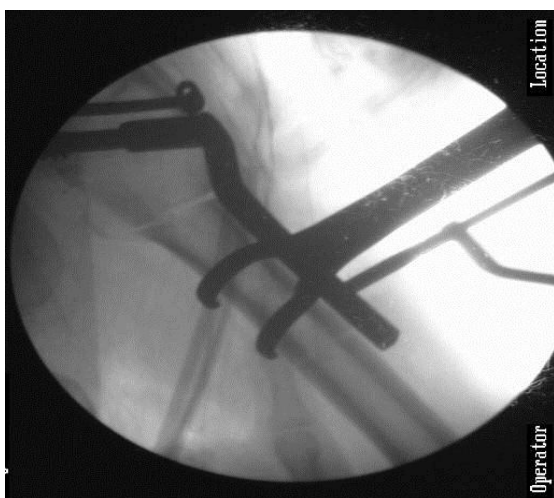


Image view 3 Gradual closure of osteotomy site by tightening of Lawman's Clamp, Osteotomy site closed.

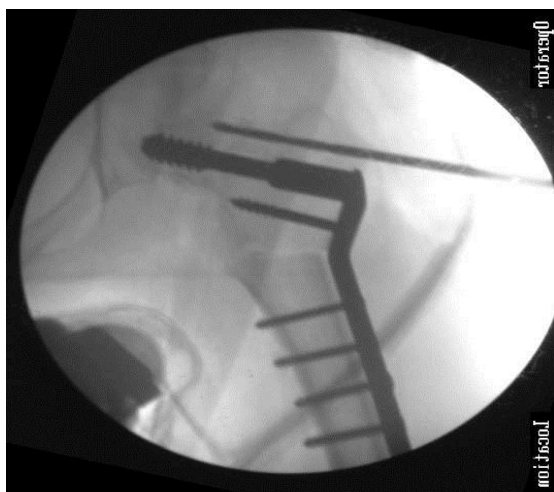

Image view 4 Final View of Plate with Richards Screw

DISCUSSION

Fracture neck femur is not very uncommon in developing country like India. Due to poor socio-economical status and lack of education in rural area, these injuries tend to be neglected. Fracture neck femur tends to be neglected more than intertrochanteric fracture because of factors like less severity of injury and lack of gross deformity. Most local bone setter tends to manage these fractures as soft tissue injuries and give massage and manipulations. These fractures are more common in osteoporotic and osteomalacia females and these cases don't get attention due to gender bias in our rural areas.

Numerous methods were advised in literature for the management of fracture neck of femur in young adults. Various methods were used for preservation of head in fracture femur in young adults such as Multiple cannulated cancellous screw¹¹, fibula graft with screw^{12,13}, vascularised fibular graft^{14,15,16}, vascularised iliac bone graft^{17,18}, muscle pedicle graft^{19,20} various osteotomy around hip^{21,22,23} and combination of these procedures²⁴.

According to **Sandhu et al**⁴, there are changes seen in the area of neglected femoral fracture like smoothing of fracture margin, neck resorption and osteonecrosis. Various study show good results of treatment of non union of neglected neck fracture with valgus osteotomy. **Marti et al**²⁵ 1989 done 50 cases of neck fracture with 86% union rate and developed technical difficulties in 6 cases. **Anglen et al**²¹ (1997) had done double angle barrel plate in 13 cases with 100% union rate and two AVN. **Kalra and Anand**²³ in 2001 operated 20 cases of neglected neck femur fracture of more than one month old with double angle blade plate and intertrochanteric osteotomy with 85% union rate and two avascular necrosis. They also reported good to excellent result in 75% of cases after a follow up of 30 months. **KK Pruthi et al**²⁶ (2004) done 28 cases of neglected fracture neck femur with double angle barrel plate and show 88% union rate and two cases of implant cut out, **Hartford**(2005)²⁷ operated 8 cases with hip screw with followed their cases for 4-14 months and achieved 88% union rate. **Gupta et al**²⁸ in 1988 operated 25 young adults (age 15-50 years) with femoral neck fractures were operated on an ordinary operating table, using a Watson-Jones approach. Open reduction of the fracture site through an anterior capsular incision was performed and fixation with three cancellous screws was done. Patients were regularly assessed for clinical and radiological evidence of non-union and avascular necrosis. Average follow-up was 32 months. Non-union was seen in one case (4 per cent) and evidence of avascular necrosis was seen in three cases (12 per cent). **Kalra et al**²³ (2001) operated 20 cases of neglected displaced femoral neck fracture in young adults with valgus intertrochanteric osteotomy and

reported union rate of 85% and two healed cases developed avascular necrosis with over all excellent long term result in 75% of cases. **Said GZ et al**²⁹ (2010) managed Thirty-six patients presented with 19 recent vertical femoral neck fractures, and 17 non-unions with Valgus intertrochanteric osteotomy (VITO) and achieved Union in 35 patients (97%), and one recent fracture failed to unite (3%). **Sen RK et al**³⁰ (2011) operated 22 cases of failed neck fracture Cannulated Cancellous Screw(CCS) fixation cases with revision surgery using angle blade plate and autologous free fibular graft and reported 91% union rate. They reported good to excellent result in 14 cases after 3.2 yr of follow up. **Kainth GS et al**³¹(2011) operated 22 cases of neglected neck femur by valgus osteotomy and double angle 120 blade plate in 8 case and with fibular grafting and Cannulated Cancellous Screw(CCS) in 14 cases and achieved good to excellent outcome in 19 cases. They reported union in 21 cases and AVN in two cases. **Khan AQ et al**³² (2009) operated 16 cases of neglected femoral neck fracture with valgus osteotomy and fixation with 120 double angle barrel plates and achieved union in 14 cases and cut-out seen in 2 cases. **Bansal P et al**³³ (2013) operated 30 cases of neglected fracture of femur of age from 20yrs to 60 yrs using 120 double angle barrel plate and hip screw. Union was achieved in 28 cases. Two cases went into non-union and were treated by arthroplasty later on. **Pal CP et al**³⁴(2014) operated total 72 cases of neglected fracture of femur using fibular strut graft with cancellous screw and showed excellent result and noted non-union in 4 cases. **Gupta S et al**³⁵ (2014) operated 60 cases of femoral neck fracture using valgus sub-trochanteric osteotomy and repositioning and using 135 single angle blade plate and achieved union in 56 cases and 4 cases developed Avascular Necrosis (AVN).They reported excellent result in30 cases, good result in 24 cases and poor result in 6 cases. Four of their cases developed Avascular Necrosis (AVN).

In current study our result is comparable to already present study in these fractures. Out of 42 cases 38 cases(90%) shows good to excellent result according toModified Askin and Bryan criteria after four years (48 Months) of follow up. 7 cases shows radiological sign of avascular necrosis during follow up and out of these 7 cases 3 cases fracture united and functional outcome was good. Rest 4 cases shows poor result.

CONCLUSION

Femoral neck fracture in young adults could well be managed by Primary Double Angle Barrel Plate (DABP) combined trochanteric valgus osteotomy with good to excellent results in majority of cases and replacement surgery should be reserved for collapse heads and failed osteosynthesis cases.

Conflicts of Interest: None

Abbreviations Used	Full Form
CCS	Cannulated cancellous Screw
DABP	Double angle barrel Plate
AVN	Avascular Necrosis
VITO	Valgus intertrochanteric osteotomy
ROM	Range Of Motion
IV	Intra Venous

REFERENCES

1. Banks HH. Nonunion in fractures of the femoral neck. *OrthopClin North Am* 1974;5:865–85.
2. Calandruccio RA, Anderson WE 3rd. Post-fracture avascular necrosis of the femoral head: correlation of experimental and clinical studies. *ClinOrthopRelat Res* 1980;152:49–84.
3. Dedrick DK, Mackenzie JR, Burney RE. Complications of femoral neck fracture in young adults. *J Trauma* 1986;26:932–7.
4. Sandhu HS, Sandhu PS, Kapoor A. Neglected fractured neck of the femur: a predictive classification and treatment by osteosynthesis. *ClinOrthopRelat Res* 2005;431:14–20.
5. Cartledge IJ. Primary total hip replacement for displaced subcapital femoral fractures. *Injury* 1981;13:249–53.
6. Coates RL, Armour P. Treatment of subcapital femoral fractures by primary total hip replacement. *Injury* 1979;11:132–5.
7. Gregory RJ, Wood DJ, Stevens J. Treatment of displaced subcapital femoral fractures with total hip replacement. *Injury*1992;23:168–70.
8. Pauwels F. Schenkelhalsbruch. Einmechaizisches problem. F. Enke. Stuttgart; 1935
9. Bartonicek, J. Pauwels' classification of femoral neck fractures: correct interpretation of the original. *J Orthop Trauma*. 2001;15:358–360
10. Askin SR, Bryan RS (1976) Femoral neck fractures in young adults. *ClinOrthop* 114:259–264
11. Haidukewych GJ, Rothwell WS, Jacofsky DJ, Torchia ME, Berry DJ. Operative treatment of femoral neck fractures in patients between the ages of fifteen and fifty years. *J Bone Joint Surg Am* 2004;86:1711–6.
12. Azam MQ, Iraqi A, Sherwani M, Sabir AB, Abbas M, Asif N (2009) Free fibular strut graft in neglected femoral neck fractures in adult. *Indian J Orthop* 43(1):62–66
13. Elgafy H, Ebraheim NA, Bach HG (2011) Revision internal fixation and nonvascular fibular graft for femoral neck nonunion. *J Trauma* 70:169–173
14. Jun X, Chang-Qing Z, Kai-Gang Z, Hong-Shuai L, Jia-Gen S (2010) Modified free vascularized fibular grafting for the treatment of femoral neck nonunion. *J Orthop Trauma* 24:230–235
15. LeCroy CM, Rizzo M, Gunneson EE, Urbaniak JR. Free vascularized fibular bone grafting in the management of femoral neck nonunion in patients younger than fifty years. *J Orthop Trauma* 2002;16:464–72.
16. Nagi ON, Dhillon MS, Goni VG (1998) Open reduction, internal fixation and fibular autografting for neglected fracture of the femoral neck. *J Bone Joint Surg Br* 80:798–804

17. Chang MC, Lo WH, Chen TH (1999) Vascularised iliac bone graft for displaced femoral neck fracture in young adults. *Orthopedics* 22:493–498
18. Hou SM, Hang YS, Liu TK. Ununited femoral neck fractures by open reduction and vascularized iliac bone graft. *ClinOrthopRelat Res* 1993;294:176–80.
19. Baksi DP (1986) Internal fixation of ununited femoral neck fracture combined with muscle pedicle grafting. *J Bone Joint Surg [Br]* 68:239–245 365
20. Meyers MH, Harvey JP Jr, Moore TM. Treatment of displaced subcapital and transcervical fractures of the femoral neck by muscle-pedicle-bone graft and internal fixation. A preliminary report on one hundred and fifty cases. *J Bone Joint Surg Am* 1973;55:257–74.
21. Anglen JO. Intertrochanteric osteotomy for failed internal fixation of femoral neck fracture. *ClinOrthopRelat Res* 1997;341:175–82.
22. Ballmer FT, Ballmer PM, Baumgaertel F, Ganz R, Mast JW (1990) Pauwels osteotomy for nonunions of the femoral neck. *OrthopClin North Am* 21:759–767
23. Kalra M, Anand S. Valgus intertrochanteric osteotomy for neglected femoral neck fractures in young adults. *IntOrthop* 2001;25:363–6.
24. Beris AE, Payatakes AH, Kostopoulos VK, Korompilias AV, Mavrodontidis AN, Vekris MD, et al. Non-union of femoral neck fractures with osteonecrosis of the femoral head: treatment with combined free vascularized fibular grafting and subtrochanteric valgus osteotomy. *OrthopClin North Am* 2004;35:335–43.
25. Marti RK, Schuller HM, Raaymakers EL. Intertrochanteric osteotomy for non-union of the femoral neck. *J Bone Joint Surg Br* 1989;71:782–7.
26. K.K. Pruthi, H. Chandra, R.K. Goyal, and V.P. Singh. Repositioning osteotomy with dynamic hip screw with 120o double angled barrel plate fixation in fracture neck femur. *Ind J Orthop*2004;38:92-95.
27. Hartford JM, Patel A, Powell J. Intertrochanteric osteotomy using a dynamic hip screw for femoral neck nonunion. *J Orthop Trauma* 2005;19:329–33.
28. Gautam VK, Anand S, Dhaon BK (1998) Management of displaced femoral neck fractures in young adults (a group at risk). *Injury* 80-B:474–475
29. Said GZ, Farouk O, Said HG (2010) Valgus intertrochanteric osteotomy with single-angled 130° plate fixation for fractures and non-unions of the femoral neck. *IntOrthop* 34(8):1291–1295
30. Sen RK. Management of avascular necrosis of femoral head at pre-collapse stage. *Indian J Orthop* 2009;43:6–16.
31. Kainth GS, Yuvarajan P, Maini L, Kumar V. Neglected femoral neck fractures in adults. *Journal of orthopaedics surgery* 2011;19(1):13-7
32. Khan AQ, Khan MS, Sherwani MK, Agarwal R. Role of valgus osteotomy and fixation with dynamic hip screw and 120 degrees double angle barrel plate in the management of neglected and ununited femoral neck fracture in young patients. *J OrthopTraumatol* 2009;10:71–8.
33. Bansal P, Singhal V, Lal H, Mittal D, Arya RK. A convenient Way to do Valgus Osteotomy for Neglected Fracture Neck of Femur. *Kathmandu Univ Med J* 2013;42(2):147- 151.
34. Pal CP. Kumar B, Dinker KS, Singh P, Kumar H, Goyal RK. Fixation with cancellous screw and fibular strut graft for neglected femoral neck fractures. *journal of orthopaedics surgery* 2014;22(2):181-5
35. Gupta S, kukreja S, Singh V. Valgus osteotomy and repositioning and fixation with a dynamic hip screw and a 135° single-angled barrel plate for un-united and neglected femoral neck fractures. *J orthop surgery* 2014;22(1):13-7.