

# Chronic type III unstable slipped capital epiphysis and its management: A study

Maruthi CV<sup>1,\*</sup>, Venugopal N<sup>2</sup>

<sup>1</sup>Assistant professor, Department of Orthopaedics,  
Chamarajanagar Institute of Medical Sciences, Chamarajanagar - Karnataka  
<sup>2</sup>Professor, Department of orthopaedics, MVJMC, Hoskote, Bangalore, India

**\*Corresponding Author:**

E-mail: orthocvmaruthi@gmail.com

## ABSTRACT

An unusual condition of the hip joint seen in the children between ten to sixteen years of age group is slipped capital femoral epiphyses. Chronic unstable type III is rareone. The management is usually in-situ fixation. Here we studied three cases between June 2008 to April 2013 in our institution by managing the slip by closed reduction and internal fixation using single cannulated cancellous screw. The follow up,done at one, three, six, twelve and twenty-four months for clinical and radiological evaluation. And at the end of two years we observed complete healing of the slip without any complications like avascular necrosis and or chondrolysis. All the patients evaluated using modified Harris hip score and all were in excellent outcome. We conclude that chronic unstable type III slips can be managed by closed reduction and internal fixation using single cannulated cancellous screw. According to the Harris hip score we achieved excellent results. With, scores of 95, 97 and 97 in our study. Our study is statistically significant. The p value is 0.015 by chai squire test and it is statistically significant.

**Keywords:** Chronic, Unstable, Type III, Closed reduction, internal fixation

Access this article online	
Quick Response Code:	Website: www.innovativepublication.com
	DOI: 10.5958/2395-1362.2015.00032.8

## INTRODUCTION

An unusual condition of the hip joint seen in the children between ten to sixteen years of age group is slipped capital femoral epiphyses. The management of chronic unstable type III slipped capital femoral epiphyses is controversial [1,2]. Here we are done a study to know the efficacy and prognosis for managing chronic unstable type III slipped capital epiphysis by closed reduction and internal fixation using single cannulated cancellous screw.

## MATERIALS AND METHODS

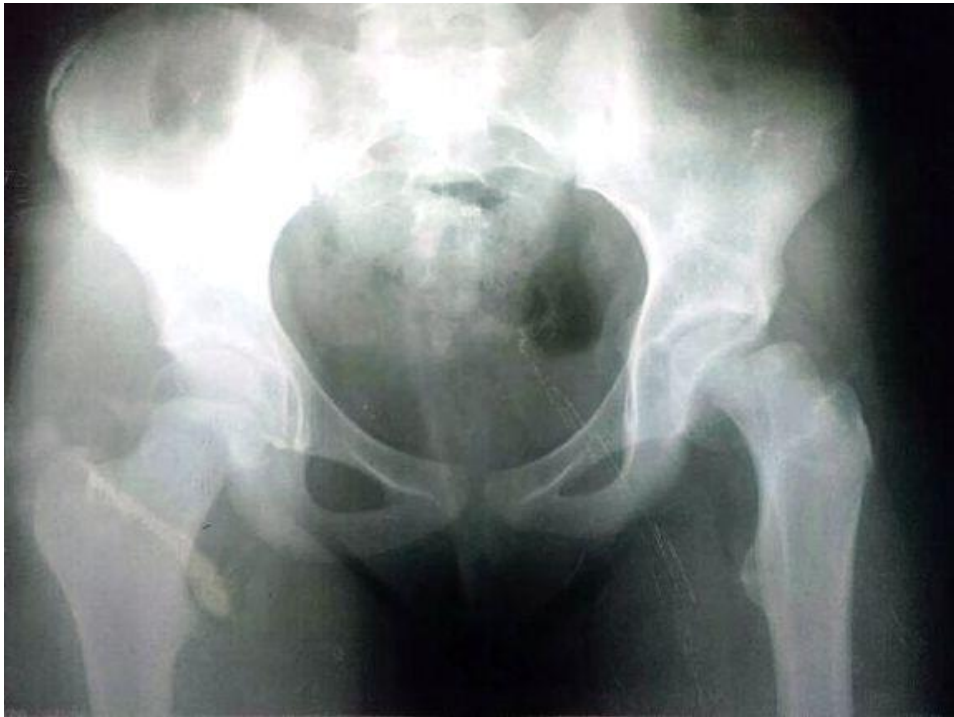We have done study between June 2008 to April 2013, and selected cases suffering from chronic that is more than three weeks old, unstable not able to bear weight on the affected limb and type III by

radiological examination that is more than 50% slip. In our study one patient was in the age group of 11 years and two were in the age group of twelve (Table 1). All were females. The duration of the symptoms was 32, 27 and 35 days in our patients.

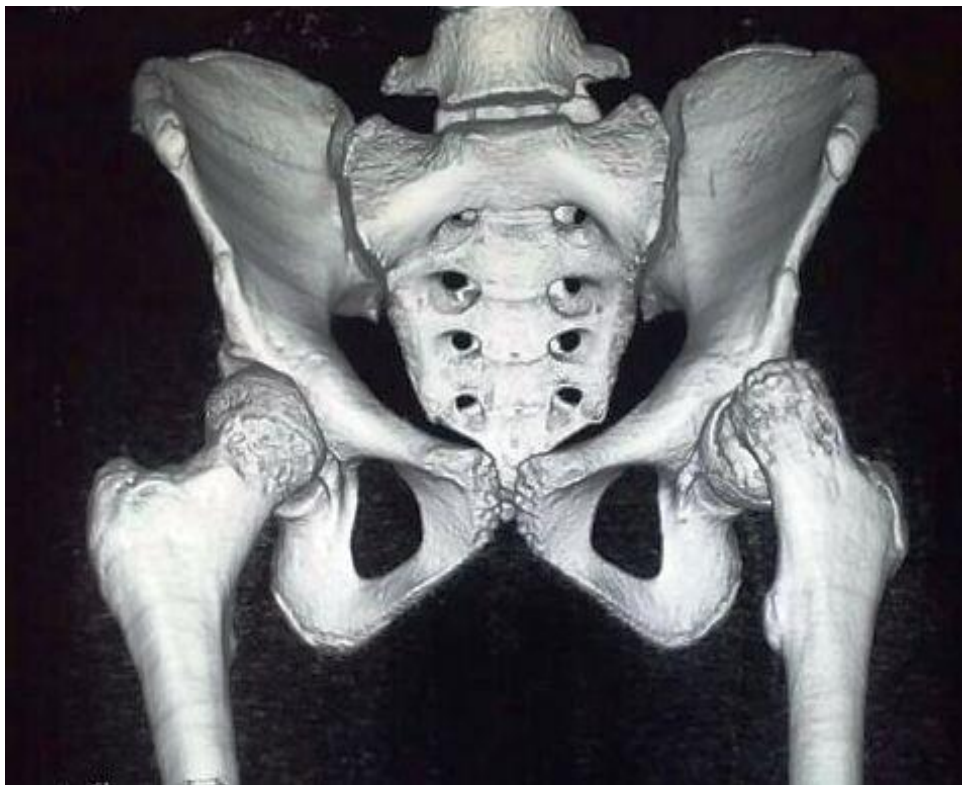The symptoms in our cases were pain in the groin, unable to walk. And all the patients were carried by their parents after lifting them to the hospital. The diagnosis was confirmed by Pelvis with both hips antero-posterior and frog leg lateral view x-ray examination (Fig 1) and 3D CT examination (Fig 4). This confirms the diagnosis of slipped capital femoral epiphysis and amount of displacement; it was more than 50% in all our cases. In our series we observed all three were left side affected. All the patients were admitted and subjected for the blood investigations Haemoglobin, total white blood cell count, bleeding time, clotting time, random blood sugar, blood urea, serum creatinine. All the patients were taken for the surgery under spinal anaesthesia. Before painting and draping closed reduction was attempted under image intensifier guidance and in our cases we achieved complete reduction of the slip. After reduction the limb was put in fracture table by lateral approach, we stabilized the slip using single cannulated cancellous screw (Fig 3).

**Table 1:**

SL NO	Age	Mechanism of injury	Sex	side	Duration of symptoms	Day of surgery
1	12	Fall while dancing	F	left	32 days	33 <sup>rd</sup> day
2	11	Fall while playing	F	left	27 days	27 <sup>th</sup> day
3	12	Fall while playing	F	left	35 days	35 <sup>th</sup> day



**Fig. 1**



**Fig. 2**

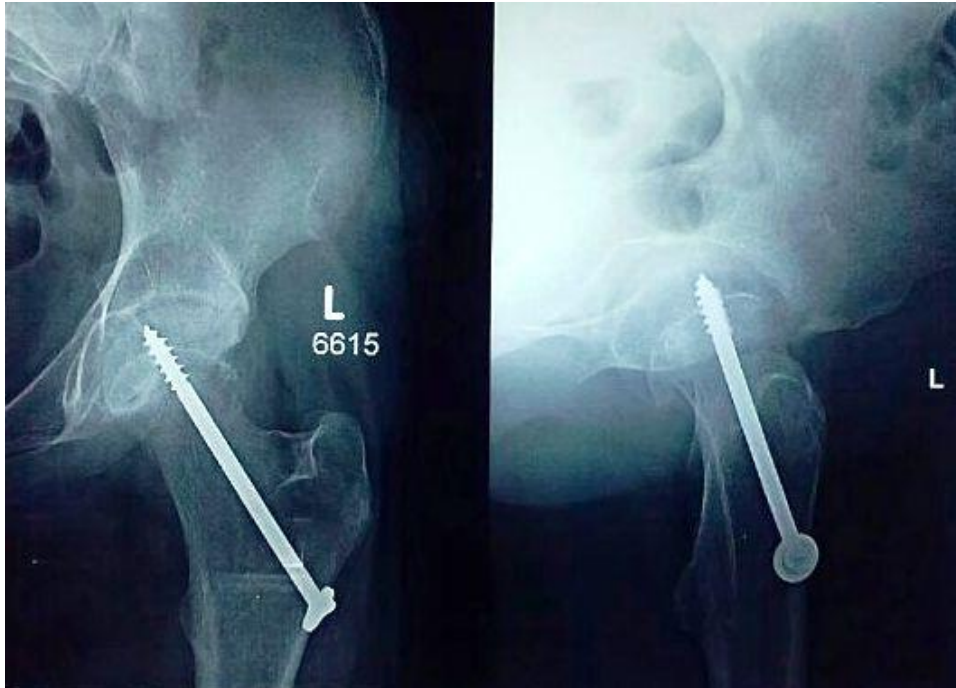


Fig. 3

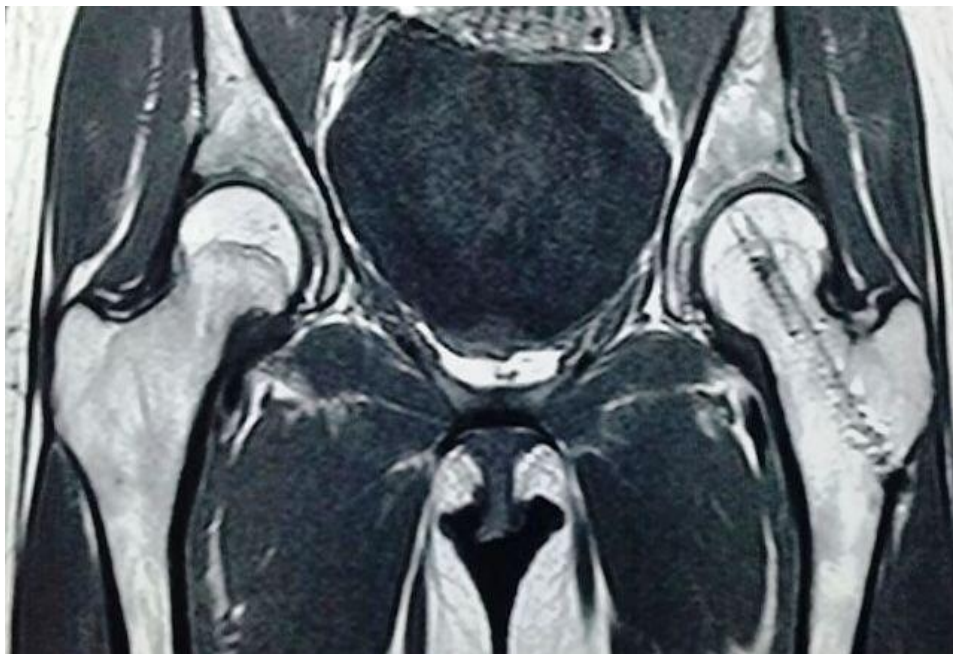

Fig. 4

### OBSERVATIONS

All the patients were started with non-weight bearing walking on the unaffected limb using axillary crutches from day three. Follow up done at one, three, six, twelve and twenty four months for clinical and radiological evaluation. In all our cases we started quadriceps exercises by second postoperative day and range of motion exercises at hip by third postoperative day. We achieved full range of movements at the hip by six weeks in our

study with any restriction. In all the cases we studied there was complete reduction of slip was noticed at the end of two years and complete healing of physeal injury, without any complications like avascular necrosis of femoral head (Fig-4). All the patients evaluated using modified Harris hip score and all were in excellent outcome. With, scores of 95, 97 and 97 in our study. The p value is 0.015 by chi square test and it is statistically significant.

## DISCUSSION

The unusual disorder of the hip joint seen in children between 10 to 16 years of age is Slipped capital femoral epiphysis. It's not rare in clinical practice. If the condition is seen in children less than ten years of age, usually associated with endocrine abnormalities like pan hypopituitarism, renal osteodystrophy, hypogonadism, hypothyroidism [3,4,5 and 6]. It is most commonly as unilateral disorder, if it is bilateral, usually associated with above mentioned endocrine abnormalities. During the preadolescence and adolescence the direction of physis changes from horizontal to oblique. The change in direction leads to change in compression forces to shearing forces[7]. The physal cartilage in cases prone for slipped capital femoral epiphysis will show widening of the zone of hypertrophy to eighty percent of the physal plate(Normal-15%). Cartilage maturation, endochondral ossification is the microscopic changes noted in the hypertrophic zone of physal plate. The above mentioned features, leading to weakly organized cartilage in the physal plate and prone for slippage. Depending on the duration they are classified as acute if the duration is less than three weeks, chronic if the duration is more than three weeks and acute on chronic if the duration is more than three weeks with acute symptoms. If patient is able to bear weight on the affected limb it is called stable hip and if unable to bear weight they are called unstable hips. The diagnosis is confirmed by x-ray examination of the hip by anteroposterior and frog-leg lateral views of the hip joint. By x-ray examination we can see the loss of normal transection of the epiphysis after drawing a horizontal line over the femoral neck called Kliens line in cases suffering from slipped capital epiphysis. Depending on the amount of slip they are classified as type-I if it is less than 33%, type-II if the amount of slip is between 33-50% and Type-III if the slip is more than 50% of the epiphyseal cartilage.

In our study we selected exclusively chronic, unstable type-III slips [8]. The management of the slipped capital femoral epiphysis is in-situ fixation as early as possible to prevent the deadly complications of the hip joint like avascular necrosis and chondrolysis. In the past, Knowles pins, threaded Steinmann pins, hip compression screws and cannulated screw were used for fixation of the slip. In this modern world of orthopaedics single, larger diameter central pin or screw is the implant of choice as it is technically less demanding than insertion of multiple pins. In our study we managed chronic unstable type-III slips by closed reduction and internal fixation under the guidance of image intensifier and fixation using single cannulated cancellous screw[9,10, and 11]. In literature we have evidence for management of chronic stable slips, but for the management of chronic unstable type III is

controversial. In our study we are done closed reduction and internal fixation for the chronic unstable type III slips with excellent outcome at the end of two years follow up and confirmed by MRI examination to rule out any features of avascular necrosis once screw was removed. The features of avascular necrosis are not seen for 6-24 months in routine X-ray examination. In our study the follow up was minimum two years for all the cases as no signs of avascular necrosis of femoral head and also confirmed by MRI examination of the hip after implant removal[12,13]. In our cases we achieved full range of hip motion which indicated that there were no features of chondrolysis. And we achieved excellent outcome by modified Harris hip score. With, scores of 95, 97 and 97 in our study. Our study is statistically significant.

## CONCLUSION

Chronic unstable type III slipped capital epiphyseal injuries are rare. Even if the slip is four to five weeks old; the treatment should be closed reduction and internal fixation using single cannulated cancellous screw under the guidance of the image intensifier, which has got excellent clinical outcome. And it heals without any complications like avascular necrosis and or chondrolysis. According to Harris hip score we achieved excellent outcome with our three cases.

## REFERENCES:

1. Kehl DK. Slipped capital femoral epiphysis. Lovell WW, Winter RB, Morrissy RT, Weinstein SL, eds. Lovell & Winter's Pediatric Orthopaedics. 4th ed. Philadelphia, Pa: Lippincott, Williams & Wilkins; 1996.
2. Loder RT. Controversies in slipped capital femoral epiphysis. Orthop Clin North America. 2006 April. 37(2):211-21, vii.
3. Azzopardi T, Sharma S, Bennet GC. Slipped capital femoral epiphysis in children aged less than 10 years. J Pediatric Orthopaedics B. 2010 January. 19(1):13-8.
4. Riad J, Bajelidze G, Gabos PG. Bilateral slipped capital femoral epiphysis: predictive factors for contralateral slip. J Pediatric Orthopaedics. 2007 June. 27(4):411-4.
5. Hagglund G, Hansson LI, Ordeberg G, Sandstrom S. Bilaterality in slipped upper femoral epiphysis. J Bone Joint Surgery British. 1988 March. 70(2):179-81.
6. Brenkel JJ, Dias JJ, Davies TG, Iqbal SJ, Gregg PJ. Hormone status in patients with slipped capital femoral epiphysis. J Bone Joint Surgery British. 1989 January. 71(1):33-8.
7. Zupanc O, Krizancic M, Daniel M, et al. Shear stress in epiphyseal growth plate is a risk factor for slipped capital femoral epiphysis. J Pediatric Orthopaedics. 2008 June. 28(4):444-51.
8. Klein A, Joplin RJ, Reidy JA, Hanelin J. Roentgenographic features of slipped capital femoral epiphysis. American Journal of Roentgenol Radium Thermal Nuclear Medicine. 1951 September. 66(3):361-74.

9. Aronson DD, Carlson WE. Slipped capital femoral epiphysis. A prospective study of fixation with a single screw. *J Bone Joint Surgery America*. 1992 July. 74(6):810-9.
10. Ward WT, Stefko J, Wood KB, Stanitski CL. Fixation with a single screw for slipped capital femoral epiphysis. *J Bone Joint Surgery America*. 1992 July. 74(6):799-809.
11. Wensaas A, Gunderson RB, Svenningsen S, Terjesen T. Good long-term outcome of the untreated contralateral hip in unilateral slipped capital femoral epiphysis: Forty hips with a mean follow-up of 41 years. *J Childrens Orthopedics*. 2014 October. 8(5):367-73.
12. Castaneda P, Macias C, Rocha A, Harfush A, Cassis N. Functional outcome of stable grade III slipped capital femoral epiphysis treated with in situ pinning. *J Pediatric Orthopedics*. 2009 July-August. 29(5):454-8.
13. Krahn TH, Canale ST, Beaty JH, Warner WC, LourenCo P. Long-term follow-up of patients with avascular necrosis after treatment of slipped capital femoral epiphysis. *J Pediatric Orthopedics*. 1993 March-April. 13(2):154-8.