



Original Research Article

Radiological union: A study between open reduction and internal fixation vs. conservative treatment of clavicular fractures

Suraj Shetty¹, Mayur Rai^{1,*}, Shabir Kassim¹, Rishabh M Hegde¹, Shetty Gaurav Kishore¹

¹Dept. of Orthopaedics, A.J. Institute of Medical Sciences, Mangalore, Karnataka, India



ARTICLE INFO

Article history:

Received 19-02-2020

Accepted 17-03-2020

Available online 21-04-2020

Keywords:

Clavicle fracture

Operative

Non-operative

Radiological Union

Clavicle brace

ABSTRACT

Background: Clavicle Fracture is one of the most common bony injuries. Midshaft fractures have traditionally been treated conservatively. The prevalence of non-union or mal-union in displaced midshaft clavicle fractures after conservative treatment is higher as compared to those treated with ORIF. Surgery is believed to be the primary treatment for displaced midshaft clavicular fractures. Operative fixation of the clavicle fractures results in improved function, shorter time for union, and early return to activity as compared to those treated conservatively.

Materials and Methods: A hospital-based retrospective and prospective study was conducted at the Department of Orthopaedics, A.J. Institute of Medical Sciences and Research Centre, Mangalore, for two years. A total of 100 cases of midshaft clavicle fractures, meeting the inclusion and exclusion criteria were treated by operative and non-operative methods after ethical clearance. After 3 weeks, physiotherapy was started. Patient follow-ups were done at 6, 12 and 24 weeks and evaluated radiologically by a senior orthopaedic surgeon and radiologist.

Results: Males outnumbered females by 66% (i.e 83% against 17%). 54 patients (54%) had an RTA while the remaining 46 patients (46%) a history of fall. The youngest patient was 19yrs, and the oldest was 72yrs old. The mean age was 36.93 years. Amongst complications plate breakage in 1 patient, non-union in 13 patients and restriction of range of motion in 18 patients were seen. In our study, 63% of patients had left-sided fracture while the remaining 37% of patients had a right-sided fracture. Radiological union at 12 and 24 weeks was faster in the operative group ($p > 0.05$) than conservative group.

Conclusion: Midshaft clavicular fractures treated operatively have better union rates radiologically and clinically when compared to those treated conservatively.

© 2020 Published by Innovative Publication. This is an open access article under the CC BY-NC-ND license (<https://creativecommons.org/licenses/by/4.0/>)

1. Introduction

Clavicle fractures are common injuries and account for ~2.6–5% of all the fractures in adults.^{1,2} The most common mechanism of injury is a fall on the ipsilateral shoulder, athletes being particularly prone to this injury. 80–85% of these fractures occurring are in the midshaft where the conventional compressive forces are applied to the shoulder, and the narrow cross-section of the bone combine and result in bony failure.³ Open clavicular fracture is an absolute rarity and found in only 0.1–1% of cases.

* Corresponding author.

E-mail address: mayurrai28@gmail.com (M. Rai).

The rate of midclavicular fractures is more than twice as high in women. About 10% of patients have significant accompanying injuries, most frequently vertebral fractures, other shoulder girdle injuries, or broken ribs.^{4,5}

Traditionally, nonsurgical management has been favored as the treatment for most clavicular fractures.^{5,6}

However, recent evidence has emerged, indicating that operative fixation presents lower nonunion rates, better functional outcomes, improved cosmesis, and higher patient satisfaction compared with closed treatment. Surgery is believed to be the primary treatment for displaced midshaft clavicular fractures. Fixation resulted in improved function, shorter time for union, and early return to activity as

compared to those treated conservatively.

The objective of the study was to assess the safety and efficacy, time for radiological union, rate of non-union, malunion, and the complications of clavicular fractures treated by open reduction and internal fixation and conservative management.

2. Materials and methods

All cases presenting at AJ Institute of Medical Sciences and Research Centre in the out-patient department and casualty, meeting our inclusion and exclusion criteria during the study period were included. Our sample consisted of 100 patients, with 50 in each group of conservative and operative patients.

Patients above 18 years with closed mid-clavicular fractures were chosen, and those with any associated AC joint dislocation, medial or lateral 1/3rd fractures were excluded.

Patients being treated conservatively were treated with a clavicular brace (Figure 1), and an arm pouch was given.

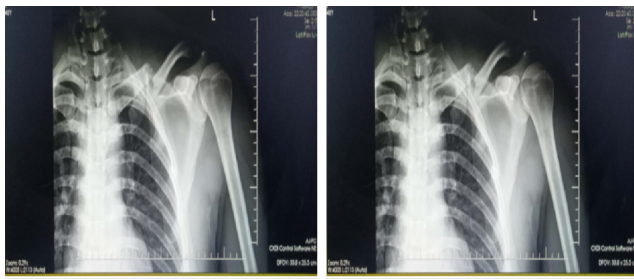

Fig. 1: X-ray of a conservatively treated patient

Patients undergoing surgical fixation were assessed pre-operatively and fitness obtained.

Follow-up was done on 6, 12, and 24 weeks for both conservative and operative cases. The absence of tenderness with no mobility at the fracture site and a bridging callus radiographically were taken as indications of fracture union.

3. Surgical Technique

The patient is kept in a supine position with a large roll placed between the scapula. This allows the injured shoulder girdle to fall posteriorly and helps to restore length increasing the exposure of the clavicle. An supraclavicular nerve is identified and retracted. Clavipectoral fascia is incised along with its attachment. Soft-tissue dissection is carried out and the fracture is reduced and held with bone clamps. A lag screw is used for provisional fixation if required. A 3.5 mm plate is contoured along the anteroinferior edge of the clavicle. The screws for plate fixation are aimed at posteriorly and superiorly.⁷ For Superior Fixation, the plate is contoured along the superior edge of the clavicle (Figure 2) from a superior

to inferior direction. Care must be taken to avoid injury to the neurovascular structures.⁷ Wound closed in layers (Figure 3).

4. Rehabilitation

The limb is immobilized in a sling with the shoulder in adduction and internal rotation. ROM was not started until after suture removal on POD 12 when gentle pendular movements are started. At the end of 6 weeks, gentle active range of motion of the shoulder is allowed and abduction is limited to 80°.

From 6-8 weeks Active to an active-assisted range of motion in all planes are allowed.

At 8-12 weeks: Isometric and isotonic exercises are prescribed to the shoulder girdle muscles.⁸

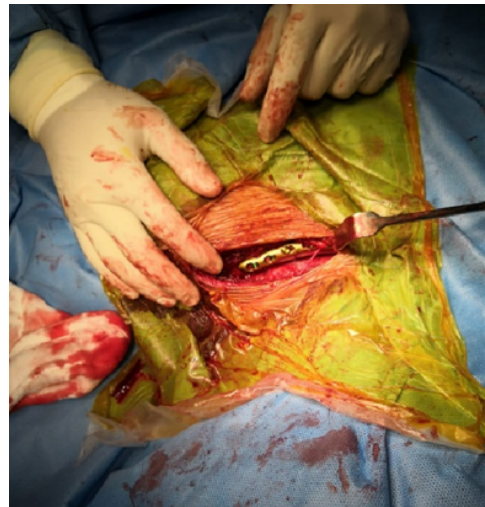

Fig. 2: Application of clavicle plate

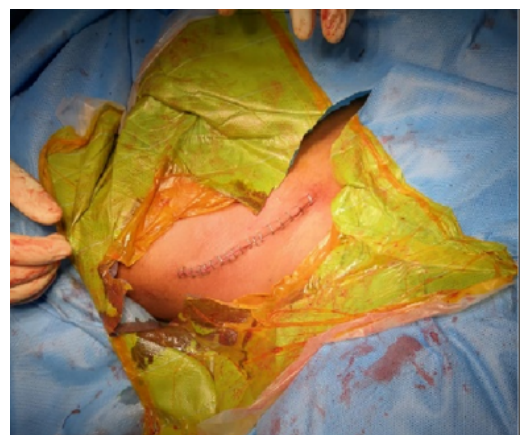

Fig. 3: Wound closure

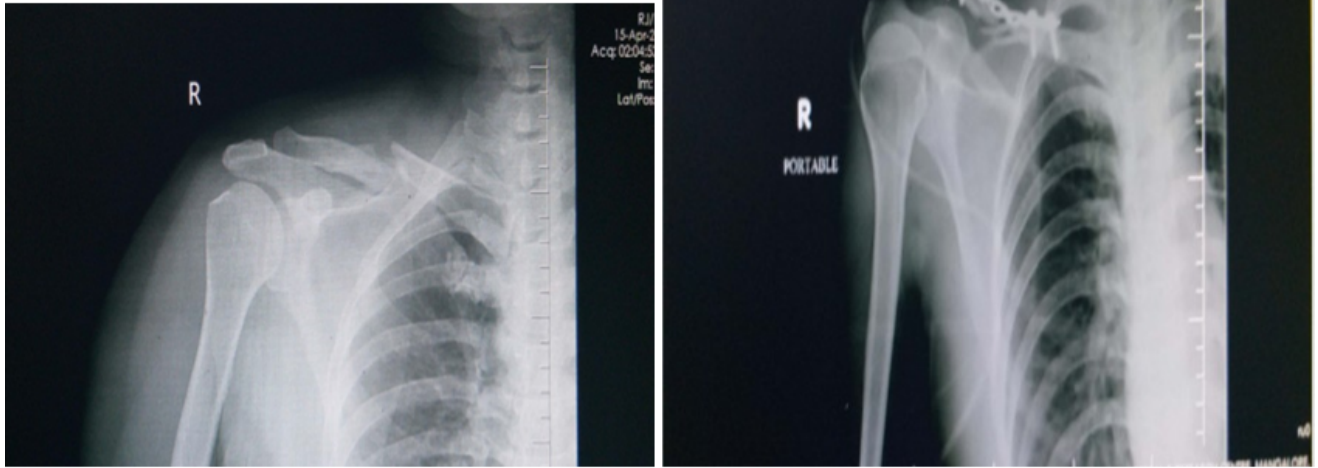


Fig. 4: X-ray of an operated patient

5. Results

The mean age of our patients in this study was 36.9 ± 11.78 years. Patients ranged from 19-80 years old. 35% of patients were between 21-30 years old (Figure 6). The study included 83 male and 17 female patients similar to a study done by Channappa et al.⁹ Our 54 patients sustained the injury due to a road traffic accident and the other 46 with a history of fall. Our study also concluded that radiological union at 12 and 24 weeks was faster in the operative group ($p > 0.05$) (Figure 7). 82% of patients treated operatively had a hospital stay of 4-6 days with 4% of patients staying only for 1-3 days (Table 1).

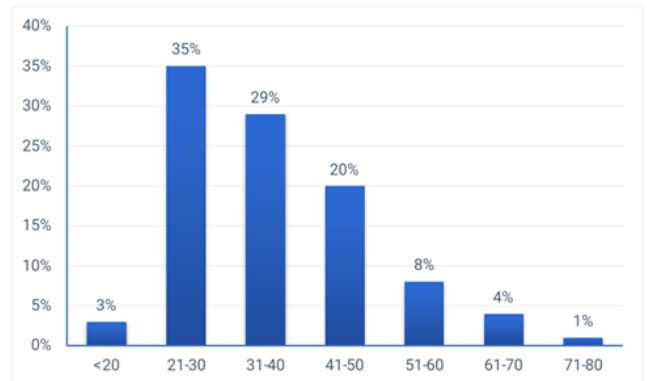


Fig. 6: Mean age of patients

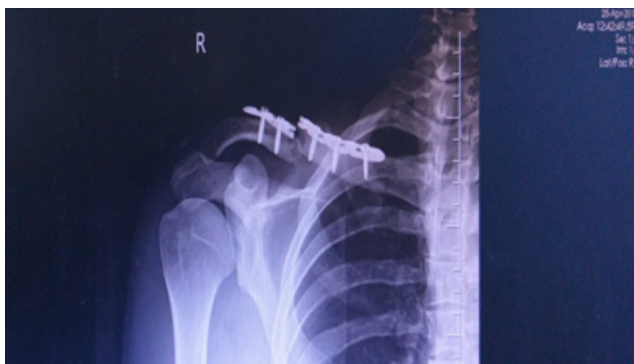

Fig. 5: Plate breakage x-ray (complication)

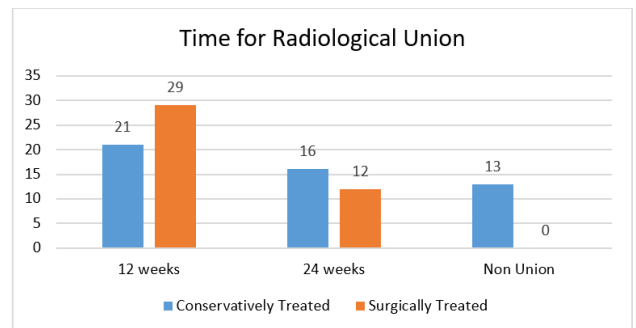


Fig. 7: Time for radiological union

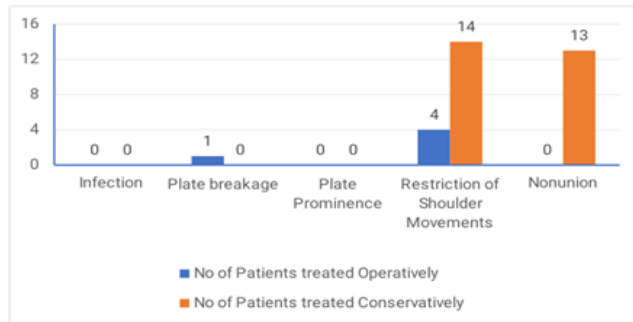
5.1. Complications (Figure 8)

Conservatively treated, 5 patients had complications. Plate breakage (Figure 5) was noted in only 1 patient in the study.

Table 1: Duration of Hospital Stay

Duration of stay (in days) in hospital	Number of patients	Mean	Standard Deviation
1-3	2 (4%)		
4-6	41 (82%)	5.3	1.89
7-10	7 (14%)		
Total	50 (100%)		

In the Operative group, 27 patients had complications but none of them developed non-union. Overall Non-union (13) and restriction of shoulder movements (14) were noted in 54% of the study subjects.

**Fig. 8:** Complications noted

6. Discussion

The argument of ORIF and plating vs. Conservative therapy for a Clavicle shaft fracture has been a matter of debate from time immemorial. Early advocates of conservative treatment soon made way for a concept of surgical fixation of these fractures. In a study by Nischoll et al., he mentions, “It is known that all that is necessary is to support the elbow and brace the shoulders” and that fracture clavicle cannot be effectively immobilized.¹⁰ The fracture of the middle third of the clavicle is given very little importance concerning the pain and disability that they produce, especially during the first three weeks of treatment. It is also not possible to support and immobilize a fracture of the middle third of clavicle in an adult by external means with figure-of-eight bandages.¹¹ Another study of a period of 10 years having fifteen adult patients with clavicular non-unions was evaluated. Initially, these patients were treated with a figure-of-eight bandage, but it was found that it did not provide pain relief or adequate reduction of the fracture. Another study achieved transcortical fixation by using locking Knowles pin for treating hypertrophic nonunion as well as for irreducible acute fractures.¹² A study concluded that although good results with minimal functional deficits have been reported following non-operative treatment of clavicular fractures, surgeon-based methods of assessment may be insensitive to loss of muscle strength. They detected residual deficits in shoulder strength and endurance in their

patient population, which may be related to the significant level of dysfunction detected by the patient-based outcome measures.¹³

Conservatively treated displaced mid third fractures showed that 15% had developed nonunion and 31% reported unsatisfactory results and hence stressed the need for open reduction and internal fixation of severely displaced fractures of the middle third of clavicle in adults.

A study on 868 patients with fracture of clavicle treated nonoperatively showed prevalence of 6.2% nonunion which was higher than previously reported. The risk of nonunion following a diaphyseal fracture of clavicle increased by following factors- lack of cortical apposition, presence of comminution, advancing age and in female gender. These factors when present can be used clinically to counsel the patients about the risk for development of nonunion immediately after the injury.¹⁴

Ramkumar Reddy et al.¹⁵ concluded in their study that the average age group was between 19-39 years (66%) while 2 patients were above the age of 50. The average age was 33.8 years.

A study by Ramesh et al.¹⁶ showed that among 20 patients, 45% were in the age group of 21-30 years. The youngest patient was 19 years and the oldest was 60 years old. This is in accordance with the results noted in our study.

The majority of patients who came to us with a fractured clavicle were caused due to a RTA. This result is similar to numerous studies done by Ramkumar et al.,¹⁵ Mohamed E. Attia et al.,¹⁷ & H. Jiang et al.¹⁸

Radiological outcomes and complication rates were compared between the two groups in our study. The mean time to radiographic union was faster in the operative group than in the non-operative group ($p > 0.05$). There were Zero non-union cases in the operative group compared to 13 in the non-operative group (Figure 7). In a study conducted by TS Channappa et al. the average union time for the operative group was 15.1 weeks and average union time for the conservative group was 20 weeks. The difference was statistically highly significant ($P < 0.001$). Symptomatic mal-union was present in none of the operative group. After one year of injury, the operative-group patients were more satisfied with the appearance of the shoulder and with the shoulder in general than the non-operative group patients.¹³ (Figure 4)

7. Conclusion

As per our study done on 100 patients, the operative group had a lower rate of complications compared to the conservative group. We observed that early primary plate fixation of midshaft clavicle fractures led to improved patient-oriented outcomes and a more rapid return to function and work. Non-union or malunion was not reported in any of the patients who were treated operatively. Patients were more content with the shoulder movements and their appearance following an operative intervention. Hence we conclude that midshaft clavicular fractures treated operatively showed better and faster radiological union as compared to those treated conservatively (Figure 7).

8. Acknowledgements

Our statistician, postgraduates and students who helped with the study.

9. Source of Funding

None.

10. Conflict of Interest

None.

References

1. Postacchini F, Gumina S, Santis PD, Albo F. Epidemiology of clavicle fractures. *J Shoulder Elbow Surg.* 2002;11(5):452–6.
2. Robinson CM. Fractures of the clavicle in the adult. *J Bone Joint Surg Br.* 1998;80(3):476–84.
3. Court-Brown CM, Hj D, McQueen MM, Rw M, T P. Rockwood and green's fractures in adults. In: Walters Kluwer. vol. 111. Wolter Kluwer; 2015. p. 1644.
4. Schiffer G, Faymonville C, Skouras E, Andermahr J, Jubel A. Midclavicular fracture: not just a trivial injury: current treatment options. *Dtsch Arztebl Int.* 2010;107(41):711–7.
5. Ranalletta M, Rossi LA, Piuze NS, Bertona A, Bongiovanni SL, Maignon G. Return to Sports After Plate Fixation of Displaced Midshaft Clavicular Fractures in Athletes. *Am J Sports Med.* 2015;43(3):565–9.
6. Verborgt O, Pittoors K, Glabbeek FV, Declercq G, Nuyts R, Somville J. Plate fixation of middle-third fractures of the clavicle in the semi-professional athlete. *Acta Orthop Belg.* 2005;71:17–21.
7. Azar F, Bj H. Campbells operative orthopaedics. 13th edition. vol. 3. Philadelphia: Elsevier;.

8. Gaudinez RF, Hoppenfeld S. Clavicle fractures. Chapter. In: S H, VL M, editors. Treatment and Rehabilitation of fractures. vol. 10. Lippincott Williams and Wilkins; 2000. p. 73–84.
9. Channappa TS, Radhakrishna AM, Sumanth B, Shivakumar HB. A comparative study of functional outcome of clavicular fractures treated by operative and nonoperative methods. *Int J Orthop Sci.* 2017;3(1):509–14.
10. Nicholl EA. Annotation. Miners and mannequins. *J Bone Joint Surgery (Br).* 1954;36:171–2.
11. Rowe CR. An atlas of anatomy and treatment of midclavicular fractures. *Clin Orthop.* 1968;58:29–42.
12. Connolly JF, Dehne R. Non Union of the clavicle and thoracic outlet Syndrome. *J Trauma.* 1989;29:1127–32.
13. Nonoperative treatment compared with plate fixation of displaced midshaft clavicular fractures. A multicenter, randomized clinical trial. *J Bone Joint Surg Am.* 2007;89(1):1–10.
14. Robinson CM, Court-Brown CM, McQueen MM, Wakefield AE. Estimating the risk of nonunion following nonoperative treatment of a clavicular fracture. *J Bone Joint Surg Am.* 2004;86(7):1359–65.
15. Reddy RK, Rathod J, Rao KT. A study on surgical management of clavicle midshaft fractures by locking plate. *Int J Contemp Med Res.* 2016;3(7):2005–7.
16. Ramesh CG, Chandrashekar HS. Functional outcome of displaced middle third clavicle fractures treated by precontoured locking plate. *Int J Sci Res.* 2016;5(3):731–3.
17. Mohamed EA, Zanfaly AI. Plate fixation in midshaft fracture clavicle. *Egypt Orthop J.* 2014;49:299–303.
18. Jiang H, Qu W. Operative treatment of clavicle midshaft fractures using a locking compression plate: Comparison between mini-invasive plate osteosynthesis (MIPPO) technique and conventional open reduction. *Orthop Traumatol Surg Res.* 2012;98(6):666–71.

Author biography

Suraj Shetty Consultant

Mayur Rai Professor

Shabir Kassim Assistant Professor

Rishabh M Hegde 3rd Year Post Graduate

Shetty Gaurav Kishore 2nd Year Post Graduate

Cite this article: Shetty S, Rai M, Kassim S, Hegde RM, Kishore SG. Radiological union: A study between open reduction and internal fixation vs. conservative treatment of clavicular fractures. *Indian J Orthop Surg* 2020;6(1):30-34.