



Review Article

A short term review of Pipkin fractures type I treated surgically

NVSR Krishna¹, Ch Prathyush^{1,*}, P Prathap¹¹Dept. of Orthopaedics, Lalitha Super Specialty Hospital, Guntur, Andhra Pradesh, India

ARTICLE INFO

Article history:

Received 14-03-2020

Accepted 27-03-2020

Available online 07-07-2020

Keywords:

Pipkin fractures

ABSTRACT

Background: head of femur fractures along with a hip dislocation is a rare & most probably has a poor outcome.

Materials and Methods: In the taken period of 1 yr, we came across nearly twenty cases of Pipkin fracture type I. Through Medical and radiographs evaluation was done and recorded. The followup was done for these selected patients for a period of 12 months. Merle d'Aubigne-Postel score was the score used and recorded the functional outcome of each patient in the study and analyzed.

Results: the cases selected were Pipkin type 1 fracture with dislocation. The time interval between the incident and the successful reduction in the hospital was about 5.6 hrs avg among all the cases. The outcome of the surgically treated cases 8 of them out of 10 showed excellent results clinically and functionally. No complications like AVN and HO or neuro vascular injury was noted in any cases. In our study surgically treated cases showed better results than treated conservatively

Conclusion: Anatomic reduction is must with marginal soft tissue injury. This type I Pipkin fracture better treat surgically than conservative.

© 2020 Published by Innovative Publication. This is an open access article under the CC BY-NC license (<https://creativecommons.org/licenses/by-nc/4.0/>)

1. Introduction

This type of fractures are generally very rare and most probably has a poor functional outcome.¹ Keely & Lipscomb stated that this type of fracture with is 0.000002/yr.² This is one of the emergencies in the orthopaedics and the approach should be very divisive, relocation of the joint must be done as soon as possible under sedation with proper relaxation of muscles to avoid further complications. Immediately after relocation proper, assessment must be done to find any fractures associating to the acetabulum, amount of reduction achieved & any fragments in the joint³ after proper evaluation if all the fragments are in anatomical position it is advised to give conservative treatment in such cases.⁴ If relocation of the joint is not successful then open reduction and internal fixation should be done as early as possible

2. Materials and Methods

In the taken span of one year between January 2019 to January 2020, we had TEN type I Pipkin femoral head fractures. Assessment of TEN patients was done and admitted. All Data of the patients were collected and evaluated radiologically. The follow up was done in all the patients for a period of 12 months classification of Pipkin femoral head fractures type I – Which include only non weight bearing area of the femoral head, type II – this type affects the weight bearing part of the fracture, type III – this may include both type I or II with neck of femur fractures & type IV this includes type I or type II associated with acetabular fracture most commonly effected is fracture of the posterior wall⁵ The evaluation was done using the Merle d'Aubigne-Postel score.⁶ The hip is calculated with this score in three main that's : pain, mobility, and weight bearing, each scores from 0-6 points where 6 is the maximum. Excellent means all three combined score has 18 points, range between 15–17 points is calssified as good,

* Corresponding author.

E-mail address: prathyush.chitithoti@gmail.com (Ch Prathyush).

range between 12-14 points is fair, and that of score <12 points poor shows outcome.

In the cases selected female cases are two, where as male cases were eight. This shows most predominance in males the average age in the individual of the study ranged between 30-59 years, This was not taken into consideration. The main reason for injury is Road Traffic accidents. Reduction of the dislocation of the hip performed short general anesthesia in all the patient as early as possible after admission and all were closed reductions. Ten of the twenty types I Pipkin fracture was treated with open reduction and internal fixation of the fragment with 2 Herbert screws by Smith-Peterson approach (Figure 2), and the rest of the ten were treated conservatively. The total outcome was superb in eight cases treated surgically. One in surgical treated case developed Heterotopic ossifications due to unorthodox massaging done at the village. All the cases were inspected for the range of moments of the hip from the 1 st month of visit permitted partial weight-bearing for surgically treated cases and which was with less pain in surgically treated than the people with conservative treatment. The range of moments in all the surgically treated cases was flexon avg about 85 and only 1 developed limp which is very minimal the abduction is about 20 in all the surgically treated cases and which is a significantly good result than the conservative management.

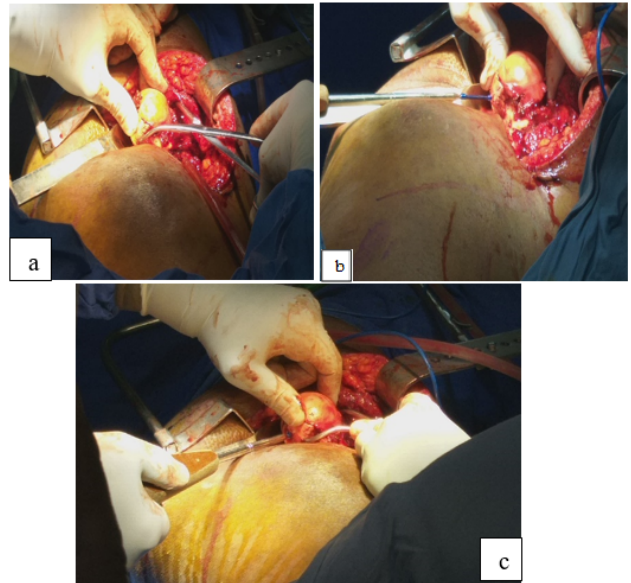


Fig. 2: Showing the reduced fragment and fixing it with Herbert screw; **a):** showing the reduced fragment; **b):** fixing the fragment with screw; **c):** post fixation fragment stability

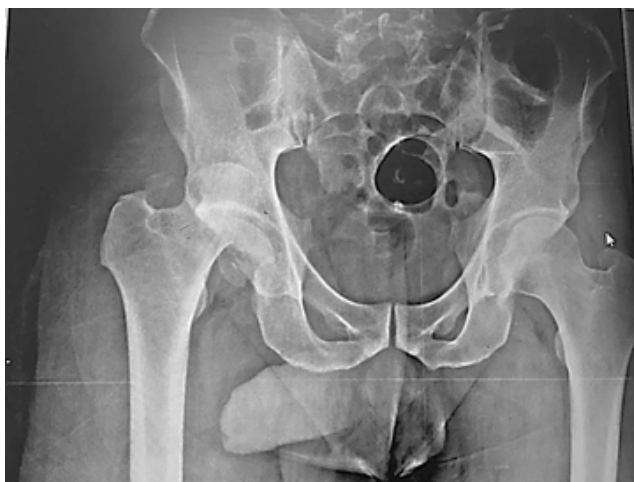

Fig. 1: X-ray showing fracture dislocation with Pipkins fracture

3. Discussion

Time between dislocation & relocation is the key for the best outcome. Epstein et al. indicated reducing as early as possible gives excellent results than reducing lately.⁷ Individuals with Pipkin fractures type I can treated conservatively and surgically depending of the choice of the surgeon. If the fragment is large then open reduction and internal fixation provides good to excellent results.⁸

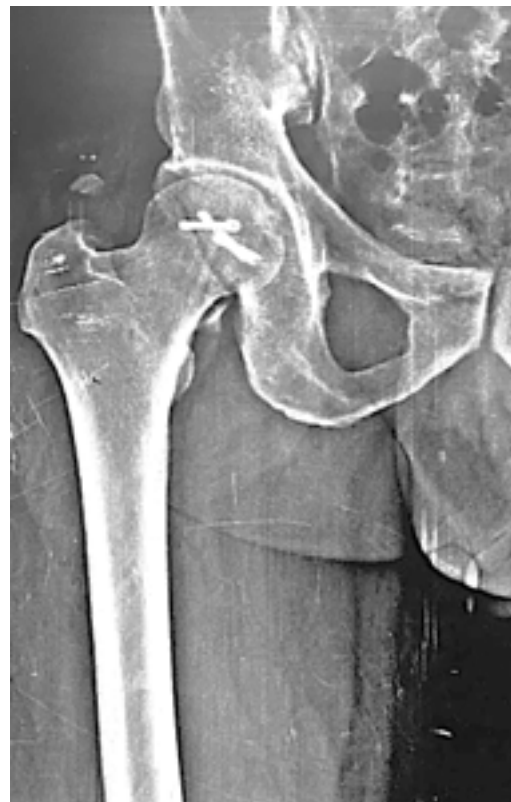

Fig. 3: Showing post op x-ray of the fixation

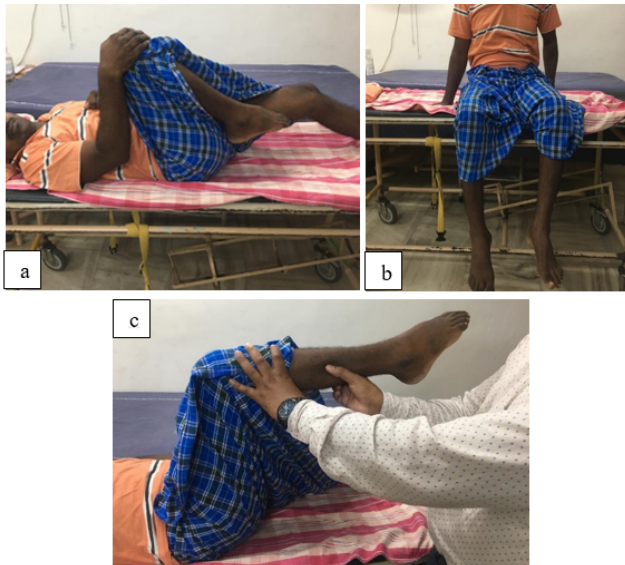


Fig. 4: a,b, &c: Showing the rom of the hip at 12 months visit post-operatively

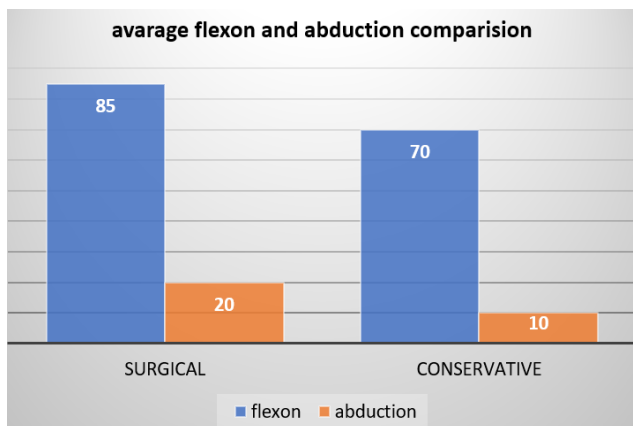


Fig. 5: Showing the out come of the study for range of motion

The reduction must be anatomical to get good result, which is very difficult to achieve in closed manipulation and reduction. Henle et al.⁴ stated that in his study of closed reduction in this type of fractures he got only 1 in 12 anatomical reduction; if the gap of fracture with displacement of > 2 mm, surgical treatment gave best results than conservative. The ideal treatment of this is controversial. Epstein et al.⁹ said to treat traumatic dislocations as emergencies and reducing with numerous attempts is contraindicated. His study showed that initial direct surgical intervention showed good results than treating initially as conservative with delayed surgical intervention. McMurtry & Quaile¹⁰ failure to reduce the joint with in first 6 hrs showed to boost the probability of developing AVN of the head of the femur and also anatomical reduction in initial 4 hrs showed good functional

outcome. The size of the fragment, and position of the fractured fragment also affects the outcome post-operatively. If involving the weight bearing portion the anatomical reduction is the best method to get good outcome.¹¹ Lin et al.¹² showed the value of time for the reduction of the larger fragments and also indicated that surgical treatment should be done to get good outcomes. Surgical excision of small fragments after closed reduction is somewhat useful in treating some fracture of type I Pipkin fractures.¹³ Chakraborti¹⁴ & Butler¹⁵ even if the treatment is hard and time taking conservative is the best treatment for this type of fracture. In some studies Kocher-Langenbeck, in few the Smith-Peterson approach and in few closed reduction and percutaneous fixation can be done for this type of fracture.^{1,7,9,16}

4. Conclusion

The fragments should be reduced anatomically that's the main aim of the surgical intervention with minimal soft tissue injury. No matter the treatment strategy all the patients may develop limp, and in a long-standing study, we can expect the outcome as good in conservative management too which depends mainly on the condition of the patient, severity of the injury, any neurovascular injuries, injury to cartilage, and timing between dislocation and relocation. In our study, it's clear that treating this type I fracture surgically showed better results than the cases treated conservatively in all aspects of early mobilization to the range of moments & further more time has to be taken to find out the long term results.

5. Source of Funding

None.

6. Conflict of Interest

Authors had no conflict of interest to disclose.

References

1. Stannard JP, Harris HW, Volgas DA, Alonso JE. Functional Outcome of Patients With Femoral Head Fractures Associated With Hip Dislocations. *Clin Orthop Relat Res*. 2000;377:44–56.
2. Kelly PJ, Lipscomb PR. Primary Vitallium-Mold Arthroplasty for Posterior Dislocation of the Hip with Fracture of the Femoral Head. *J Bone Joint Surg*. 1958;40(3):675–80.
3. Moed BR, Maxey JW. Evaluation of fractures of the femoral head using the CT-directed pelvic oblique radiograph. *Clin Orthop Relat Res*. 1993;296:161–7.
4. Henle P, Kloen P, Siebenrock KA. Femoral head injuries Which treatment strategy can be recommended? *Inj*. 1993;38:478–88.
5. Pipkin G. Treatment of Grade IV Fracture-Dislocation of the Hip. *J Bone Joint Surg Am*. 1957;39(5):1027–42.
6. Ugino FK, Righetti CM, Alves DPL, Guimarães RP, Honda EK. Evaluation of the reliability of the modified Merle d'Aubigné and Postel Method. *Acta Ortop Bras*. 2012;20:213–7.
7. Epstein HC. Traumatic dislocations of the hip. *Clin Orthop Relat Res*. 1973;p. 116–42.

8. Park KS, Lee KB, Na BR, Yoon TR. Clinical and radiographic outcomes of femoral head fractures excision vs. fixation of the fragment in Pipkin type I what is the optimal choice for a femoral head fracture? *J Orthop Sci.* 2015;20:702–7.
9. Epstein HC, Wiss DA, Cozen L. Posterior Fracture Dislocation of the Hip with Fractures of the Femoral Head. *Clin Orthop Relat Res.* 1985;201:9–17.
10. McMurtry IA, Quaile A. Closed reduction of the traumatically dislocated hip: a new technique. *Inj.* 2001;32(2):162–4.
11. Lederer S, Tauber M, Karpik S, Bogner R, Auffarth A. Fractures of the femoral head. A multicenter study. *Unfallchirurg.* 2007;110:513–20.
12. Lin D, Lian K, Chen Z, Wang L, Hao J. Emergent surgical reduction and fixation for Pipkin type I femoral fractures. *Orthopedics.* 2013;36:778–782.
13. Chen ZW, Lin B, Zhai WL, Guo ZM, Liang Z. Conservative versus surgical management of Pipkin type I fractures associated with posterior dislocation of the hip: a randomized controlled trial. *Int Orthop.* 2011;35:1077–81.
14. Chakraborti S, Miller IM. Dislocation of the hip associated with fracture of the femoral head. *Inj.* 1975;7(2):134–42.
15. Butler JE. Pipkin Type-II fractures of the femoral head. *J Bone Jt Surg.* 1981;63(8):1292–6.
16. Rajagopal TS, Kanse P. Percutaneous Fixation for Pipkin type II Femoral head fracture associated with posterior dislocation of the hip.; 2003.

Author biography

NVSR Krishna HOD

Ch Prathyush Senior Resident

P Prathap Senior Resident

Cite this article: NVSR Krishna , Ch Prathyush , Prathap P. A short term review of Pipkin fractures type I treated surgically. *Indian J Orthop Surg* 2020;6(2):54-57.