



Case Report

Aggressive lytic lesion of lesser trochanter proximal femur in an eighteen year old male - A case report

Lavindra Tomar¹, Gaurav Govil^{1,*}, Pawan Dhawan¹

¹Dept. of Orthopaedics, Max Super Speciality Hospital, Patparganj, New Delhi, India



ARTICLE INFO

Article history:

Received 27-04-2020

Accepted 28-04-2020

Available online 07-07-2020

Keywords:

Aneurysmal bone cyst

Expansile lytic cyst

Lesser trochanter tumour

Proximal femur

ABSTRACT

Aneurysmal bone cyst (ABC) is an osteolytic benign tumour, which is usually situated in the metaphysis of long bones and mostly encountered in patients younger than 20 years old. Common treatment modalities include arterial embolization, curettage, intralesional injections and en-bloc resection with instrumentation. We present a case of an eighteen-year old male with an ABC involving lesser trochanter of left femur with impending pathological proximal femur fracture. We discuss treatment modalities and clinical outcome in our case.

© 2020 Published by Innovative Publication. This is an open access article under the CC BY-NC license (<https://creativecommons.org/licenses/by-nc/4.0/>)

1. Introduction

Aneurysmal bone cyst (ABC) amongst cystic lesions is still an enigma for an orthopaedic surgeon. Although first described in 1942 by Jaffe and Lichtenstein, the true aetiology and optimum line of treatment is still unknown.¹⁻³ The incidence in the general population is 0.14/100,000 inhabitants with the peak incidence recorded in the second decade of life typically affecting the metaphysis of long bones.¹⁻³ Although considered benign, radiologically it can be locally aggressive.^{2,4} ABC can be either primary or secondary to other underlying pathologies which adds to the challenge in ABC diagnosis.¹⁻³ Several ABC treatment modalities had been utilized with variable risk of recurrence.^{1,3-5}

We present a case of eighteen-year old boy with aggressive lytic lesion of lesser trochanter femur with impending pathological fracture with its unique challenges for management to achieve favourable outcome.

2. Case Presentation

An eighteen-year-old boy presented to us with complaints of pain in left hip region since last 3 months with difficulty in walking and no relief on pain killers. The pain was insidious in onset, mild to moderate in intensity and did not show any radiation or any diurnal variation. Examination revealed tenderness along groin region and attempts to move left hip are resisted. There was no shortening of left lower limb, however antalgic gait was present. Radiographs of pelvis with both hips (Figure 1) revealed a well-defined, homogenous eccentric expansile lytic lesion in the region of the left upper femoral metaphysis in region along lesser trochanter. The cortex surrounding the lesion had been thinned out. Computer tomography (CT) hip (Figure 2 a,b,c,d) showed an expansile lytic lesion along lesser trochanter lesion with no septa. Thinning of medial cortex of femur along lesser trochanter was present. Magnetic Resonance Imaging (MRI) (Figure 3 a,b) revealed signal changes with lesion involving antero-medial aspect of lesser trochanteric region of femur with cortical ballooning without breach involving around half of femoral lesser trochanter. The lesions showed a low signal on T1W and high signal on T2W weighted images. CT guided fine needle

* Corresponding author.

E-mail address: gauravgovil@yahoo.co.in (G. Govil).

aspiration biopsy was done which was conclusive.

As the patient was young, removal of tumour and restoring the function was essential. The surgery was done via the anterior approach. After exposure, an elliptical cortical window along longest longitudinal dimension of the tumour was made and curetted material showed blood filled lining of cyst wall (Figure 4 a,b). Extended curettage by high-speed burr drilling was done to achieve an extended clearance of lesion. Alcoholic cyst cauterization and biological reconstruction of the defect with autologous ipsilateral non vascularized fibular strut graft and cortico-cancellous ipsilateral iliac graft along the medial femoral defect was done. Synthetic bone substitutes of calcium phosphate ceramics added to obliterate residual empty spaces. Prophylactic nailing was done with AO antegrade de-rotation proximal femoral nailing (Figure 5a,b). Histopathological examination of the lesion revealed aneurysmal cystic lesion.

Post-surgery the patient was able to mobilize non weight bearing. At 6 months patient was walking without any aid. Serial radiological assessment showed healing of the cyst with consolidation. At 24 months the patient had no pain, walks unaided, no avascular necrosis or coxa-vara were detected. There were no signs of recurrence.

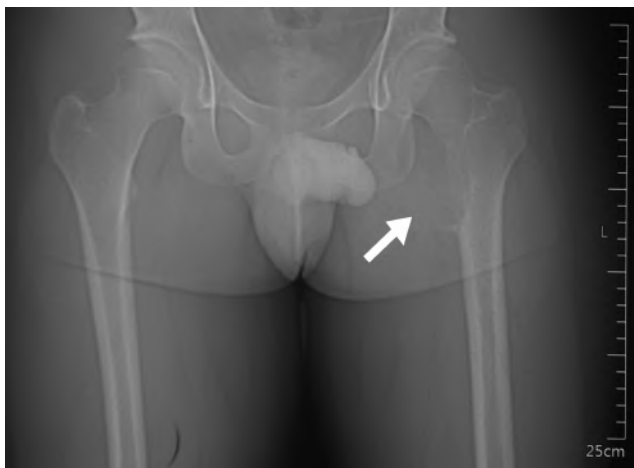


Fig. 1: Radiograph of pelvis with both hips anteroposterior view shows an eccentric expansile lytic lesion marked with white arrow in the proximal femoral metaphysis of lesser trochanter left hip

3. Discussion

Lesions that occur in the proximal femur are potentially more challenging as they carry a high risk of pathological fractures, biomechanical stress and rate of recurrence. ABC are actually mass of vascular spaces encased within periosteal new bone. ABCs are rare, accounting for 1-6% of all the primary bone neoplasms.² It commonly presents in the first two decades with slight female predominance unlike our case who is a male.^{1,2,4,5} Main sites are the

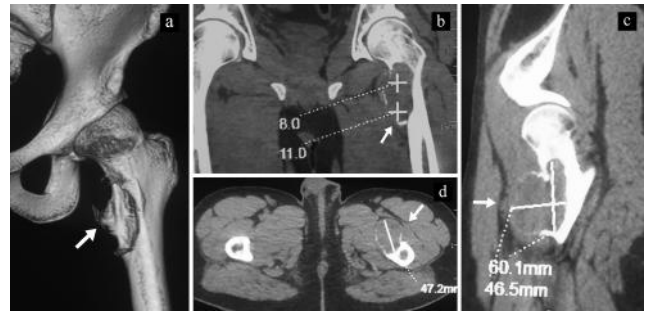


Fig. 2: CT reconstruction hip delineates expansile lytic bone cyst, white arrow showing thinned cortex in 2a, medial femoral orientation of cyst on sagittal view in 2b, ballooning of cortex in 2c and 2d

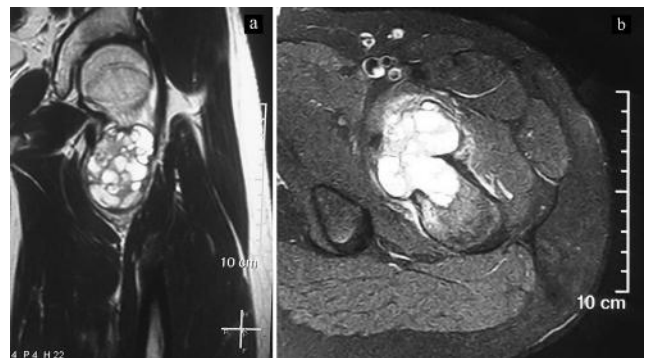


Fig. 3: MRI of the hip shows area of signal changes involving lesser trochanter affected by well demarcated expansile lytic bone cyst on sagittal view in 3a and perilesional oedema with soft tissue displacement on axial view in 3b

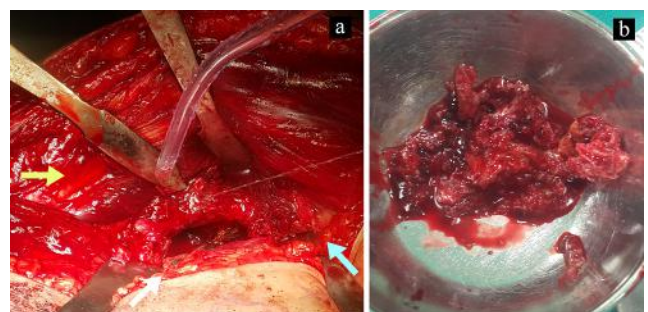


Fig. 4: Intra-operative clinical photographs shows the macroscopic appearance of the lesion with yellow arrow on hip, blue arrow on thigh and white arrow for elliptical window created on medial femur in 4a and the curetted material in 4b.

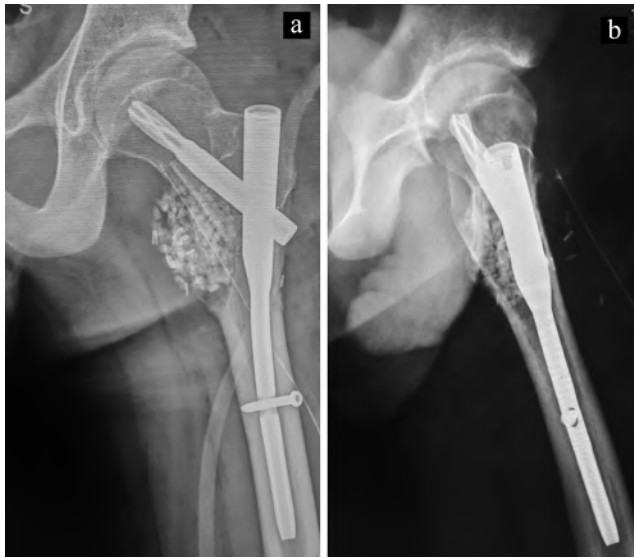

Fig. 5: Post-operative radiograph following curettage of the cyst, with in situ fibular strut graft, calcium phosphate granules and proximal femoral nail in anteroposterior view in **5a** and lateral view in **5b** image

femur, tibia, humerus, spine, and pelvis however lesser trochanter femur is an uncommon site.^{1,4} The tumours are usually metaphyseal and eccentric with unknown aetiology consistent with our case. Most of the lesions arise de novo and are termed as ‘Primary ABCs’. They may also arise in conjunction with other lesions viz. fibrous dysplasia, osteoblastoma etc and designated as ‘Secondary ABCs’.² The short duration of complaints, no known underlying cause indicated an aggressive progression of the lesion presumably a primary ABC. Radiographically, lytic expansile lesion presents with cortical thinning and MRI shows septation with fluid level as noted with our patient too.^{1,4} The affected bone characteristically appears cystic and ballooned outward. Incisional biopsy is the current standard of diagnosis with fine needle aspiration giving few positive results.¹

The optimal treatment for ABC’s is debatable.^{4,5} Several ABC treatment modalities had been utilized including wide resection, intralesional resection, curettage with or without different adjuvants, radiation, curettage, embolization, intralesional sclerotherapy,^{1,3-5} and more recently denosumab^{2,4} with variable risk of recurrence.^{1,3-5} Aggressive surgical management for lesions involving at least 50% of the bony cortex of the proximal femur, painful tumours and impending pathological fracture is needed. Treatment aims to stop extension of the lesion, prevent pathological bone fractures, reduce relapse, and most importantly, stop pain.⁴ In spite of the number of techniques reported in the literature, there remains a recurrence rate that ranges from 5% to greater than 40%.^{4,5} Procedures such as curettage with or without bone marrow injection, and bone

grafting are the most commonly used treatment options.^{1,2} Currently, less invasive treatments are more commonly used.^{1,2} There is more risk to neurovascular bundle along lesser trochanter femoral region with less invasive treatment options than an open procedure. An en-bloc resection advocated for aggressive tumour have low recurrence rate but high morbidity.^{1,4,5} Complex vascular anatomy of the hip as well as difficulty in full exposure of the lesion renders surgical management of lesser trochanter tumours a rather challenging procedure.³ The proper selection of the treatment option and surgical approach is a cornerstone in management.

We used open surgical procedure with anterior approach which provided an accessible surgical field with direct visualization of the neurovascular structure, enough to perform complete exposure of the femoral head and neck without the need for surgical dislocation and adequate curettage of neoplastic tissue. Prophylactic fixation is considered to prevent the further propagation of an impending pathological fracture with either an intramedullary or an extramedullary device after curettage. Proximal antegrade derotation nail as an intramedullary device gives a load sharing construct allowing for early rehabilitation. Non-vascularized fibular strut grafts along with autologous cancellous iliac crest graft along with bioactive bone substitute granules was considered adequate to pack the defect for reconstruction. It provides for sufficient biomechanical strength once it heals into its bed.⁵ At two years follow up, there were no graft failure or recurrence noted.

For a lesser trochanter femoral lesion, extended curettage and reconstruction with graft substitutes and prophylactic nailing represents a recommended approach with good to excellent functional results. A longer follow up for late recurrences is recommended.

4. Source of Funding

None.

5. Conflict of Interest

None.

6. Ethical Approval

We declare that it is a retrospective case report. No ethical approval taken.

References

1. Park HY, Yang SK, Sheppard WL, Hegde V, Zoller SD, Nelson SD, et al. Current management of aneurysmal bone cysts. *Curr Rev Musculoskeletal Med.* 2016;9(4):435–44.
2. Sharma S, Gupta N, Salaria A, Singh R. Aneurysmal bone cyst: An unusual cause of pathological intertrochanteric fracture in an eight-year old boy. *Internet J Orthop Surg.* 2007;8(2).

3. Rahman MA, Masry AME, Azmy SI. Review of 16 cases of aneurysmal bone cyst in the proximal femur treated by extended curettage and cryosurgery with reconstruction using autogenous nonvascularized fibula graft. *J Orthop Surg.* 2018;26(2):1–6.
4. Ulici A, Sterian AG, Tevanov I, Carp M, Dusca A, Cosma D. Aggressive development of an aneurysmal bone cyst of the proximal femur in a paediatric patient: a case report. *J Int Med Res.* 2018;46(1):538–45.
5. Kapoor C, Shah M, Soni R, Patwa J, Merh A, Golwala P. Aneurysmal Bone Cyst of the Proximal Femur and Its Management - A Case Report. *Cureus.* 2017;9(1):e991.

Author biography

Lavindra Tomar Director and Unit Head

Gaurav Govil Senior Consultant

Pawan Dhawan Attending Consultant

Cite this article: Tomar L, Govil G, Dhawan P. Aggressive lytic lesion of lesser trochanter proximal femur in an eighteen year old male - A case report. *Indian J Orthop Surg* 2020;6(2):128-131.