



## Case Report

# Subtotal Claviclectomy for aneurysmal bone cyst of clavicle: A case report and review of literature

Ritabh Kumar<sup>1</sup>, Pushkar Chawla<sup>1</sup>, Sumit Kumar<sup>1,\*</sup>

<sup>1</sup>Dept. of Orthopaedics and Traumatology, Indian Spinal Injuries Centre, New Delhi, India



## ARTICLE INFO

### Article history:

Received 01-05-2020

Accepted 21-05-2020

Available online 07-07-2020

### Keywords:

Aneurysmal bone cyst

Clavicle

Claviclectomy

## ABSTRACT

Aneurysmal bone cysts are benign, locally aggressive osteolytic neoplasms that usually affect individuals in their second decade. Majority of aneurysmal bone cysts occur in metaphysis of long bones and vertebra. Clavicle is an uncommon location and only few cases have been reported in literature. We present a case of 17 year old male who presented with gradually progressive painful swelling in left shoulder region. X-ray and CT scan showed expansile osteolytic swelling. Excision of the lesion with subtotal claviclectomy was done. On follow up, patient was able to perform his daily activities without any restriction and no recurrence was noted on ten year follow up.

© 2020 Published by Innovative Publication. This is an open access article under the CC BY-NC license (<https://creativecommons.org/licenses/by-nc/4.0/>)

## 1. Introduction

Aneurysmal bone cyst (ABC) is a locally destructive blood filled reactive lesion of bone and are not considered to be true neoplasms. Most occur in patients younger than 20 years old.<sup>1</sup> These tumours are usually metaphyseal and are eccentrically located. Any bone may be involved but the most common locations include the proximal humerus, distal femur, proximal tibia and spine.<sup>1</sup> Clavicle is an unusual location for ABC with very few cases reported in literature.<sup>2,3</sup> We report a case of ABC of clavicle in a young male managed with subtotal claviclectomy with no recurrence and no functional disability over 10 year follow up.

## 2. Case Report

A 17 year old male presented with complaints of gradually increasing swelling in left clavicular region for five months. It was painless and not associated with any motor weakness or sensory symptoms in left upper limb. Examination revealed a non-tender, fixed bony hard swelling measuring six by four centimeter that was continuous with clavicle

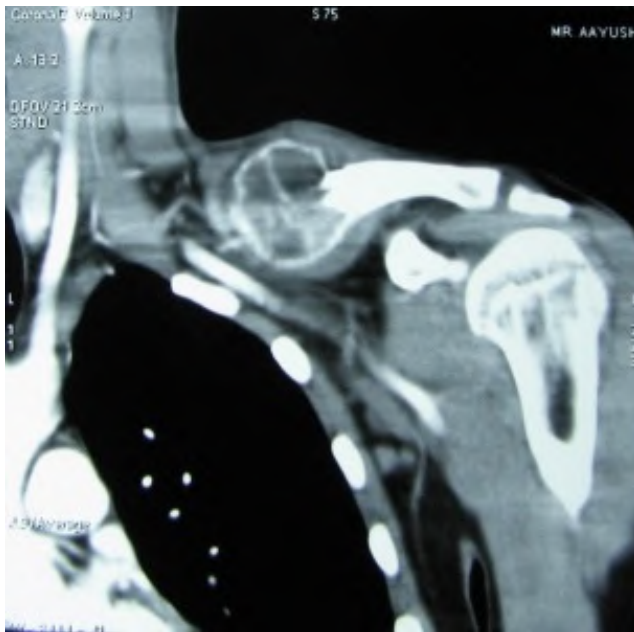on either side. Overlying skin was normal, non-adherent to swelling and transillumination was negative. No other swelling was noted. Systemic examination was normal.

After examination, radiograph and CT scan with 3D reconstruction of the involved area was done. X-ray revealed an expansile, osteolytic lesion in middle third of the left clavicle. On CT scan, a thin-walled multiloculated expansile lesion was noted in the diaphyseal region of the left clavicle (Figures 1 and 2). There was no soft tissue extension. FNAC was inconclusive.

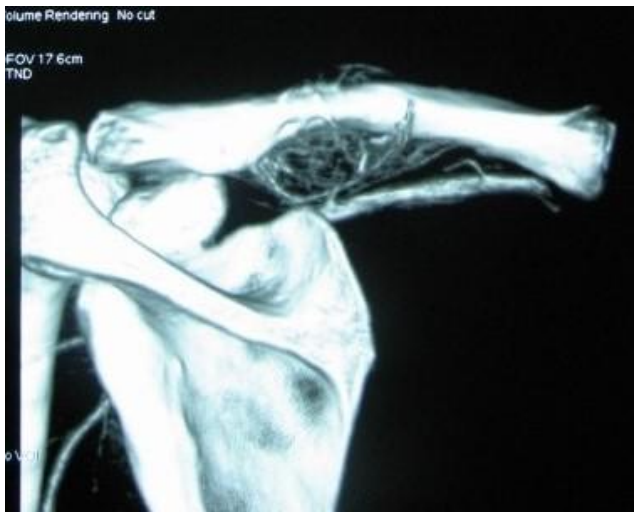Provisional diagnosis of aneurysmal bone cyst was made and excisional biopsy was planned. Written informed consent for the surgery was obtained from the parents of the patient. Written Consent was also obtained for taking images and publishing the information. Subtotal claviclectomy was performed under general anesthesia. A 12 cm long curvilinear incision following the contour of clavicle was given to expose the bone. Careful blunt dissection was carried out and en-bloc resection of tumour along with normal margins of bone was done leaving three cm of medial and two cm of lateral end of the clavicle intact (Figures 3, 4 and 5). Wound was thoroughly irrigated and closure done in layers. Post-operative recovery was uneventful and patient was given

\* Corresponding author.

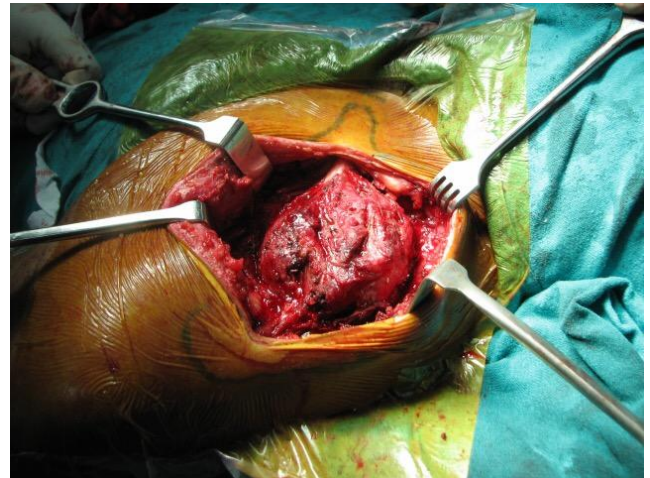
E-mail address: [drsumit26@gmail.com](mailto:drsumit26@gmail.com) (S. Kumar).



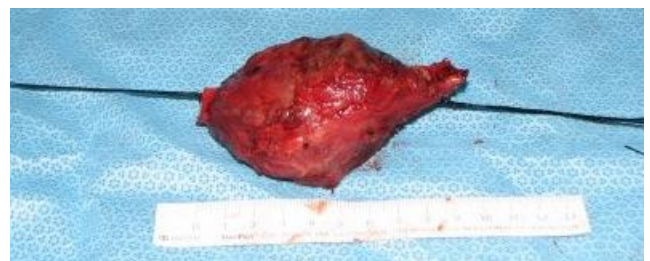**Fig. 1:** Pre-operative CT scan image



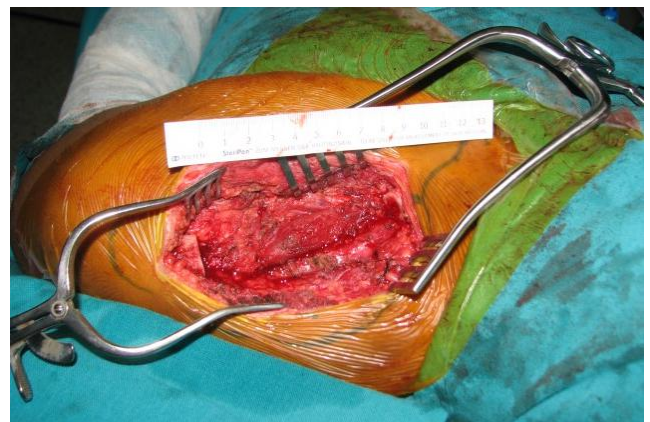
**Fig. 2:** Pre-operative 3D CT scan image



**Fig. 3:** Intraoperative image showing tumour in situ

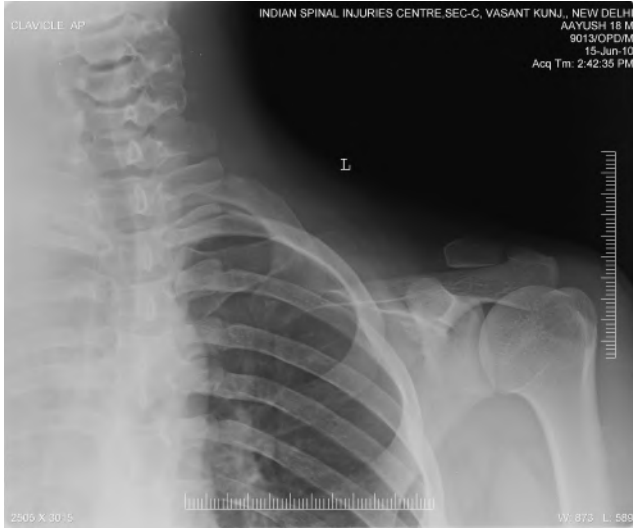


**Fig. 4:** Intraoperative image showing removed tumour along with clavicle

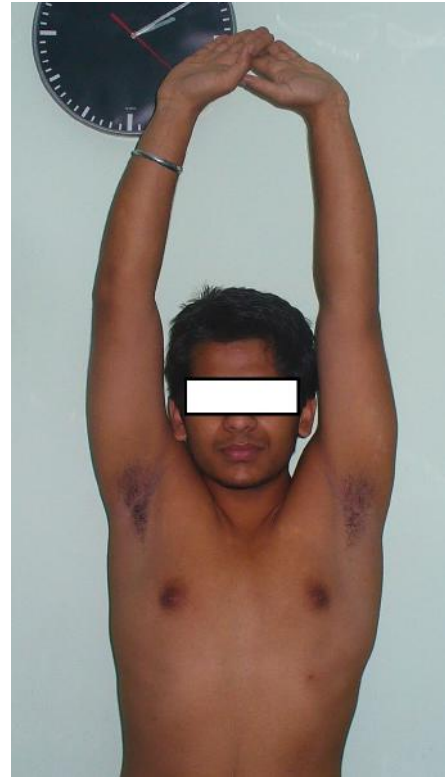

**Fig. 5**

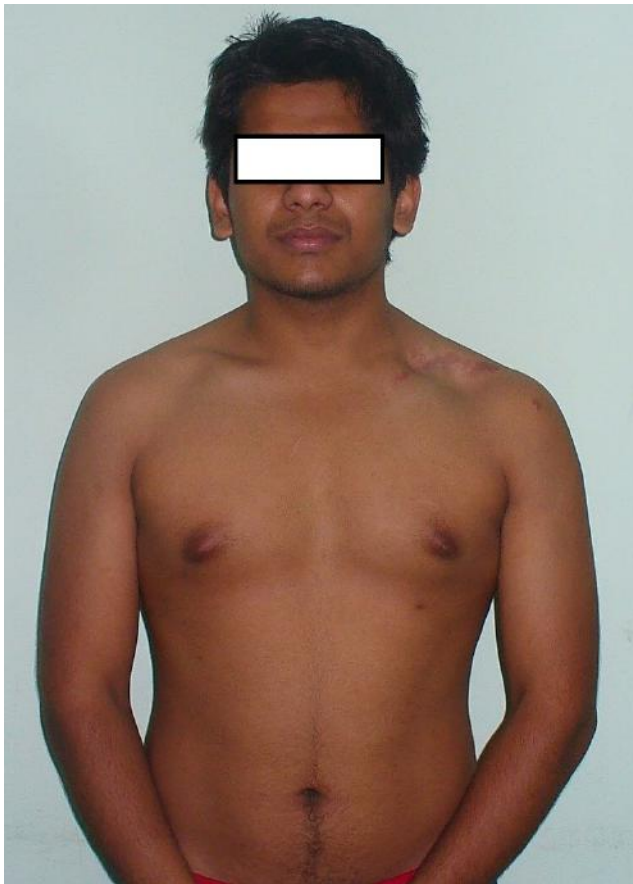immobilizer for four weeks. Gradual mobilization was started and patient returned to normal activities after three months. Histopathological examination of the lesion showed cystic blood filled spaces separated by fibrous septa, confirming the diagnosis of aneurysmal bone cyst. DASH score (Disability of arm, shoulder and hand) was used to evaluate the function of the limb. Patient had normal shoulder movements and no restrictions in day to day activities over ten year follow up and no recurrence of lesion was noted (Figures 6, 7, 8 and 9).



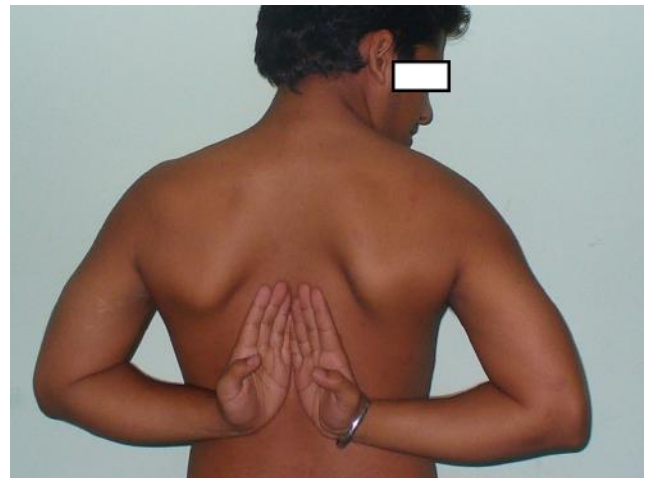**Fig. 6:** Post-operative radiograph (after 10 years)



**Fig. 8:** Showing range of shoulder movements ten years after surgery



**Fig. 7:** Showing range of shoulder movements ten years after surgery



**Fig. 9:** Showing range of shoulder movements ten years after surgery



### 3. Discussion

Aneurysmal bone cyst (ABC) is a benign tumour commonly involving metaphyseal region of long bones. Clavicle is an uncommon site of aneurysmal bone cyst. Till 2015 only 62 cases of ABC in clavicle have been reported in literature. In a case series of 465 cases of ABC, only 3% cases were reported in Clavicle.<sup>4</sup> Kaiser et al. in 2019 presented the largest series of 13 cases of ABC of clavicle.<sup>2</sup> Most common site of ABC of clavicle is acromial end. Kaiser et al. reported 77 % cases in lateral third of clavicle.<sup>2</sup> In our case ABC is in diaphysis which is very rare. Smith et al. reported five out of six clavicular ABCs arising in the acromial end.<sup>5</sup>

Most of the ABCs arise in second decade of life. However cases have been reported much later in life. Smith et al. reported 2 cases at 61 and 63 years respectively.<sup>5</sup>

Most common presenting symptom of ABC is pain or swelling or both. Swelling gradually increases which may vary in duration from weeks to several years.

On X-ray, it is seen as eccentric, expansile osteolytic lesion with paper thin shell of sub-periosteal bone. In some cases, characteristic pattern of soap bubble appearance has been reported. CT scan shows more details in comparison to plain radiographs such as size of lesion and its extension. The classic pattern of fluid-fluid level is seen in some patients and represents sedimentation of RBCs in hemorrhagic cavities. This feature is more prominently seen in MR Imaging.<sup>6</sup>

Differential diagnosis of ABC includes Giant cell Tumour, Chondromyxoid fibroma and Telangiectatic osteosarcoma. Giant cell tumour usually presents in skeletally mature individuals with a peak incidence in third decade of life. It is less polycystic and seldom grows as rapidly as aneurysmal bone cyst. Chondromyxoid fibroma is a rare tumour that presents more commonly in males in second and third decade. It is found nearly always in lower limb. X-ray feature often confuse with aneurysmal bone cyst, however, histological appearance of mixture of fibrous, myxomatous and chondroid tissue helps in differentiation. Telangiectatic osteosarcoma clinically and radiologically resembles Aneurysmal bone cyst. On histopathology, presence of pleomorphic, hyperchromatic cells with nuclear anaplasia in combination to osteoid matrix is highly characteristic of osteosarcoma.

The best modality of treatment for ABC is still debated. Various methods of treatment include curettage, curettage with reconstruction with graft or cement, resection, radiotherapy, adjuvants like cryotherapy and phenol and vascular occlusion. Curettage with reconstruction of defect with bone graft/ bone cement is the mainstay of treatment in ABC but recurrence rate may vary from 20-70% within 2 years.<sup>3,7</sup> Cottalorda et al. reported 31% recurrence rate. Marcove et al. reported a lowest recurrence with curettage and cryotherapy.<sup>7</sup> Radiotherapy is used in cases

that cannot be operated because of their location and to prevent damage to the function of important structures. Arterial embolization of the feeding vessels has been used as definitive treatment in location where curettage would be extremely difficult. In locations such as pelvis and spine, embolization helps to decrease vascularity making the surgical procedure less bloody. Wide resection is associated with lowest risk of recurrence. Studies have shown that patients undergoing wide resection report 95-100 % local control and no relapses.<sup>8</sup> However, it is often avoided due to issue of functional impairment such as muscle weakness and decreased range of motion and need for reconstruction. The clavicle has five main functions, a) to meet the need for cosmesis, b) to protect the subclavian structure, c) to act as the attachment of the musculature, d) to act as a strut supporting the scapula, and e) to maintain the limb function. In our case, the options of treatment were curettage with bone graft or wide resection of lesion. Many studies have shown that there is good shoulder function after total or subtotal claviclectomy. Wessel et al. in their study outcome reported full range of motion of shoulder after total claviclectomy in six cases.<sup>9</sup> Similarly Krishnan et al. in their series of six cases found normal range of motion after total claviclectomy. Several authors suggested that clavicular reconstruction following total and subtotal claviclectomy is imperative to prevent shoulder instability, abnormal scapular motion, chronic shoulder joint damage, weakness, pain, an unsightly appearance and injury to the subclavian structure. However, Chen et al in 2017 in their study suggested no better outcome with clavicular reconstruction than isolated total claviclectomy.<sup>10</sup> Wood in his study of five cases also proposed that removal of total clavicle result in good function of shoulder. But if trapezius muscle is paralysed, removal of clavicle is hazardous.

Given the size of lesion and resection being a viable option, subtotal claviclectomy was done in the above patient. On regular follow up over a period of ten years, there was no disability to the patient and no recurrence was found.

### 4. Conclusion

Although rare, aneurysmal bone cyst should always be kept as differential diagnosis when dealing with a clavicular swelling. Total or subtotal claviclectomy in such benign aggressive tumours gives no or very limited functional disability and minimizes chances of recurrence of tumour, thus making it the treatment of choice.

### 5. Source of Funding

None.

### 6. Conflict of Interest

None.

## References

1. Heck RK, Toy PC. Benign bone tumours and nonneoplastic conditions simulating bone tumours. In: Campbell's operative orthopaedics. Philadelphia: Mosby Elsevier; 2013. p. 875–6.
2. Kaiser CL, Yeung CM, Raskin KA, Lozano-Calderon SA. Aneurysmal bone cyst of the clavicle: a series of 13 cases. *J Shoulder Elbow Surg*. 2019;28(1):71–6.
3. Chadha M, Singh AP. Aneurysmal bone cyst of the clavicle. *Can J Surg*. 2008;51:32–3.
4. Yashavnta KC, Nalini KB, Menon J, Patro DK. Aneurysmal Bone Cyst of Medial End of Clavicle in a Child, a Rare Case Report. *Indian J Surg Oncol*. 2014;5(2):158–60.
5. Smith J. Aneurysmal bone cyst of clavicle. *Br J Radiol*. 1977;50(598):706–9.
6. Hudson TM. Fluid levels in aneurysmal bone cysts: a CT feature. *AJR Am J Roentgenol*. 1984;142:1001–4.
7. Marcove RC, Sheth DS, Takemoto S, Healey JH. The treatment of aneurysmal bone cyst. *Clin Orthop Relat Res*. 1995;311:157–63.
8. Campanacci M, Capanna R, Picci P. Unicameral and Aneurysmal Bone Cysts. *Clin Orthop Rel Res*. 1986;204:25–36.
9. Wessel RN, Schaap GR. Outcome of total claviclectomy in six cases. *J Shoulder Elbow Surg*. 2007;16(3):312–5.
10. Chen Y, Yu X, Huang W, Wang B. Is clavicular reconstruction imperative for total and subtotal claviclectomy? A systematic review. *J Shoulder Elbow Surg*. 2018;27(5):141–8.

## Author biography

**Ritabh Kumar** Senior Consultant

**Pushkar Chawla** Senior Consultant

**Sumit Kumar** Fellow

**Cite this article:** Kumar R, Chawla P, Kumar S. Subtotal Claviclectomy for aneurysmal bone cyst of clavicle: A case report and review of literature. *Indian J Orthop Surg* 2020;6(2):132-136.