



## Original Research Article

## Comparative analysis of the functional outcome in intertrochanteric fractures between dynamic hip screw and proximal femoral nailing - A prospective study

R Sahaya Jose<sup>1,\*</sup>, K Visnu<sup>1</sup>, K Vivek<sup>1</sup>, R Manikandan<sup>1</sup>

<sup>1</sup>Dept. of Orthopaedics, Sree Mookambika Institute of Medical Sciences, Kanyakumari, Tamilnadu, India



## ARTICLE INFO

## Article history:

Received 04-09-2020

Accepted 11-09-2020

Available online 19-09-2020

## Keywords:

Dynamic hip screw

Intertrochanteric fracture

Proximal femoral nailing

Harris Hip Score

Boyd and Griffin's classification

## ABSTRACT

**Background and Objectives:** The aim of this study is to assess the functional outcome of dynamic hip screw and Proximal Femoral Nailing in intertrochanteric fractures using Harris hip score.

**Materials and Methods:** In our prospective study, we compare the functional outcome in intertrochanteric fractures between dynamic hip screw and proximal femoral nailing. 70 patients with Intertrochanteric fracture femur were included in this study. 35 patients were treated with DHS and 35 patients with PFN, respectively. In both the groups, patients were evaluated for postoperative functional outcome by using Harris hip score. The Data was analyzed by SPSS 16.00 version. Unpaired t test applied to find the statistical significance between the groups. P value less than 0.05 is considered statistically significant.

**Results:** Our results show dynamic hip screw has 14.29% of excellent results, whereas proximal femoral nailing has 40% excellent results. Among 70 patients with intertrochanteric fractures, patients developed less complication in PFN group (20%) than DHS group (40%). PFN had shown excellent Harris hip score in all type of intertrochanteric fractures than DHS group.

**Conclusion:** In this present study we assessed the functional outcome of dynamic hip screw and Proximal Femoral Nailing in intertrochanteric fractures using Harris hip score. In view of negligible complications and superior functional outcome, we suggest that Proximal Femoral Nailing is suitable device for both stable and unstable intertrochanteric fractures than dynamic hip screw.

© 2020 Published by Innovative Publication. This is an open access article under the CC BY-NC license (<https://creativecommons.org/licenses/by-nc/4.0/>)

### 1. Introduction

Intertrochanteric fractures are predominately associated with trivial trauma among the geriatric patients. It is commonly encountered in orthopaedic surgeon day to day daily practices. Intertrochanteric fractures treated without surgical interventions, can result in malunion with coxa vara deformity, shortening of the limb, limping, bedsores and other secondary complications.<sup>1</sup> Earlier conservative treatment was given which usually delayed the active mobilization of the patient for about 4 weeks which lead to multiple secondary complications. Nowadays treatment of choice for intertrochanteric fractures is operative management. Various surgical procedures using different implants have been described to treat intertrochanteric

fractures. The important purpose of surgical treatment have to be early mobilization to keep away from secondary complications, which is obtained by fixation of Dynamic Hip screw (DHS) or Proximal Femoral Nail (PFN).

Intertrochanteric fractures are common in elderly patients, mainly due to trivial trauma. The percentage of intertrochanteric fractures differs from country to country. Increased incidence of varus deformity and also shortening leads to poor function. Surgical management of intertrochanteric fractures was introduced to improve functional outcomes and reduce complications from prolonged bed rest.<sup>2,3</sup>

Intramedullary nails such as PFN, are more stable under the action of a shorter lever arm, so the distance of the nail from the hip joint is reduced compared with that for a plate, thereby reducing the deformation forces across the implant. The biomechanical advantage of intramedullary

\* Corresponding author.

E-mail address: [drjose07@yahoo.co.in](mailto:drjose07@yahoo.co.in) (R. S. Jose).

devices is important particularly in unstable trochanteric and sub trochanteric fractures.<sup>4,5</sup>

The best part of DHS is its sliding effect which allows fracture site compression and minimizing the dangers of screw cut out and migration associated with non-sliding devices. Early rehabilitation of the patient and prevention of medical complications like thromboembolism, decubitus ulcer by early mobilization.<sup>6</sup>

The purpose of the present study was to analyze the functional outcome of dynamic hip screw (DHS) fixation and proximal femoral nailing (PFN) in stable and unstable intertrochanteric fractures by using Harris hip score.<sup>7</sup>

## 2. Materials and Methods

This Prospective study was conducted among 70 patients who were diagnosed to have Intertrochanteric Fracture of Femur of > 18 years old of either sex attending orthopaedic outpatients and inpatients Department in Sree Mookambika Institute of Medical Sciences, Kulasekharam. Patients were grouped into two groups by Convenient sampling technique. First group of patients were treated by dynamic hip screw fixation and Second group of patients were treated by Proximal femoral nailing with 35 patients in each group. Patients were diagnosed based on Clinical examination and Plain radiograph of part affected. We included patients sustained Intertrochanteric fracture of femur of age more than 18 years, and fracture types like Basicervical, Reverse oblique fractures, Displaced intertrochanteric fractures and also Sub trochanteric extension of intertrochanteric fractures. Patients of age less than 18 years of age, Patients with tumor, Patients with Pathological fracture, Patients with Intertrochanteric fracture of femur with shaft of femur fracture (segmental fracture) and patients with Bilateral Intertrochanteric fracture of femur were excluded from our study.

Intertrochanteric fractures are fixed with DHS by lateral approach<sup>8</sup> and regular femoral nailing. Duration of postoperative stay is 10 days for dynamic hip screw and 5 days for proximal femoral nailing. All patients were mobilized on the very next day of surgery. Postoperative check x-ray taken. Toe touch walking started on day one. Full weight bearing allowed only after evidence of full radiological union.<sup>9</sup> We assess the patients on Outpatient basis at 6 weeks, 3 months, 6 months, and 1 year and then yearly follow up, postoperatively functional outcome of both fixations were assessed by using Harris - Hip Score (HHS).

## 3. Results

In this study we included 70 patients with all type of intertrochanteric fractures and 35 of them were treated with dynamic hip screw and the other 35 were operated with Proximal Femoral nailing respectively by systemic random

sampling. Functional outcome was done using HHS which reveals the following results.

### 3.1. Age

Among 70 patients of intertrochanteric fractures who were taken for DHS, the mean age in years was found to be 67 years, and the mean age group in patients who were taken for PFN is 66 years.

### 3.2. Distribution of the patients

1. There was a female preponderance in DHS (57.14%).
2. There was a male preponderance in PFN (62.86%).

### 3.3. Type of fracture

In the distribution of fractures according to Boyd & Griffin classification,<sup>10</sup> Type III intertrochanteric fractures were more common (70%) because most patients had low velocity injuries and road traffic accidents. In this study, right sided intertrochanteric fractures were more common (54.29%).

### 3.4. Complications

Among 70 patients with intertrochanteric fractures, patients developed less complication in PFN group (20%) than DHS group (40%). Superficial infections more in DHS group (11.43%) than PFN group (5.71%) Screw cut -out noted in two patients of DHS group (5.71%) and one patient (2.86%) in PFN group. Patients who were lost to follow up is more in PFN group (11.43%) than DHS group (8.57%). Varus collapse founded in two patient of DHS group (5.71%) but not noted in PFN group. Deep infection founded in the patient among DHS group (2.86%) and not noted in PFN group Limb shortening noted in two patients of DHS group (5.71%) and No limb shortening noted in PFN group.

### 3.5. Mean Harris Hip score

Mean Harris hip score in DHS group is 70.28(SD  $\pm$ 30.51).

Mean Harris hip score in PFN group is 75.17(SD  $\pm$ 31.51).

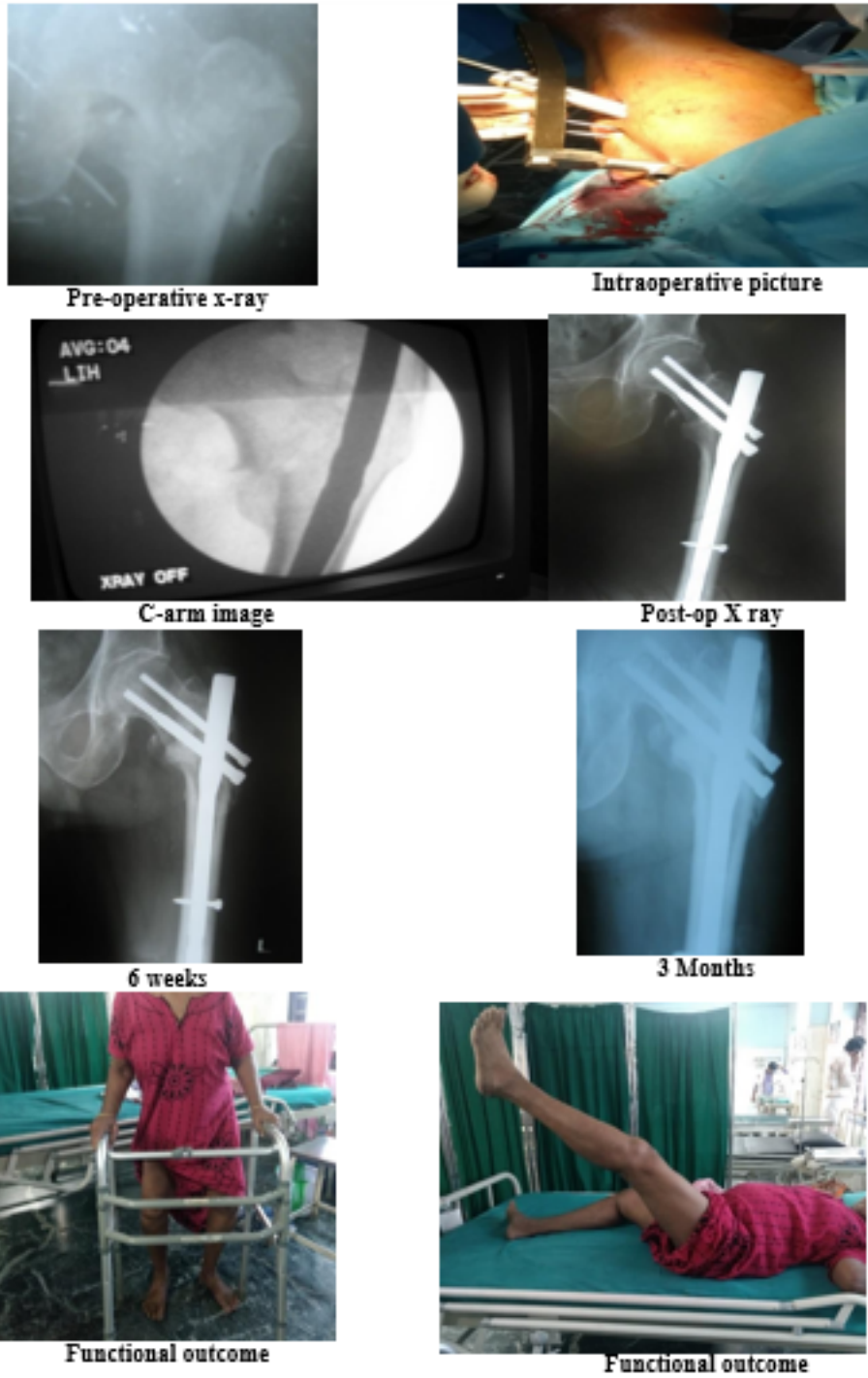
PFN had shown excellent Harris hip score in all type of intertrochanteric fractures than DHS group.

### 3.6. Distribution of patients based on the Harris Hip Score

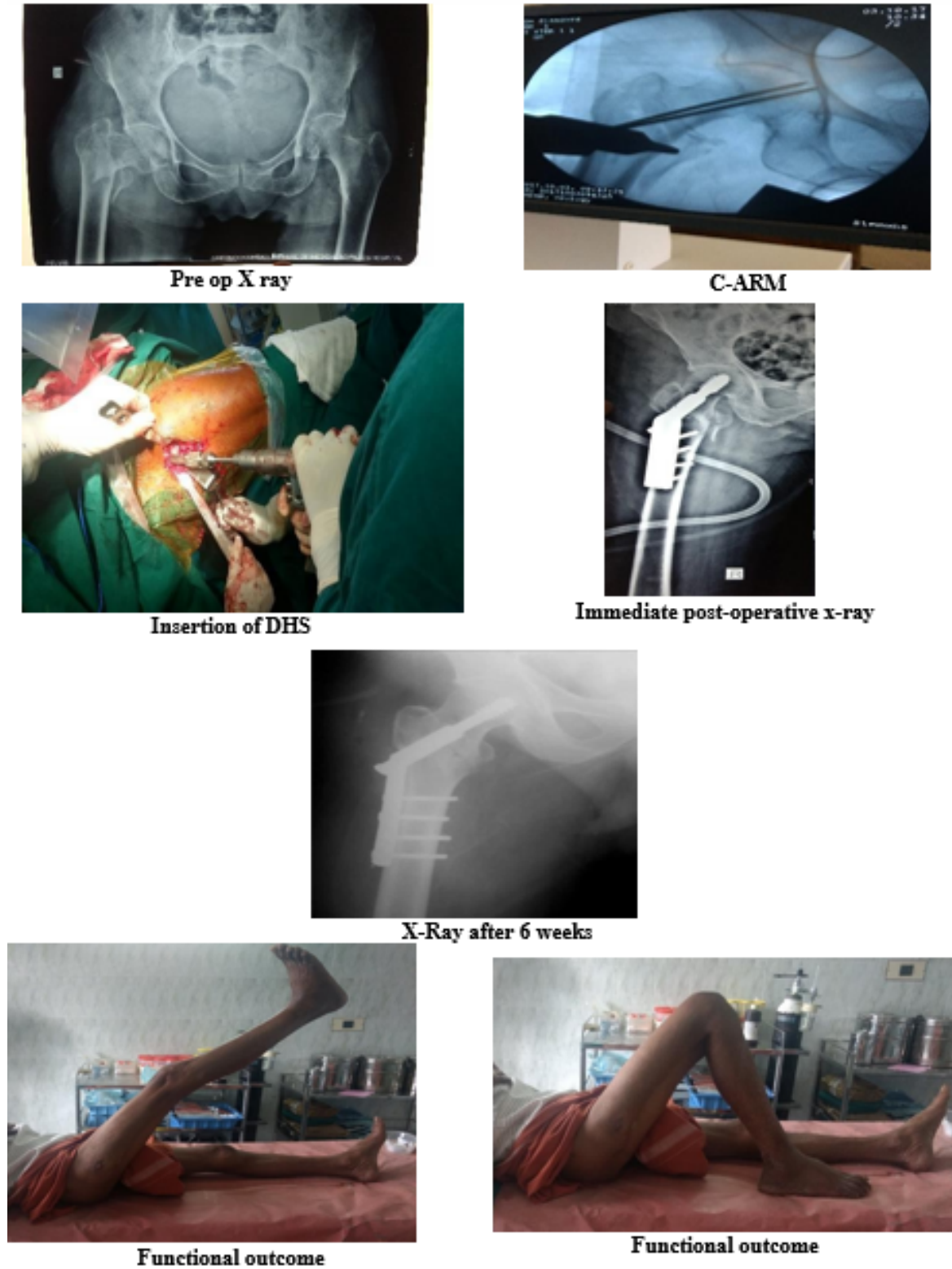
40% in the PFN group had shown excellent Harris hip score compared to DHS group who had shown 14.29%.

## 4. Discussion

The objective of the study is to compare the functional prognosis of patients with intertrochanteric fractures treated



**Fig. 1: Case 1: Proximal femoral nailing (Excellent Result)**



**Fig. 2: Case 2: Dynamic hip screw (DHS) (Good Result)**

**Table 1:** Mean age of patients DHS and PFN

Type	Age (years) (MEAN±SD)
DHS	67.42±9.33
PFN	66.97±8.20

**Table 2:** Distribution of patients in DHS and PFN

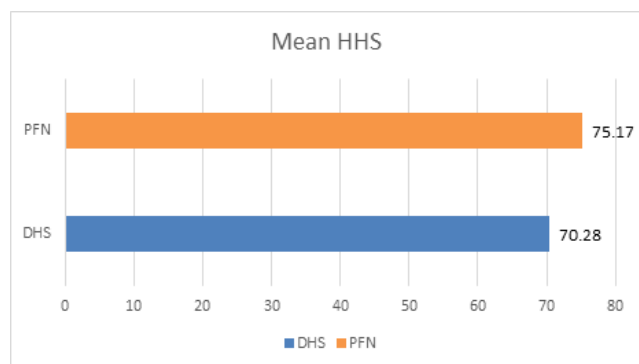
Type	Number	Male		Female	
		Percentage (%)	Number	Percentage (%)	Number
DHS	15	42.86	20	57.14	
PFN	22	62.86	13	37.14	

**Table 3:** Distribution of patients based on diagnosis in DHS and PFN

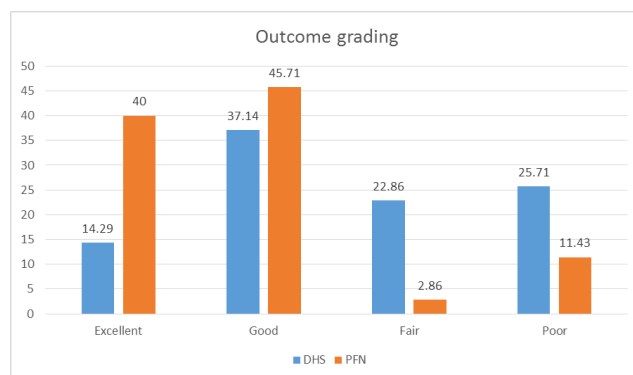
Diagnosis	DHS		PFN	
	Number	Percentage (%)	Number	Percentage (%)
Type I IT Fracture Right	1	2.86	0	0.00
Type I IT Fracture Left	0	0.00	0	0.00
Type II IT Fracture Right	5	14.29	1	2.86
Type II IT Fracture Left	9	25.71	1	2.86
Type III IT Fracture Right	10	28.57	19	54.29
Type III IT Fracture Left	9	25.71	9	25.71
Type IV IT Fracture Right	1	2.86	2	5.71
Type IV IT Fracture Left	0	0.00	3	8.57

**Table 4:** Complication in DHS and PFN

Complications	DHS		PFN	
	Number	Percentage (%)	Number	Percentage (%)
No complication	21	60.00	28	80.00
Superficial infection	4	11.43	2	5.71
Screw cut- out	2	5.71	1	2.86
Lost to follow up	3	8.57	4	11.43
Varus collapse	2	5.71	0	0.00
Deep infection	1	2.86	0	0.00
Limb shortening	2	5.71	0	0.00



Graph 1: Mean HHS in DHS and PFN



Graph 2: Distribution of patients based on the Harris Hip Score.

with two different fixation devices, the extra medullary dynamic hip screw and the intramedullary Proximal Femoral nail. Our study consisted of 70 patients operated with DHS and PFN belong to the age group 60 to 80 years with average age in DHS group 67.42 and PFN group 66.97.

In our study 53 % patients were females and 47 % were males in each group. KYLE series 58% were females and 42% were males.

Most common mode of injury is accidental fall injury and road traffic accidents. In our study we had 39 cases right sided and 31 cases left sided. Most common associated injuries are 4 public ramus fractures. Others are 1 shaft of femur, 2 both bones leg fractures, and 1 pneumothorax and 1 head injury. Compared with dynamic hip screw, the proximal femur nailing has less pain. Limping is less in proximal femoral nailing. Harris hip score was better in proximal femoral nailing in both 3 and 6 months of follow than dynamic hip screw.

In their series Baumgartner et al.<sup>11</sup> found that the operative times of the DHS group were 10 % higher than PFN group. Saudan and colleagues found in their series that there was no significant difference in the operating time between the two groups of patients.<sup>12</sup> In our study we found more operating time in the DHS group. Since PFN has narrow distal diameter, the event of femoral shaft fractures is no more a problem.<sup>13</sup> Moreover, rotation control is inherent in nail design and does not rely on multiple components. These intramedullary nails have smaller diameter lag screws and therefore require less proximal femoral reaming, thereby decreasing the chance of iatrogenic proximal femoral fractures. In our study, there were no cases of femoral shaft fractures or extension of the original fractures during or after surgery. This findings were similar to the results of Saudan et al.<sup>12</sup> There was no significant difference in fracture healing time between the two groups, because all fractures united at average of 12 weeks. In our study, screw cut out noted in two patients of DHS group (5.71%) and one patient (2.86%) in PFN group, which was similar to the series by Menezes and colleagues.

Compared with the PFN group, we attribute the greater number of wound infections in the DHS group due to longer incisions, diabetes, and subsequent more soft tissue handling in this group. However those were only superficial wound infections, there was only a delay in wound healing by about 7 days and no further surgical intervention was needed. Wound healed with regular dressings. Saudan and associates in their series found no significant differences between the rate of infection among the PFN and DHS groups.

Banan H<sup>14</sup> believed that PFN is a superior choice for stabilizing sub trochanteric and unstable trochanteric fractures. Pajarinet et al<sup>15</sup> compared the postoperative recovery of patients treated with DHS and PFN in their series, and found similar findings. Zeng Cet et al<sup>16</sup> in his meta-analysis showed that PFN was superior to DHS in terms of operation time, intraoperative blood loss rate, fixation failure rate and overall complications. There were minimal complications in PFN group compared to DHS group in terms of like less infection, sliding and limb length discrepancy. Common reasons for failure of fixation are unstable fractures, lack of anatomical reduction, osteoporosis, failure of fixation devices and incorrect screw placement. In our study we have found that the PFN is

more beneficial in unstable fracture pattern in addition to reverse oblique intertrochanteric fractures. Therefore PFN is superior to DHS in the treatment of femoral intertrochanteric fractures.

In present study Dynamic hip screw has 14.29% of excellent results, whereas proximal femoral nailing has 40% excellent results. Postoperative complications were superficial infection in 6 cases, limb length discrepancy was seen in 2 patients. Varus collapse noted in 2 cases of DHS. No vascular and neurological complications were noted in these 70 cases.

Among patients with unstable fractures the functional outcome was significantly better in those treated by PFN than those patients treated with DHS. Compared with unstable fractures treated with DHS, we have achieved good results for all unstable fractures treated with PFN.

## 5. Conclusion

In this present study we assessed the functional outcome of dynamic hip screw and Proximal Femoral nailing in intertrochanteric fractures, we reached the following conclusions:

1. In view of less duration of surgery, small incision and less blood loss proximal femoral nailing can be comfortably used in elderly patients with other comorbidities. Complications such as shortening, varus collapse, screw cut out was slightly higher in DHS group than proximal femoral nailing group.
2. Duration of postoperative hospital stay more in dynamic hip screw than proximal femoral nailing.
3. Pain, limp, support, walking distance, squatting, sitting cross legged, early mobilization and using of public transport are better results in proximal femoral nailing than dynamic hip screw.
4. According to our study we conclude that dynamic hip screw is suitable device for stable intertrochanteric fractures but not an ideal implant for unstable trochanteric fractures. Proximal femoral nailing is better choice for both stable and unstable intertrochanteric fractures.

Thus, we can conclude that Proximal Femoral nailing is an appropriate device for both stable and unstable intertrochanteric fractures than dynamic hip screw in terms of minimal complication and good functional Harris hip score.

## 6. Source of Funding

None.

## 7. Conflict of Interest

None.

## References

1. Falch JA, Ilebakk A, Slungaard U. Epidemiology of hip fractures in Norway. *Acta Orthop Scand*. 1985;56(1):12–6.
2. Hagino H, Furukawa K, Fujiwara S. Recent trends in incidents and lifetime risk of hip fracture in Tottori. *Japan Osteoporosis Int*. 2009;20(4):543–8.
3. Jarnlo GB, Thorngren KG. Background Factors to Hip Fractures. *Clin Orthop and Relat Res*. 1993;(287):41–9.
4. Schumpelick W, Jantzen PM. A new principle in the operative treatment of trochanteric fracture of the hip. *J Bone Joint*. 1988;70:1297–1303.
5. Massie WK. Fractures of the Hip. *J Bone Joint Surg*. 1964;46(3):658–90.
6. Sermon A, Broos PLO. The use of PFNA in treatment of intertrochanteric fractures. *Folia Traumatol*. 2007;p. 48–52.
7. Rockwood and Green's, Fractures in Adults. vol. 1. 8th ed.;
8. Hoppenfeld S, Boer PD, Buckley R. Surgical Exposures in Orthopaedics the Anatomic Approach. 5th ed.; 2016.
9. Carneiro MB, Alves DP, Mercadante MT. Physical therapy in the postoperative of proximal femur fracture in elderly. *Acta ortopedica brasileira*. 2013;21(3):175.
10. Sonawane DV. Classifications of intertrochanteric fractures and their clinical importance. *Trauma Int*. 2015;1:7–11.
11. Baumgaertner MR, Curtin SL, Lindskog DM. Intramedullary Versus Extramedullary Fixation for the Treatment of Intertrochanteric Hip Fractures. *Clin Orthop Relat Res*. 1998;348:87–94.
12. Saudan M, Lubbeke A, Sadowski C, Riand N, Stern R, Hoffmeyer P. Peritrochanteric fractures: is there an advantage to an intramedullary nail? A randomized, prospective study of 206 patients comparing the dynamic hip screw and proximal femoral nail. *J Orthop Trauma*. 2002;16:386–93.
13. Hardy DCR, Descamps PY, Krallis P, Fabeck L, Smets P, Bertens CL, et al. Use of an Intramedullary Hip-Screw Compared with a Compression Hip-Screw with a Plate for Intertrochanteric Femoral Fractures. A Prospective, Randomized Study of One Hundred Patients\*. *J Bone Joint Surg*. 1998;80(5):618–30.
14. Banan H, Al-Sabti A, Jimulia T, Hart AJ. The treatment of unstable, extracapsular hip fractures with the AO/ASIF proximal femoral nail (PFN)—our first 60 cases. *Inj*. 2002;33(5):401–5.
15. Pajarinen J, Lindahl J, Michelsson O, Savolainen V, Hirvensalo E. Peritrochanteric femoral fractures treated with a dynamic hip screw or a proximal femoral nail - A randomized study comparing post-operative rehabilitation. *J Bone Joint Surg*. 2005;87:76–81.
16. Zeng C, Wang YR, Wei J, Gao SG, Zhang FJ, Sun ZQ, et al. Treatment of Trochanteric Fractures with Proximal Femoral Nail Antirotation or Dynamic Hip Screw Systems: A Meta-Analysis. *J Int Med Res*. 2012;40(3):839–51.

## Author biography

**R Sahaya Jose** Associate Professor

**K Visnu** Postgraduate

**K Vivek** Postgraduate

**R Manikandan** Postgraduate

**Cite this article:** Jose RS, Visnu K, Vivek K, Manikandan R. Comparative analysis of the functional outcome in intertrochanteric fractures between dynamic hip screw and proximal femoral nailing - A prospective study. *Indian J Orthop Surg* 2020;6(3):228-234.