



Case Report

Tuberculosis of the medial end of the clavicle, a unique presentation

Sarvesh Kakhandaki^{1,*}, Pranav Paritekar¹, Ramangouda Biradar¹, Ashok Nayak¹, Santosh Nandi¹, Sandeep Naik¹

¹Dept. of Orthopaedic, Shri BM Patil Medical College, Vijayapura, Karnataka, India



ARTICLE INFO

Article history:

Received 19-04-2021

Accepted 01-06-2021

Available online 12-06-2021

Keywords:

Clavicle

Tuberculosis

Osteomyelitis

ABSTRACT

Tuberculosis of the medial end of the clavicle is very rare osteomyelitis, secondary to extrapulmonary skeletal Tuberculosis. We report a rare presentation of clavicular Tuberculosis as a swelling in the medial end of the clavicle. Tumours are much more frequent than infections in this bone, and thus it is challenging to conclude before surgical excision. With the worldwide resurgence of Tuberculosis, clinicians should maintain a high index of suspicion as more infection at unusual sites is being reported.

© This is an open access article distributed under the terms of the Creative Commons Attribution License (<https://creativecommons.org/licenses/by/4.0/>) which permits unrestricted use, distribution, and reproduction in any medium, provided the original author and source are credited.

1. Introduction

Tuberculosis of the medial end of the clavicle alone, without the involvement of joints next to it, is rare.¹ With the increasing recurrence of Tuberculosis as a worldwide infection, a growing number of cases are being reported with unusual characteristics. The medial end of the clavicle is a unique site of Tuberculosis of skeletal origin. Due to its exceptional blood supply, extrapulmonary Tuberculosis in the SC joint (sternoclavicular) region is rare. The tubercular presentation at this site may frequently be unusual, leading to confusion in the clinical diagnosis and delays in proper treatment. In the select research and literature on this topic, the medial end of the clavicle is more frequently diseased than the lateral end.² Also, Tuberculosis as an infection is known to copy all types of lesions. Solitary lesion of the clavicle without pulmonary involvement leads to confusion in the diagnosis and hence further management. Using the latest investigative modalities like plain radiograph and MRI may indicate a similar diagnosis. Other similar conditions like infection and malignancy may not help to diagnose the tubercular origin.

2. Case Report

A 59-year-old male came to the orthopaedics outpatient department with complaints of pain and swelling over the left sternoclavicular region for the past six months. The pain began gradually, it was continuous and dull, aching. The pain used to subside with analgesics. It was also associated with minor swelling, which the patient ignored for the last three months. The patient did not present with any recent trauma or history of fall. Patient gives history of low-grade fever, which used to subside on taking oral tablets. In the last two months, pain and swelling have increased suddenly with the painful movement of the shoulder.

Examination findings suggested that it was a round smooth swelling was present over the right midclavicular region, which was 5x3 cm in size. It was tender swelling, firm to hard in consistency and not adhering to the skin and fixed to the underlying bone. The skin over swelling was not discolored or hyperpigmented. No dilated / engorged veins / discharging sinuses.

Blood investigations suggest raised total count with lymphocytosis, increased ESR and CRP levels, and serology investigations were reactive to HIV 1 and HIV 2.

CT scan of left sternoclavicular joint showed cortical erosions and significant destruction of subchondral bone

* Corresponding author.

E-mail address: sarveshrk08m2373@gmail.com (S. Kakhandaki).

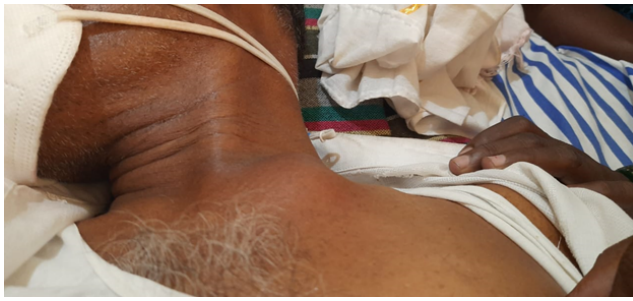

Fig. 1:

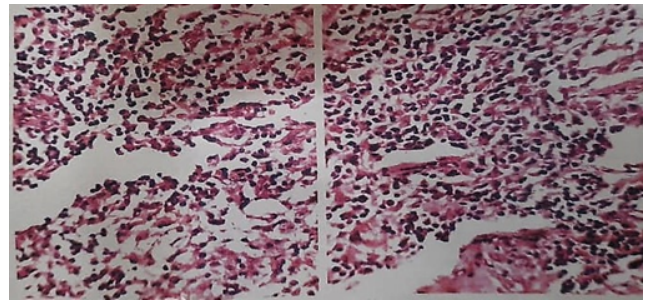


Fig. 4:

with a relative widening of left sternoclavicular joint space and advised biopsy co-relation.

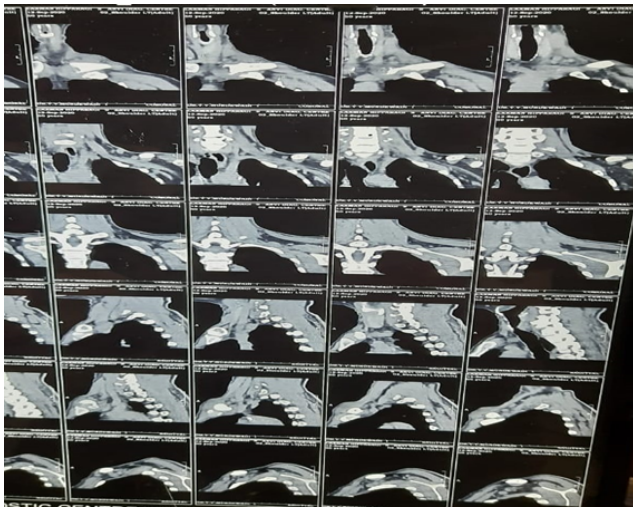


Fig. 2:

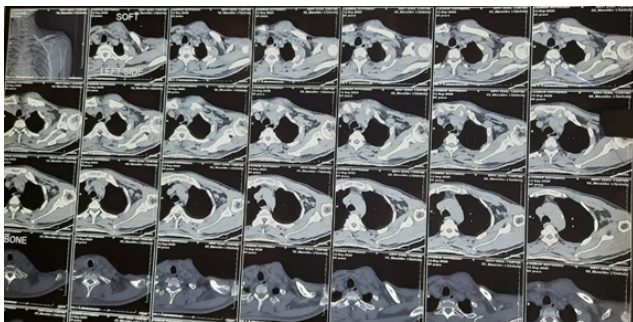


Fig. 3:

Histopathology report of excision biopsy of the swelling showed a microscopic impression of foci of necrosis with granulomas with giant cells and chronic inflammatory cells, fibro collagenous tissue admixed with plenty of necrosis. No granuloma/malignancy seen. Impression was a Granulomatous lesion with necrosis, suggestive of Koch's Induced pathology.

2.1. Treatment protocol

HRZE anti tubercular therapy regimen consisting of four drugs, namely: rifampicin(r) 450 mg, isoniazid(h) 300 mg, ethambutol(e) 800 mg, and pyrazinamide(z) 1500 mg.

Follow-up was done at six weeks. Pain and swelling had reduced significantly. Range of motion of the right shoulder had improved significantly.

3. Discussion

Clavicular Tuberculosis is a rare entity.³ Secluded clavicular Tuberculosis is even less frequent than other skeletal Tuberculosis.⁴ Tuberculosis can involve any site of the clavicle, with the most common involvement is noted in the medial one-third region. Adjacent joint involvement can also be seen. It is associated with pain without significant bone destruction, which may later present with cold abscess, discharging sinuses, and non-healing ulcers.³ Radiologically the lesions in Tuberculosis can be either destructive or proliferative, and in rare, pathological fractures can also be seen.³ Conventional radiographic pictures may show multiple cystic cavities or sequestrum, honeycomb appearance or diffuse thickening. Such a Diagnosis based only on plain radiograph is challenging due to overlapping anatomical structure, and therefore it is not a valuable tool for evaluating the changes.³ CT scan and MRI provide better images and diagnosis.⁵ CT scan is a better tool for appreciating bony changes, and MRI is more helpful in appreciating the extent of the lesion with determining soft tissue and bone marrow involvement.⁶ Diagnosis can be than be confirmed by histopathological and microbiological examination. Bony tissue specimen can be obtained by Fine needle aspiration cytology(FNAC), core biopsy and/or curettage.³ The primary treatment modalities are multidrug anti-tubercular regimen. However, in advance cases which are not responsive to oral treatment, anti-tubercular drugs should be combined with surgical measures such as debridement and curettage of lesion or resection of infected clavicle without loss of function. Surgical intervention is more useful when the disease is unresponsive to medical treatment, when the diagnosis is uncertain, or

an impending abscess burst. The mainstay of treatment is modern medical therapy with multidrug antimicrobial drugs in which isoniazid, rifampicin, pyrazinamide, and ethambutol for eight weeks and rifampicin and isoniazid for the next forty weeks.⁷ The response for treatment is monitored clinically by decreasing the swelling or ulceration and biologically by decreasing ESR. Surgical excision is indicated when the clinical diagnosis is unclear or the disease does not respond to medical therapy alone.

4. Conclusion

Clavicle tuberculosis should be considered an important differential of non-traumatic lesion of the clavicle. And chronic swelling at a strange place not responding to routine treatment, a high index of suspicion should be kept for extrapulmonary Tuberculosis.

5. Source of Funding

None.


6. Conflict of Interest

The authors declare that there is no conflict of interest.

References

- Dugg P, Shivhare P, Mittal S, Singh H, Tiwari P, Sharma A. Clavicular osteomyelitis: a rare presentation of extra pulmonary tuberculosis. *J Surg Case Rep*. 2013;2013(5):rjt030. doi:10.1093/jscr/rjt030.
- Agarwal A, Maheshwari R. Tubercular Osteomyelitis Clavicle: A Case Report. *J Orthop Case Reports*. 2014;4(4):51–3.
- Aggarwal AN, Dhammi IK, Singh AP, Kumar S, Goyal MK. Tubercular Osteomyelitis of the Clavicle: A Report of Four Cases. *J Orthop Surg*. 2009;17(1):123–6. doi:10.1177/230949900901700128.
- Gerscovich EO, Greenspan A. Osteomyelitis of the clavicle: clinical, radiologic, and bacteriologic findings in ten patients. *Skelet Radiol*. 1994;23(3):205–15. doi:10.1007/bf00197463.
- Shah J, Patkar D, Parikh B, Parmar H, Varma R, Patankar T. Tuberculosis of the sternum and clavicle: imaging findings in 15 patients. *Skelet Radiol*. 2000;29(8):447–53. doi:10.1007/s002560000207.
- Sachdeva S, Kaur SP, Garg R, Khurana T, Garg S, Jindal A. Tubercular Arthritis of Sternoclavicular Joint: A Case Report. *Ann Int Med Dent Res*. 2016;2(6):5–7. doi:10.21276/aimdr.2016.2.6.me2.
- Agarwal A, Pruthi M. Tuberculosis of clavicle in children: a report of 3 cases with review of literature. *Eur J Orthop Surg Traumatol*. 2011;21(6):411–5. doi:10.1007/s00590-010-0726-1.

Author biography

Sarvesh Kakhandaki, Senior Resident  <https://orcid.org/0000-0002-2065-6862>

Pranav Paritekar, Junior Resident

Ramangouda Biradar, Associate Professor

Ashok Nayak, Professor

Santosh Nandi, Professor

Sandeep Naik, Associate Professor

Cite this article: Kakhandaki S, Paritekar P, Biradar R, Nayak A, Nandi S, Naik S. Tuberculosis of the medial end of the clavicle, a unique presentation. *Indian J Orthop Surg* 2021;7(2):178-180.