

## Application of Radiofrequency (RF) in Debridement and Wound Bed Preparation (WBP)

Bibilash Babu Suseela<sup>1,\*</sup>, Chittoria Ravi Kumar<sup>2</sup>, Pandey Sandhya<sup>3</sup>, Senthil Kumaran<sup>4</sup>, Friji MT<sup>5</sup>, Mohapatra Devi Prasad<sup>6</sup>, Dinesh Kumar Sivakumar<sup>7</sup>

<sup>1,3,4</sup>Senior Resident, <sup>2</sup>Head, <sup>4,5,6</sup>Associate Professor, Dept. of Plastic Surgery, Jawaharlal Institute of Postgraduate Medical Education and Research (JIPMER), Pondicherry, Indian – 605006

**\*Corresponding Author:**

E-mail: drchittoria@yahoo.com

### Abstract

Wound Bed Preparation (WBP) without debridement is not possible. Debridement has to be radical but without harming the normal tissue. Another important aspect is simultaneous stimulation of wound bed for Plastic Surgeon to cover with wound with skin graft/flap. These requirements are met with radiofrequency debridement. This article highlights the application of radiofrequency debridement not only in debriding the necrotic tissue but also its role in stimulating the wound bed for wound bed preparation.

**Key words:** Radiofrequency, Debridement, Wound bed preparation (WBP).

Access this article online	
Quick Response Code:	Website: www.innovativepublication.com
	DOI: 10.5958/2395-1362.2016.00006.2

### Introduction

Debridement is removal of devitalized necrotic tissue. Wound Bed Preparation (WBP) is dynamic process involving series of techniques and methods to prepare wound bed for wound to heal itself or cover by skin graft or flap. There are several surgical and nonsurgical methods for debridement of wounds, of which less invasive methods are getting more and more popular because of its lesser need for anaesthesia, less tissue damage and better haemostasis.<sup>1</sup> Radio frequency ablation has proven advantage of debridement, wound bed stimulation and better healing compared to others.<sup>2,3</sup> The extent of debridement using radiofrequency device is comparable to the surgical debridement along with better haemostasis and wound bed stimulation. This article highlights the application of radiofrequency debridement and its experience in a tertiary care centre.

### Methodology

This study was conducted in the Department of Plastic surgery, JIPMER, Pondicherry, India from November 2013 to October 2014. This is a retrospective analysis of 18 cases of wounds of different aetiologies requiring debridement. All the wounds were debrided under general anaesthesia using the radiofrequency (RF) probe. The Ellman Surgitron F.F.P.F. EMC™ Radiofrequency machine was used for debridement at the setting of 5W (fig. 1). Toothed forceps was used to hold the necrotic tissue and was

removed with the RF probe (fig. 2) keeping in a combined mode (cutting and coagulation simultaneously). The slough which was tightly adhered to the wound bed was removed by this method (fig. 3). Once the necrotic tissue was debrided, wound bed was stimulated using the same probe at a lower energy of 3W (fig. 4). Amount of blood loss during the debridement was recorded. Time required for appearance of healthy granulation tissue (wound bed preparation) after wound bed stimulation by RF was recorded. After debridement and wound bed preparation wound was reconstructed following ladder of reconstruction (fig. 5).

### Results

Eighteen patients over one year duration with wounds of different aetiologies were analysed retrospectively. The mean age was 37.27 years with male to female ratio of 5:1. The most common etiology was trauma. Most common site of wound was lower limb. Mean duration of wound was 5.05 weeks. The maximum size of wound was 30 x 20 cm. The most common co-morbidity was anaemia (83.33 %), diabetes mellitus (38.8%) followed by hypertension (16.17%). Osteomyelitis was present in 3 patients (16.66%). No bleeding was noticed during the process of cutting of tissue by RF. The mean duration of wound bed preparation (WBP) after radiofrequency debridement and wound bed stimulation was 2.11 weeks. Wounds were reconstructed with split thickness skin graft (SSG) (fig. 6 a, b, c) in 3 patients (16.66 %), local flaps (fig. 7 a, b, c) in 2 patients (11.11 %), pedicle flaps (Fig. 8 a, b, c) in 7 patients (38.33%), microvascular free flap (Fig. 9 a, b, c) in 2 patients (11.11 %). Average duration of wound healing was 4 weeks. No complications were noted in 6 months follow up period (Table 1).



Fig. 1: Ellman Surgitron F.F.P.F. EMC™ Radio Frequency machine



Fig. 2: Different RF probes and foot switch

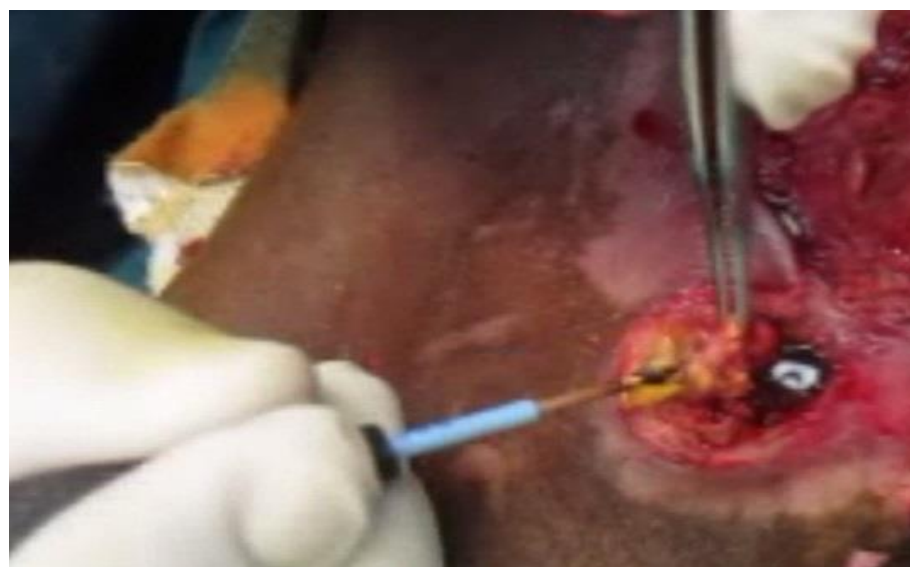

Fig. 3: Debridement with RF probe while holding the of necrotic tissue with toothed forceps

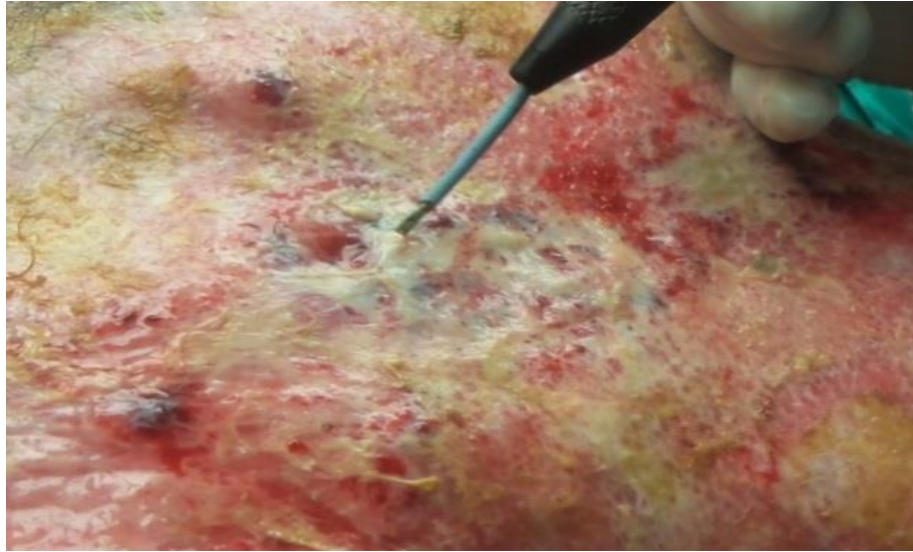


Fig. 4: Wound bed stimulation by RF probe using low energy (3W)

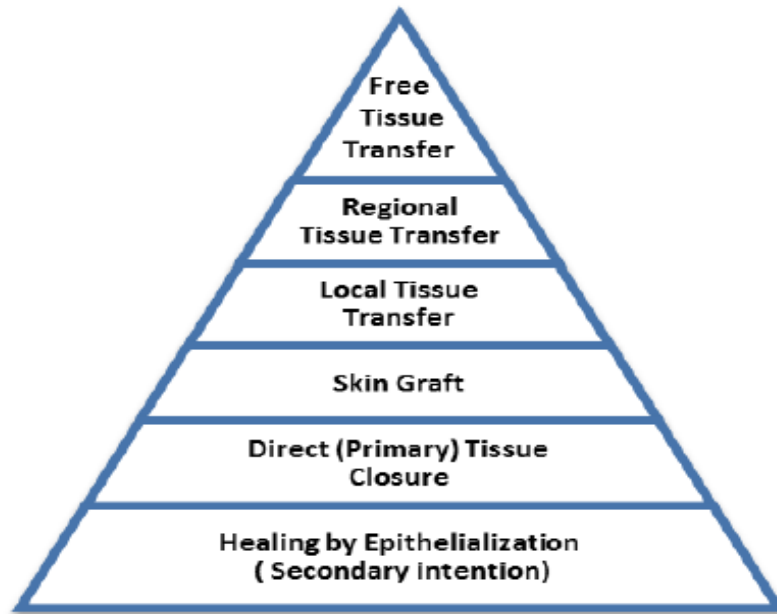

Fig. 5: Ladder of Reconstruction.

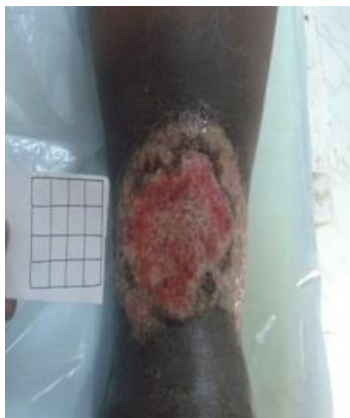

Fig. 6(a): Before RF Debridement.

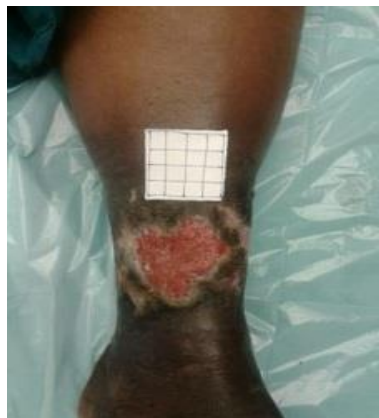

Fig. 6(b): After RF debridement and wound bed stimulation.

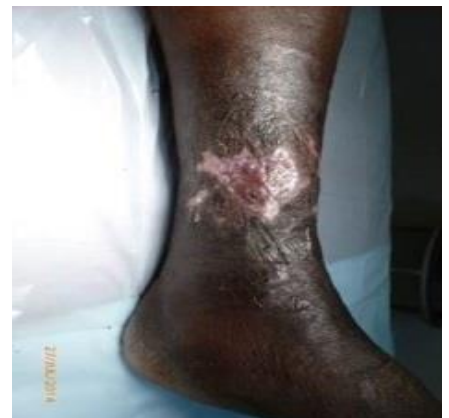
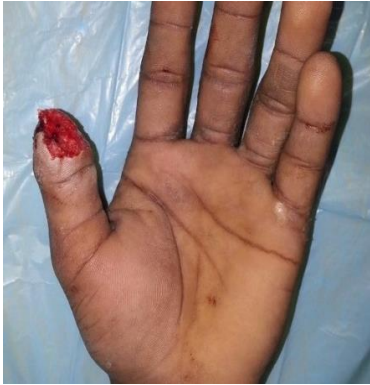
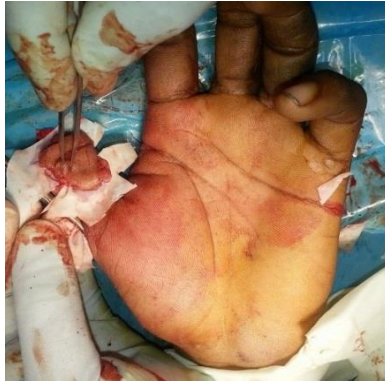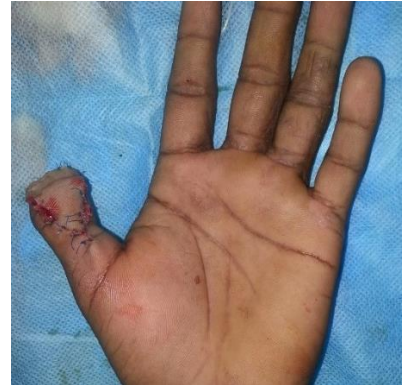Fig. 6(c): After wound reconstructed with split thickness skin grafting.



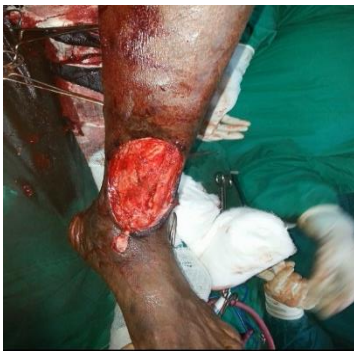**Fig. 7(a): Post trauma wound thumb**



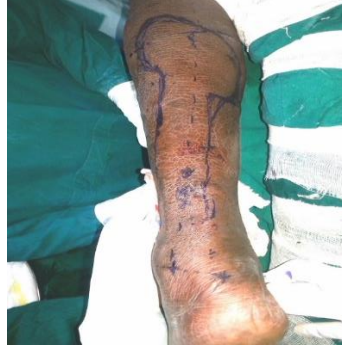**Fig. 7(b): After RF debridement and flap raised**



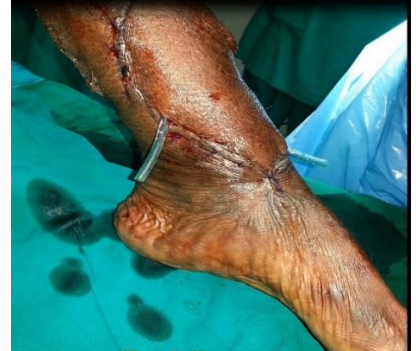**Figure 7(c): After flap cover**



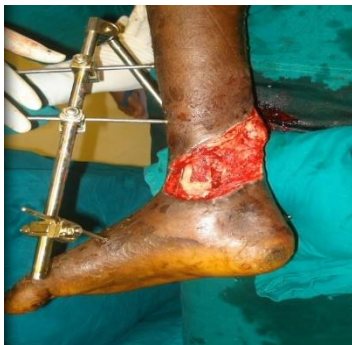**Fig. 8(a): Post trauma wound left leg**



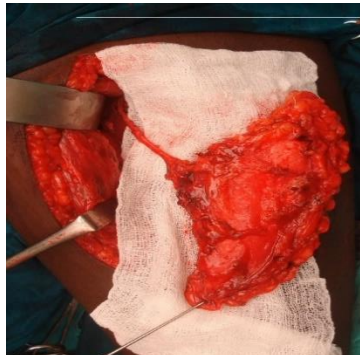
**Fig. 8b. After RF debridement, wound bed stimulation planned for pedicle reverse sural flap cover**



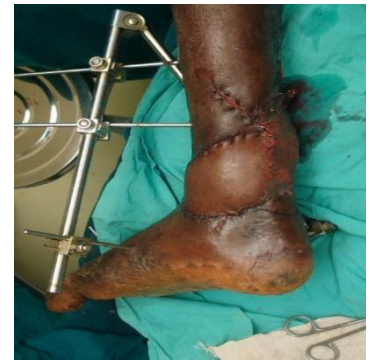**Fig. 8(c): After flap cover**



**Fig. 9(a): Post trauma Wound Right leg after RF debridement and wound bed stimulation.**



**Fig. 9(b): Antero Lateral Thigh (ALT) Free flap harvested.**



**Fig. 9(c): After free ALT flap cover.**

**Table 1: Case Summary**

Case No.	AGE & GENDER	ETIOLOGY	SITE	DURATION	WOUND MEASUREMENT	COMORBIDITY	TIME TAKEN FOR WBP	SKIN GRAFTING	LOCAL FLAP	PEDICLED FLAP	FREE FLAP	COMPLICATIONS
1	45/M	Trauma	Ischium	1 year	10x8 cm	Anemia	2 weeks	—	—	Yes	—	nil
2	40/F	Carcinoma	Oral cavity	6 months	10x6	Anemia	1 week	—	—	DP flap	—	nil
3	35/M	Diabetic foot	Foot	11 months	8x7 cm	Anemia	3 weeks	—	—	sural artery flap	—	nil
4	50/F	Carcinoma	Face	2 years	5x3	DM, HTN	—	—	Limberg flap	—	—	nil
5	30/M	Trauma	Leg	4 months	30x20	Anemia	5 weeks	Yes	—	—	—	nil
6	35/M	Snake bite	Upper limb	2 weeks	18x10	Anemia	1 week	—	—	double abdominal flap	—	nil
7	18/M	Cracker blast	Upper limb	1 day	6x4 cm	—	1 week	—	—	double abdominal flap	—	nil
8	30/M	Snake bite	Hand	6 months	12x5	Anemia	4 weeks	yes	—	—	—	nil
9	55/M	Ventral hernia	Abdomen	2 years	12x6	—	1 week	—	—	—	—	nil
10	55/M	Trauma	Leg	11 months	6x4 cm	DM	2 weeks	—	—	—	—	nil
11	25/M	Trauma	Hand	2 days	12x8	—	1 weeks	—	—	Shaw flap	—	nil
12	50/M	Post radiation	Lower limb	6 months	12x18	—	3 weeks	—	—	ALT flap	—	nil
13	50/M	Post op	Chest	6 months	4x2 cm	DM, HTN	1 week	—	Advancement flap	—	—	nil
14	28/M	Warfarin induced	Thigh	6 months	25x15	ITP	2 weeks	—	—	—	—	nil
15	35/F	Trauma	Sacrum	5 months	25x20	DM	4 weeks	—	—	—	—	nil
16	35/M	Trauma	Sacrum	6 months	30x20	Anemia	3 weeks	SSG	—	—	—	nil
17	30/M	Infection	Face	3 weeks	18x10	DM	3 weeks	—	—	—	Free LD flap	nil
18	35/M	Carcinoma	Scalp	8 months	15x15	—	2 weeks	—	—	—	Free ALT flap	nil
								3(16.6%)	2(11.1%)	7(38.3%)	2(11.1%)	

## Discussion

Debridement is the procedure of removing the devitalised tissue. Devitalised and moist tissues help in the multiplication of pathological organisms and causes wound infection. So the removal of these necrotic tissue and slough alters the healing environment of a wound. Wound debridement is an important procedure in all surgical specialities. Following are the different types of wound debridement methods commonly followed:

### Surgical Debridement

Sharp Surgical (scalpel and scissors), Radio frequency, Ultrasound and Laser debridement comes in this category. These method are rapid and selective methods which give a complete control for the surgeon for debridement and is subjective based on the surgeon's assessment, may or may not be done under anaesthesia based on the extent of debridement. The problem with sharp surgical debridement is bleeding and pain. Advantage of Radio frequency above the sharp surgical is the less amount of traction and mechanical effects which will produce lesser amounts of pain and the coagulation effect causing better haemostasis.<sup>4</sup>

### Mechanical Debridement

It includes hydro jet, syringe pump, wet to dry dressings etc. These methods are used for selective debridement for removal of minimal slough or partial removal. Jet lavage is an effective method for removal of the loosely attached slough on superficial plane. Advantage is less painful and better irrigation and cleansing. Syringe pumping is with similar mechanism but less effective. Wet to dry dressing by application of a wet gauze piece for longer times till it dries up and the slough is adherent to it. Then the gauze along with slough is removed together. Not a recommended method because of pain and slower action.<sup>5</sup>

### Enzymatic Debridement

Chemical enzymes are fast acting products that slough off necrotic tissue. These enzymes are derived from micro-organisms including clostridium histolyticum, collagenase, varidase, papain, and Bromelin. Some of these enzymatic debriders are selective, while some are not. This method works best on any wound, especially well on burns, with a large amount of necrotic debris, or with eschar formation. Contraindicated in patients with clotting disorders and

used with caution in patients with cellulitis, cavity wounds, wounds with exposed nerves or neoplasms. However, the results are mixed and the effectiveness is variable.<sup>6,7</sup>

### Autolytic Debridement

Autolysis uses the body's own enzymes and moisture to re-hydrate, soften and finally liquefy hard eschar and slough. Autolytic debridement is selective; only necrotic tissue is liquefied. It is also virtually painless for the patient. Autolytic debridement can be achieved with the use of occlusive or semi-occlusive dressings which maintain wound fluid in contact with the necrotic tissue. Autolytic debridement can be achieved with hydrocolloids, hydrogels and transparent films. To be used with caution in immunocompromised patient.<sup>8</sup>

### Biological Debridement

Also known as bio surgery. The larvae used for the treatment are those of *Lucilia sericata* or green bottle fly. The maggots are scientifically bred so that they will not carry any bacteria. Maggots can debride a wound in a day or two. The maggots derive nutrients through a process known as "extracorporeal digestion" by secreting a broad spectrum of proteolytic enzymes that liquefy necrotic tissue. The proponents of this therapy claim that it is fast, safe and effective. Disadvantages are aesthetic reasons and local discomfort and itching.<sup>9</sup>

### Radiofrequency Debridement (RF)

Radiofrequency is an energy source using high-frequency electrical current. Radiofrequency is especially useful in highly vascular areas. Advantages of radiofrequency over the electrocautery are its lower frequency, higher current and lesser zone of injury. The effect of pulsed radiofrequency stimulation on wound healing is already proven.<sup>10</sup>

### Radiofrequency versus other methods of debridement

There are various methods for debridement each of them can be used alone or in combination according to the purpose. One of the most used and effective method is surgical debridement. The main disadvantage of surgical debridement is pain and bleeding during the procedure. The radiofrequency probe which is commonly used for the making incisions and dissection of tissues during surgeries can be used for debridement of wounds. The advantage of the radiofrequency probe over normal electrocautery is that it can cut and coagulate the tissues at the same time. Further, at lower frequency it stimulates wound bed leading to early wound bed preparation. Most of the time patient's wound remains unfit for reconstruction because of wound bed not ready for cover due to presence of necrotic tissue in the wound.

A sharp debridement without harming the normal tissue with no loss of blood is essential. Early wound bed preparation is desired to save patient's time, cost and stay in the hospital. Kloth et al highlighted in their study application of RF in bed stimulation.<sup>10</sup> In our study we observed that radiofrequency debridement helped in sharp debridement of necrotic tissue without any blood loss. Due to wound bed stimulation wound beds were made ready for a reconstruction in mean duration of 2.11 weeks. Due to early wound bed preparation patient's stay in the hospital can be reduced. The present study has limitations of retrospective analysis, no control, small sample size, no statistical analysis performed and no comparative data available. A large prospective, randomized, blind, control study with statistical analysis is required to study the effectiveness of RF debridement in wound bed preparation.

### Conclusion

Radiofrequency debridement (RF) may be used not only for sharp debridement of necrotic tissue without blood loss but also to stimulate wound bed for early cover and reconstruction.

### Disclaimer/ Source of Funding/ Conflicts of Interest

The study has no conflict of interest. The study was supported by the department of plastic surgery, JIPMER, Pondicherry.

### References

1. Anderson, Irene. Debridement methods in wound care. *Nursing Standard*. 2006; 20(24):65.
2. Yang R, Zuo T, Zhu J, Zhong H, Wu K, Hou S, Rungong Y. Effect of Radiofrequency Ablation on Healing of Infected Full-Thickness Wounds in Minipigs. *The international journal of lower extremity wounds*. 2013;12(4): 265-70.
3. Yang R, Zuo T, Zhu J, Zhong H, Wu K, Hou S. Effect of pulsed radio frequency stimulation on wound healing: a double-blind pilot clinical study. *Int J Low Extrem Wounds*. 2013; 12(4):265-70.
4. Attinger CE, Bulan E, Blume PA. Surgical debridement. The key to successful wound healing and reconstruction. *Clinics in podiatric medicine and surgery*. 2000; 17(4):599-630.
5. Granick MS, Tenenhaus M, Knox KR, Ulm JP. Comparison of wound irrigation and tangential hydrodissection in bacterial clearance of contaminated wounds: results of a randomized, controlled clinical study. *Ostomy Wound Management*. 2007; 53(4):64.
6. Ramundo J, Gray M. Enzymatic wound debridement. *Journal of Wound Ostomy & Continence Nursing*. 2008; 35(3):273-80.
7. Burke JF, Golden T. A clinical evaluation of enzymatic debridement with papain-urea-chlorophyllin ointment. *The American Journal of Surgery*. 1958;95(5): 828-42.
8. König M. Enzymatic versus autolytic debridement of chronic leg ulcers: a prospective randomised trial. *Journal of wound care*. 2005; 14(7):320-23.
9. Mumcuoglu KY, Ingber A, Gilead L, Stessman J, Friedmann R, Schulman H, et al. Maggot therapy for

- the treatment of intractable wounds. *International journal of dermatology*. 1999; 38(8): 623-27.
10. Kloth L.C, Berman JE, Sutton CH, Jeutter DC, Pilla AA, Epner ME. Effect of pulsed radio frequency stimulation on wound healing: a double-blind pilot clinical study. *Electricity and magnetism in biology and medicine*. 1999; 875-78.