

## Cement less ceramic on ceramic total hip replacement for idiopathic osteonecrosis in young patients. Is it the best solution?

Amr I. Zanfaly<sup>1</sup>, Adel Abdel Azim<sup>2\*</sup>

<sup>1,2</sup>Lecturers of Orthopaedic Surgery Faculty of Medicine Zagazig University

\*Corresponding Author:

E-mail: a4\_sf@hotmail.com

### Abstract

**Background:** Management of idiopathic osteonecrosis of the femoral head with arthritis in the young age group is controversial. Total hip replacement is considered the gold standard for management of arthritic hip. However, the longevity of the prosthesis and the number of future revisions are still the main source of concern about total hip replacement in this age group. The use of ceramic on ceramic bearing couples improved the longevity of the prosthesis

**Patients and methods:** In the period from June 2010 – to December 2012, 18 patients (22 hips) with idiopathic osteonecrosis of the femoral head were treated by cement less ceramic on ceramic total hip replacement. This study was done at Zagazig university hospitals. The mean age was 29.5 years old. There were 14 males and 4 females. The mean follow up period was 48.4 months. All cases had idiopathic osteonecrosis of the femoral head stage III and IV according to Ficat classification. The functional results were evaluated according to Harris hip score. The radiological results of the femoral and acetabular components following surgery were evaluated according to the criteria of Lins et al and Engh et al., respectively.

**Results:** The mean Harris hip score improved from 39.36 (range 30-56) preoperatively to 89.59 (range 68-96) in the final controls ( $p < 0.001$ ). Fourteen cases had excellent score, four good, three fair, and one patient had poor score. Patients in the zone from good to excellent represented about 80% from total number of cases. Radiolucency was observed around two acetabular components at 36 months follow-up, it was mildly progressive at 60 months follow-up in one case and the other one developed loosening at 48 months follow up for whom, revision was done at 50 months. Two stems were associated with a radiolucent line at 48 months follow-up. Their progression was not sufficient to conclude that there was any loosening at 60 month follow-up.

**Conclusion:** The results of cementless total hip replacement with ceramic on ceramic bearing surfaces are promising for young patients with idiopathic osteonecrosis of the femoral head at 5 years follow up. Longer - term follow up is recommended.

**Keywords:** Idiopathic osteonecrosis of the femoral head, Cementless total hip replacement, ceramic on ceramic total hip replacement.

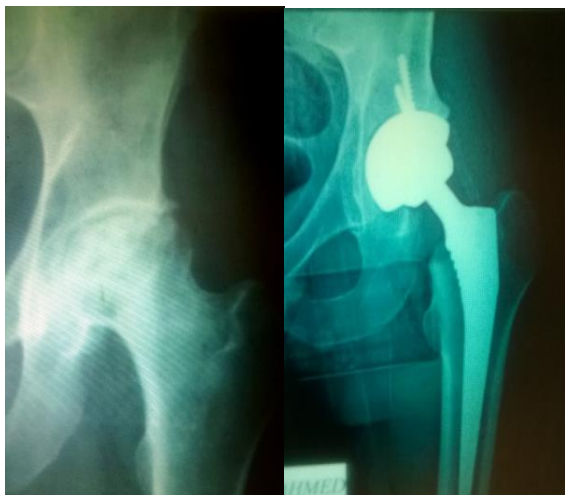Access this article online	
Quick Response Code:	Website: <a href="http://www.innovativepublication.com">www.innovativepublication.com</a>
	DOI: 10.5958/2395-1362.2016.00001.3

### Introduction

Several methods were tried for management of idiopathic osteonecrosis of the femoral head. The best treatment affords long lasting painless hip joints with functional range of motion. Total hip replacement is the gold standard for treatment of arthritic hip, but the main problem of replacement surgery is the longevity of the prosthesis. Unfortunately idiopathic osteonecrosis of the femoral head affects relatively young persons, so the main concern in total hip replacement in those patients is to increase the longevity of the prosthesis and to decrease the number of future revisions. The use of the current ceramic on ceramic bearing couples with minimal wearing properties compared with other bearing surfaces is promising for young patients undergoing total hip replacement<sup>1</sup>.

### Patients and methods

From June 2010 to December 2012, 22 cases (18 patients) with idiopathic osteonecrosis of the femoral head were operated with cement less ceramic on ceramic total hip replacement (**Fig. 1**). This study was carried out at Zagazig University Hospitals. The mean age was 29.5 years old (Range 18 to 39). Fourteen patients were unilateral while 4 patients were bilateral. Fourteen cases were males while four cases were females. Clinically all cases were complaining of disabling hip pain interfering with ordinary daily activities even with comfortable sleep. There was marked restriction in hip motions, flexion and adduction deformity in all cases and limb length discrepancy of more than 3 cm in 5 cases. Radiologically plain x- ray showed Ficat<sup>2</sup> stage III in 7 cases and stage IV in 15 cases. The mean follow up period was 48.4 months (Range 36 to 60 months). The functional results were evaluated according to Harris hip score<sup>3</sup>. The mean preoperative score was 39.36 (range 30-56). Radiographically the acetabular and femoral components were evaluated according to the criteria of Lins<sup>4</sup> et al and Engh<sup>5</sup> et al., respectively.



**Fig. 1:** pre and post operative x-rays of one case

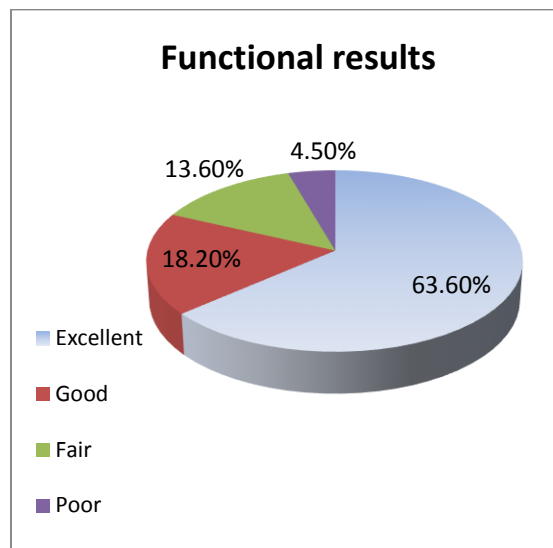
Surgery was done in the lateral decubitus under spinal anaesthesia for all cases. All operations were done through the lateral approach (Harding); the anterior capsule was excised in all cases. The prosthesis used in all cases was ceramic on ceramic (Zimmer Co. Inc.), the femoral component was inserted with a press fit technique while the acetabular component was secured with two screws at least in all cups. Prophylaxis against deep venous thrombosis was done for every case. Indomethacin was used with a dosage of 25 mg b.i.d. for 7 days for prophylaxis against heterotopic ossification. Exercises were started on the first postoperative day. Patients started partial weight bearing on the operated extremity with axillary crutches on the 2<sup>nd</sup> postoperative day. Full weight bearing without crutches was possible by the end of the 3<sup>rd</sup> month.

## Results

Patients' results were evaluated in terms of functional and radiological postoperative results throughout the follow up period and complications either operative or post-operative.

**Functional results:** There was improvement in the Harris hip score, the mean preoperative score increased from 39.36 (Range 30-56) to 89.59 (Range 68-96) in the final controls. Fourteen cases (63.6%) had excellent score, four cases (18.2%) were good, three cases (13.6%) were fair and only one case (4.5%) had poor results (Fig. 2). It was found that the increase in Harris hip score was significant ( $p < 0.001$ ). Patients who had good to excellent results, (Harris hip score  $\geq 80$ ) showed marked pain relief, improvement in limb function and range of motion. These 18 cases (14 excellent and 4 good) attained a pain score of 44 (complete relief of pain) after six months of surgery except one good case who had pain score of 30. The range of motion was improved in all the patients in the final controls as compared to preoperative period. Hip flexion improved from 70° (Range 50°-90°) to

110° (Range 90°-130°), internal rotation increased from 15° (Range 10°-20°) to 30° (Range 25°-35°), external rotation improved from 25° (range 20°-35°) to 40° (Range 35°-45°), abduction improved from 25° (Range 20°-30°) to 45° (Range 40°-50°), and adduction increased from 15° (Range 10°-20°) to 30° (Range 25°-35°).



**Fig. 2:** Functional results according to Harris hip score

## Radiographic results:

Femoral Stem was in a central position in 17 cases, valgus position found in two cases, and varus position present in three cases. The acetabular cup position measurements were found within normal in every case. The mean cup angle was 45° (Range, 35° to 55°); cup height 25 mm (Range, 20 to 30 mm); and cup medialization distance was 30 mm (Range, 20 to 40 mm). Radiolucency was observed around the acetabular component of two cases (9.1 %) in the form of radiolucent lines in zones (II & III) at 36 months follow-up and it was mildly progressive at 60 months, follow-up in one case and the other one developed loosening of the acetabular component at 48 months follow up, the radiolucent zone around his acetabular component was 2 mm in width, and the patient had pain on weight bearing relieved by rest and aggravated by rotation of the hip. An antalgic gait was developed. This was revised at 50 months from the initial THA after exclusion of infection. This patient had 69 Harris hip score before undergoing revision surgery; we considered revision as an end point of follow up. Two stems were associated with a radiolucent line, the 1<sup>st</sup> was in zone (I&II) and the 2<sup>nd</sup> was in zone (II & III) at 48 months follow-up and it was mildly progressive on serial radiographs at 60 months follow-up. This progression was not sufficient to conclude that there was any loosening.

As regard complications, there were no complications developed intra-operative. Only one case (4.54%) had superficial surgical site infection, this patient had a diabetes mellitus. Infection was managed in this case with antibiotics (Intravenous Third generation cephalosporin) and local wound care plus control of blood glucose level. The wound was cured within 19 days. Deep vein thrombosis developed in one case (4.54 %) after three weeks postoperative and managed medically. One patient (4.54 %) had limb length discrepancy of 2 cm shortening for which a compensatory shoe raise was used. Thigh pain was present in six cases (27.3 %) it was mild and non-limiting in four cases (18.2%) and moderate in two cases (9.1%). A sclerotic area around the tip of the femoral component was present in four cases with thigh pain. Sclerosis around the tip of the femoral component also happened in seven cases (31.8%) without thigh pain. Heterotopic ossification was seen in 2 cases (9.1 %) with Brooker grade 1. No dislocation had occurred during the follow up period. No statistically significant differences were found between patients with unilateral avascular necrosis and those with bilateral involvement as regards pre and postoperative hip scores ( $p > 0.05$ ).

## Discussion

Avascular necrosis (AVN) is a disease that may affect several bones as a result of temporary or permanent loss of the blood supply to these bones. The femoral head is the most commonly affected by this disease. AVN of the femoral head is one of the common causes of painful hip in a young adult. The disease usually affects patients in the third, fourth and fifth decade of life at the time of diagnosis<sup>6</sup>. Initially, patients are asymptomatic, but with time, AVN leads to progressive joint destruction with eventual advanced arthritic changes requiring surgical treatment<sup>7</sup>. The ideal treatment of AVN of the femoral head in young patients with head collapse or in the presence of advanced degenerative changes remains controversial. Core decompression, bone grafting and valgus osteotomy can be considered in early stages<sup>8</sup>. Cup arthroplasty has failed to give satisfactory results in late stages of femoral head osteonecrosis and proved to be unable to significantly postpone the necessity for total hip arthroplasty<sup>9</sup>. Arthrodesis may be considered for unilateral disease, but it has a limited role due to the high incidence of a bilateral disease in idiopathic avascular necrosis of the femoral head which reaches up to 40-70% of cases<sup>10</sup>.

Although the main goal of treatment in young patients is to preserve the normal bone stock, total hip arthroplasty is seen as the main therapeutic option in such cases of advanced stages, Ficat and Arlet stages III and IV<sup>11, 12</sup>. Unfortunately young patients with active lifestyle carry the risk of early loosening and repeated revisions. To overcome these problems; more durable bearing materials have been developed<sup>13</sup>.

The longevity of the implanted prosthesis is a major concern of total hip replacement surgery especially in young patients with active lifestyle. The primary threat to that longevity originates from wear of the bearing surfaces, resulting in production of periprosthetic wear debris, subsequent osteolysis, and eventual loss of fixation<sup>14</sup>. The absence of osteolysis is of great advantage for young patients, as revision surgery is expected even at a longer time, so preservation of bone stock is a very important consideration. A major challenge for total hip replacement surgery is to minimize wear and osteolysis in the young, active patients with high activity level. Advances in the design of bearing surfaces improved the longevity of hip replacement surgery to a great extent. This allows expansion of the indications for younger and more active patient population<sup>15</sup>.

The wear rates of alumina ceramics are less than those of polyethylene-on-metal and metal-on-metal couples. This is because alumina ceramics have extremely low coefficient of friction with superior wear resistance<sup>16</sup>. Alumina ceramics are extremely hard, scratch resistant, and stable at high temperatures, and their hydrophilic nature provides for improved lubrication over other bearing surfaces<sup>17</sup>. Alumina ceramic debris is less biologically reactive than particulate metal or polyethylene debris<sup>18</sup>. Alumina ceramic bearings have no potential for ion release, a distinct advantage over metal on-metal couplings<sup>19</sup>. These improvements in implant design hold great promise for prolonged fixation of implants, particularly in young and more active patients.

A major consideration about ceramic bearing couples is fracture. Early ceramics had insufficient purity, low density, and a coarsely grained microstructure, which resulted in less mechanical strength of the ceramic material<sup>20</sup>. Early experience with alumina-ceramic bearings was disappointing secondary to ceramic component fracture and accelerated wear, the current generation of alumina has addressed the problems of the earlier ceramics<sup>14</sup>. Current alumina ceramic material is of higher quality than earlier alumina ceramics and avoids the previous drawbacks of the earlier designs as higher rigidity.

Clinical and radiological outcomes following total hip replacement for osteonecrosis of the femoral head in the young age group favor cement less over cemented technique as regard longevity and easier revision. In addition, the cement less technique offers reduced operative time, preservation of more bone stock, and decreased rate of component loosening<sup>21</sup>. The early results of cement less THA are superior to cemented THA even with advances in cementing techniques<sup>22</sup>. Lins et al<sup>4</sup> reported after a mean follow-up period of 60 months that 81% of the femoral components, and 97% of the acetabular components were stable in the 37 hips with avascular necrosis they treated with cement less total hip arthroplasty.

In the literature the previous results of cement less ceramic on ceramic total hip replacement are very promising as regard longevity of the prosthesis and revision rates. Many authors reported no or minimal osteolysis at short and midterm follow up. In a study by Kim et al<sup>23</sup>, there was no osteolysis at a minimum of 10 years of follow-up in 93 hips performed in patients younger than 45 years. In another study done by Shetty et al<sup>24</sup>, they found survival rate of 88.9% in ceramic on ceramic bearings in 249 patients within 10 years follow up. In a long term study, 20 years follow up of 100 patients had primary total hip replacement with alumina ceramic on ceramic bearings<sup>25</sup>. The results of this study as regard osteolysis were very promising. The authors had loosening of five acetabular cups and the one complete prosthesis (the cup and femoral stem) otherwise there were no instances of either clinical or radiographic evidence of loosening. In the current study at 5 years follow up no osteolysis had been recorded.

The revision rates of the previous studies addressing the use of ceramic on ceramic couples in young patients are promising. In a study done by Patrick et al<sup>26</sup> 2012, in their short term follow up (averaging 4 years, 4 months) of 24 cases young than 20 years had total hip replacement using ceramic on ceramic bearing couples, they had a revision rate of 8% of cases. In another study done by Yoowanget al 2010<sup>27</sup> about cement less total hip arthroplasty with ceramic-on-ceramic bearing in patients younger than 45 years with femoral head osteonecrosis, they reported 0% revision of either of the femoral or the acetabular components at 11.1 years follow up if the cause of revision was attributed to aseptic loosening and 1% revision rate was reported in one case due to recurrent dislocated and needed revision of the acetabular component. In this study at 5 years follow up one case (4.5%) had revision due to aseptic loosening of the acetabular component.

## Conclusion

Ceramic-on-alumina ceramic bearing couples are functioning well with minimal complications at a 5-years follow up in this study. Ceramic bearings are recommended for young patients requiring total hip replacement. Longer – term follow up is necessary for more evaluation of the longevity of the prosthesis and the overall results.

## References:

1. Young-Hoo Kim, Yoowang Choi and Jun-Shik Kim. Cement less total hip arthroplasty with ceramic-on-ceramic bearing in patients younger than 45 years with femoral-head osteonecrosis. *IntOrthop*. 2010 Dec; 34(8): 1123–112.
2. Muhammad Umar Jawad, MD, Abdul Ahad Haleem, MD, and Sean P. Scully, MD, PhD. In Brief: Ficat Classification: Avascular Necrosis of the Femoral Head. *Clin Orthop Relat Res*. 2012 Sep; 470(9): 2636–2639.

3. Söderman P<sup>1</sup>, Malchau H. Is the Harris hip score system useful to study the outcome of total hip replacement? *Clin Orthop Relat Res*. 2001 Mar;(384):189-97.
4. Lins RE, Barnes BC, Callaghan JJ, Mair SD, McCollum DE: Evaluation of uncemented total hip arthroplasty in patients with avascular necrosis of the femoral head. *Clin Orthop* 1993;(297):168-73.
5. Engh CA, Bobyn JD, Glassman AH. Porous-coated hip replacement. The factors governing bone ingrowth, stress shielding, and clinical results. *J Bone Joint Surg [Br]*1987;69:45-55.
6. Ramesh Kumar Sen. Management of avascular necrosis of femoral head at pre-collapse stage *Indian J Orthop*. 2009 Jan-Mar;43(1):6–16.
7. Horia Bogdan MD, PhD; Valentin Cristescu, MD; Mihaela Dragusanu, MD Avascular necrosis of the femoral head a journal of clinical medicine, 2009, volume 4 No.1.
8. Fairbank C, Bhatia D, Jinnah RH and Hungerford DS. Long term results of core decompression of ischaemic necrosis of the femoral head. *J Bone Joint Surg* 1995;77:42-49.
9. Greclula MJ. Resurfacing arthroplasty in osteonecrosis of the hip. *Ortho Clin North Am*. 2005 Apr;36(2):231-42.
10. Garino JP and Steinberg ME. Total hip arthroplasty in patients with avascular necrosis of the femoral head. 2 to 10 years follow-up. *Clin. Ortho*. 1997;334:108-15.
11. Cabanela ME. Bipolar versus total hip arthroplasty for avascular necrosis of the femoral head. A comparison. *Clin Ortho* 1990;261: 59 - 62.
12. Chan YS, Shih CH. Bipolar versus total hip arthroplasty for hip osteonecrosis in the same patient. *Clin Ortho* 2000;379:169-77.
13. Simon J P, Berger P, Bellemans J. Total hip arthroplasty in patients less than 40 years old with avascular necrosis of the femoral head A 5 to 19-year follow-up study *Acta Orthop. Belg.*, 2011, 77, 53-60.
14. William N. Capello, MD, James A. D'Antonio, MD, Judy R. Feinberg, PhD, Michael T. Manley, PhD, z and Marybeth Naughton, BS. Ceramic-on-Ceramic Total Hip Arthroplasty: Update. *The Journal of Arthroplasty*. 2008, Vol. 23 No. 7 Suppl 1.
15. Papatheofanis F. Technology report: Prosthetic hip and knee arthroplasty.1994. University Hospital Consortium (UHC) Technology Advancement Center, Oakbrook, IL.
16. Fisher J, Besong AA, Firkins PJ, et al: Comparative wear debris generation in UHMWPE on ceramic metal on metal and ceramic on ceramic hip prostheses. Presented at 46th Annual Meeting, Orthopaedic Research Society, Orlando, FL, 2000.
17. Skinner HB: Ceramic bearing surfaces. 1999, *Clin Orthop* 369:83.
18. Clarke IC. Role of ceramic implants: design and clinical success with total hip prosthetic ceramic-to-ceramic bearings. *Clin Orthop*, 1992, 282:19.
19. James D'Antonio, MD, William Capello, MD, Michael Manley, PhD, and Benjamin Bierbaum, MD. New Experience with Alumina-on-Alumina Ceramic Bearings for Total Hip Arthroplasty, 2002. *The Journal of Arthroplasty* Vol. 17 No. 4.
20. Willmann G. Ceramic femoral head retrieval data. *Clin Orthop* 2000;379:22.
21. Bizot P, Nizard R, Socie G, et al. Femoral head osteonecrosis after bone marrow transplantation. *Clin Orthop* 1998:127.
22. Salvati EA, Cornell CN: Long-term follow-up of total hip replacement in patients with avascular necrosis. *AAOS Instr Course Lec* 1988;37:67.

23. Kim YH, Choi Y, Kim JS. Cement less total hip arthroplasty with ceramic-on-ceramic bearing in patients younger than 45 years with femoral-head osteonecrosis. *Int Orthop* 2010;34:1123.
24. Shetty V, Shitole B, Shetty G, Thakur H, Bhandari M. Optimal bearing surfaces for total hip replacement in the young patient: a meta-analysis. *Int Orthop* 2011;35:1281–7.
25. George E. Petsatodis, MD, Pericles P. Papadopoulos, MD, Kyriakos A. Papavasiliou, MD, Ippokratis G. Hatzokos, MD, Filon G. Agathangelidis, MD, and Anastasios G. Christodoulou, MD. Primary Cement less Total Hip Arthroplasty with an Alumina Ceramic-on-Ceramic Bearing Results After a Minimum of Twenty Years of Follow-up. *J Bone Joint Surg Am.* 2010;92:639-44.
26. Patrick R. Finkbone, MD, Eric P. Severson, MD, Miguel E. Cabanela, MD, and Robert T. Trousdale, MD. Ceramic-On-Ceramic Total Hip Arthroplasty in Patients Younger Than 20 Years. *The Journal of Arthroplasty*, 2012. Vol. 27 No. 2.
27. Young-Hoo Kim,<sup>1,2</sup> Yoowang Choi,<sup>1</sup> and Jun-Shik Kim Cement less total hip arthroplasty with ceramic-on-ceramic bearing in patients younger than 45 years with femoral-head osteonecrosis. *Int Orthop.* 2010 Dec;34(8):1123–1127.