

Evaluation of Different Modalities of Osteosynthesis of Proximal Humerus Fractures in Adults

Arpit Tiwari¹, Rahul Sinha^{2,*}, Mustafa Johar³, Akanchha⁴

^{1,2}Assistant Professor, ³Professor, ⁴P.G. Student, Dept. of Orthopaedics, Index Medical College, Hospital and Research Centre, Indore, M.P.

***Corresponding Author:**

E-mail: rahulsinha2185@gmail.com

Abstract

Background: Proximal humerus fractures account for approximately 4-5% of the fracture attendance at the hospital. The management of proximal humeral fractures has always been an enigma because of numerous muscles attachment and paucity of space for fixing the implant. The objective of the present study was to compare different modalities of fixation in proximal humerus fractures.

Methods: This is a retrospective study done on 112 patients of acute proximal humerus fractures treated surgically. Follow up was done for 12 months and results were analysed using Neer's scoring system.

Results: Radiological union occurred at average time of 10.1 weeks. As per Neer's scoring system, 36% patients had excellent results while 31% patients had satisfactory results. They were all pain free and successfully returned to their pre-injury work. 25% patients had unsatisfactory and 8% failure result. 2 patients required revision surgery.

Conclusion: Treatment options depend on fracture pattern, bone quality, patient's goals and surgeon's familiarity with the technique. Patients who have two part greater tuberosity avulsion fracture are best treated by closed reduction and percutaneous screws fixation. Patients who have metaphyseal comminution and/or three-part fracture with appreciable displacement of the greater tuberosity are more appropriately treated by open reduction and Internal fixation with a plate.

Key Words: Osteosynthesis, Proximal humerus fractures, Internal fixation.

Access this article online	
Quick Response Code:	Website: www.innovativepublication.com
	DOI: 10.5958/2395-1362.2016.00005.0

Introduction

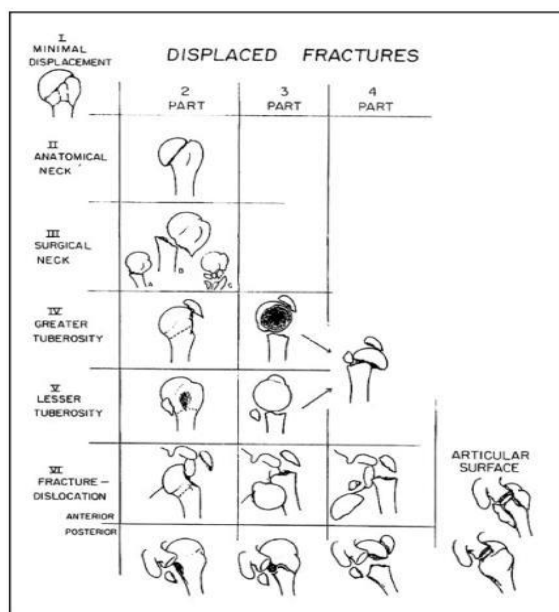
Proximal humerus fractures are one of the commonest fractures occurring in the skeleton. They account for approximately 4 - 5% of the fracture attendance at the hospital. Voluminous literature is available on this topic and treatment patterns differ very much. The preferred treatment varies depending on the patient's age and bone quality, the expertise of the surgical team and the patient's expectations. Although a number of report have described the outcome of treatment of proximal humeral fractures, comparison of these studies is hampered by inconsistency in fracture classification, treatment and evaluation method.

Neer's Classification

This study tries to bring out the salient features of all operable fractures of proximal humerus which require fixation especially in adult patients in whom the duration of stay in hospital affects the earning capacity of the person and in elderly patients in whom immobilization of upper limb is associated with reflex sympathetic dystrophy, stiffness and shoulder hand

syndrome, thus the requirement of early mobilization without any undue risk of loss of fixation and reduction.

In this study, we aim to study the occurrence, mechanism of injury and displacement of various types of fractures and to compare the results of different modalities of fixation in proximal humerus fractures.



Materials and Methods

This retrospective study was performed at Index Medical College, Hospital and Research Centre

(IMCHRC) from July 2011 to June 2015 on 112 patients of acute proximal humerus fractures.

Inclusion Criteria:

All adult patients admitted with proximal humerus fractures. [Neer's classification: grade 2 to grade 4].

Exclusion Criteria:

- A. Medically unfit patients.
- B. Pathological fractures.
- C. Fractures in paediatric age group.
- D. Shaft humerus fractures with proximal extension.
- E. Compound fractures.
- F. Neurovascular damage.

After thorough history and examination, radiographic evaluation and pre-anaesthetic check-up was done.

Method of Treatment

All patients were operated on elective basis after overcoming the avoidable anaesthetic risks. All patients were treated by one of the following methods.

1. Closed reduction and Percutaneous K-wires fixation.
2. Closed reduction and Percutaneous Screws fixation.
3. Open reduction and Internal fixation with Proximal humeral interlocking osteosynthesis (PHILOS) plate.

Young patients, patients with good compliance, good bone quality, 3-4 part fractures, fractures with metaphyseal comminution were taken for plating; greater tuberosity fractures, 2 part fractures, patients with co morbidities were taken for percutaneous screws and patients with undisplaced 2/3/4 part fractures, poor bone quality, elderly patients unfit for open reduction and internal fixation were taken for K-wire fixation.

Surgical Techniques

Percutaneous K-Wire Fixation after Closed Reduction

General anaesthesia was given and closed reduction was performed under image intensifier control. We passed 2 pins from greater tuberosity aiming for medial cortex of the shaft and 1 from lateral cortex of the shaft to the humeral head.

Open Reduction and Locking Plate Fixation (PHILOS)

Position: We employed the beach chair position.

Approach: We used the standard delto-pectoral approach. Cephalic vein was isolated and retracted medially with pectoralis major. The conjoint tendon was retracted medially to avoid injury to the musculocutaneous nerve. The axillary nerve was localized in the subdeltoid and subcoracoid spaces by gently sweeping the finger in a proximal – distal

fashion. The long head of biceps tendon was localized distally under the insertion of the pectoralis major muscle and followed proximally to locate the rotator internal. Care was taken to avoid excessive soft tissue stripping to maintain blood supply of the humeral head. Head fragments were reduced and checked under image intensifier. Reduction was fixed with K-wires. Ethibond suture fixation was done to prevent tuberosity migration. The plate was positioned at least 8 mm distal to the upper end of greater tuberosity (rotator cuff insertion). Now fixation was done with locking and concealing screws in head and locking or simple cortical screws in shaft of humerus. Drill sleeve was used for locking screw placement. The wound was thoroughly washed and standard closure done after putting a suction drain, to be removed 24-48 hours later.

Closed Reduction and Percutaneous Screw Fixation

We used percutaneous screw fixation for fractures of greater tuberosity. Reduction was achieved under image intensifier control. Temporary fixation was done with K-wire. Two guide wires were passed across the fracture site. Now two 4 mm cannulated cancellous screws were inserted over the guide wires to fix the fractures.

Postoperative Rehabilitation: We followed the protocol advised by Neer C.S. II. This was carried out in three stages.

First phase (7 days – 6 weeks): Passive assistive (pendulum exercises), passive elevation, assistive pulley exercises, external rotation with stick.

Second phase (till 3rd month): Active and early resistive, terminal elevation, stretching against wall, abduction external rotation.

Third phase (after 3 months): Stretching and strengthening (internal rotation stretch, external rotation, isometric abduction, isometric internal rotation, abduction resistive external and internal rotation)

Results

Proximal humeral fractures were more common in men with a gender distribution of 1.5: 1 and were also more common in the age group of 50 to 65 years (53%). The right side was affected more than the left. Domestic falls were the most common cause of fractures and involved the older age groups. Radiological union occurred at an average of 10.1 weeks (8-15 weeks).

Neer's type of fracture: Two part fractures constituted the most common type.

Table 1: Neer's type of fracture

Types of Fixation	No. of Patients	Percentage
Two part fracture	43	38
Three part fracture	47	42
Four part fracture	22	20
Total	112	100

Types of fixation for proximal humerus fractures:

Most proximal humerus fractures were fixed with open reduction and plate fixation. Others were treated with either close reduction and percutaneous k-wires fixation or close reduction and percutaneous screws fixation.

Table 2: Fixation of Proximal Humerus Fractures

Types of Fixation	No. of Patients	Percentage
Closed reduction and percutaneous k-wires fixation	29	26
Closed reduction and percutaneous screws fixation	35	31
Open reduction plate fixation	48	43
Total	112	100

End Result: Neer's scoring system of severity of Pain, Function, Range of Movement and Anatomy was done to determine the end results. Clinical and radiological follow up was done in immediate post op period, at 4 weeks, 8 weeks, 12 weeks, 6 months and 12 months.

The end results of 112 patients of proximal humerus fractures which were surgically treated could be categorized as:-

Table 3: End result of percutaneous screw fixation

Grading	No. of Patients	Percentage
Excellent	0	00
Satisfactory	18	51
Unsatisfactory	8	23
Failure	9	26

Table 4: End result of percutaneous k-wires fixation

Grading	No. of Patients	Percentage
Excellent	04	14
Satisfactory	06	21
Unsatisfactory	19	65

Table 5: End result of open reduction and plate fixation

Grading	No. of Patients	Percentage
Excellent	36	75
Satisfactory	11	23
Unsatisfactory	1	2

Table 6: Overall results on basis of Neer's Scoring System

Grading	No. of Patients	Percentage
Excellent	40	36
Satisfactory	35	31
Unsatisfactory	28	25
Failure	9	8

Table 7: Results according to Neer's different types of fracture on the basis of Neer's Scoring System

Type of Fracture	Total	Excellent	Satisfactory	Unsatisfactory	Failure
Two part fracture	43	18	20	01	04
Three part fracture	47	20	04	18	05
Four part fracture	22	02	11	09	00

The results show that most patients with Neer's two part fracture had excellent to satisfactory results.

Table 8: Comparison of overall end results between the three groups

	Total	Excellent	Satisfactory	Unsatisfactory	Poor
Screw fixation	35	0	18	8	9
K wire fixation	29	04	06	19	0
Plate fixation	48	36	11	1	0

Complications

6 patients had subacromial impingement in PHILOS group due to cranial position of plate. 1 patient required plate removal. 1 patient developed 2 mm screw penetration in humeral head at 8 weeks follow up which also required screw removal. 3 patients developed superficial infection which was controlled with antibiotics. 2 patients developed osteonecrosis - 1 in PHILOS group and 1 in percutaneous screw group

but they were asymptomatic clinically and are on close follow up.

Statistical analysis

Data analysis was done using IBM SPSS Statistics 20. Chi-square test was applied to determine the significance of the outcome. p-value was <0.05 signifying strong statistical significance of results.

Table 9: Case Processing Summary

	Cases					
	Valid		Missing		Total	
	N	%	N	%	N	%
Fracture type * Results	112	100.0%	0	0.0%	112	100.0%
Treatment * Results	112	100.0%	0	0.0%	112	100.0%
Fracture type *Treatment	112	100.0%	0	0.0%	112	100.0%

Fracture type * Results**Table 10: Crosstab**

		Results				Total	
		A	B	C	D		
Fracture type	2	Count	18	20	1	4	43
		% within Results	45.0%	57.1%	3.6%	44.4%	38.4%
	3	Count	20	4	18	5	47
		% within Results	50.0%	11.4%	64.3%	55.6%	42.0%
	4	Count	2	11	9	0	22
		% within Results	5.0%	31.4%	32.1%	0.0%	19.6%
Total	Count	40	35	28	9	112	
	% within Results	100.0%	100.0%	100.0%	100.0%	100.0%	

Chi-Square Tests

	Value	df	Asymp. Sig. (2-sided)
Pearson Chi-Square	35.538 ^a	6	.000
Likelihood Ratio	46.539	6	.000
N of Valid Cases	112		

a. 3 cells (25.0%) have expected count less than 5. The minimum expected count is 1.77.

Treatment * Results**Table 11: Crosstab**

		Results				Total	
		A	B	C	D		
Treatment	1	Count	36	11	1	0	48
		% within Results	90.0%	31.4%	3.6%	0.0%	42.9%
	2	Count	4	6	19	0	29
		% within Results	10.0%	17.1%	67.9%	0.0%	25.9%
	3	Count	0	18	8	9	35
		% within Results	0.0%	51.4%	28.6%	100.0%	31.2%
Total	Count	40	35	28	9	112	
	% within Results	100.0%	100.0%	100.0%	100.0%	100.0%	

Treatment 1- PHILOS, 2-K wires, 3-Percutaneous screws

Chi-Square Tests

	Value	df	Asymp. Sig. (2-sided)
Pearson Chi-Square	92.797 ^a	6	.000
Likelihood Ratio	103.114	6	.000
N of Valid Cases	112		

a. 3 cells (25.0%) have expected count less than 5. The minimum expected count is 2.33.

Fracture type* Treatment**Table 12: Crosstab**

			Treatment			Total
			1	2	3	
Fracture type	2	Count	14	6	23	43
		% within Treatment	29.2%	20.7%	65.7%	38.4%
	3	Count	20	15	12	47
		% within Treatment	41.7%	51.7%	34.3%	42.0%
	4	Count	14	8	0	22
		% within Treatment	29.2%	27.6%	0.0%	19.6%
Total		Count	48	29	35	112
		% within Treatment	100.0%	100.0%	100.0%	100.0%

Chi-Square Tests

	Value	df	Asymp. Sig. (2-sided)
Pearson Chi-Square	21.410 ^a	4	.000
Likelihood Ratio	27.249	4	.000
Linear-by-Linear Association	14.434	1	.000
N of Valid Cases	112		

a. 0 cells (0.0%) have expected count less than 5. The minimum expected count is 5.70.

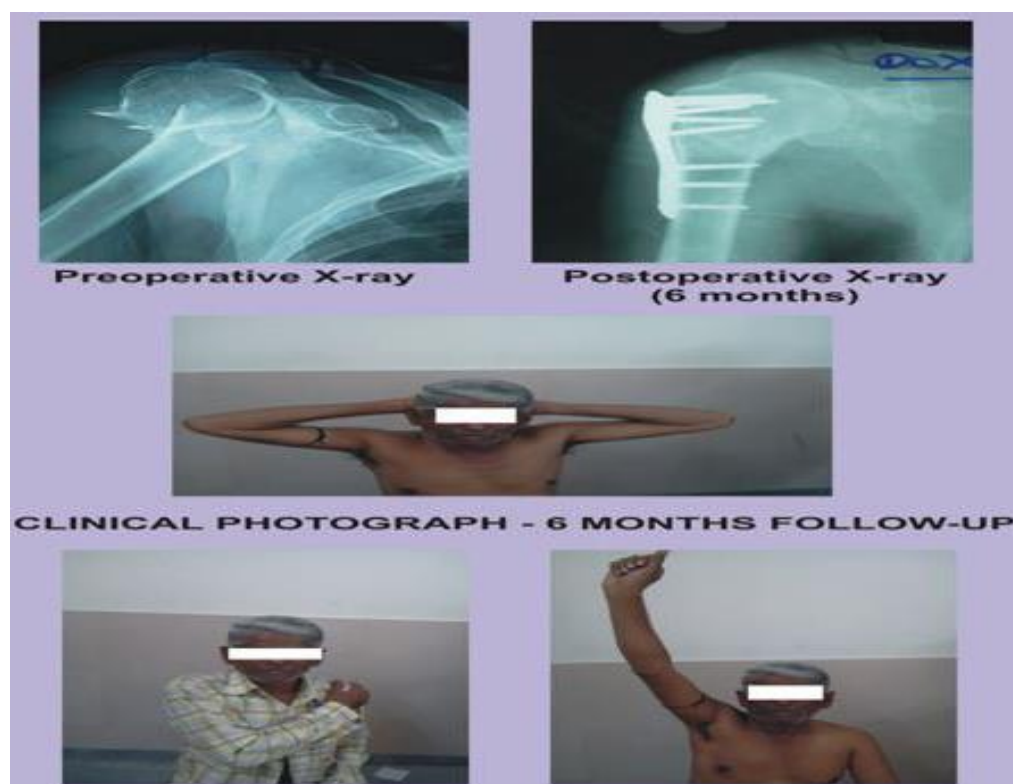

Fig. 1: Clinical and X-ray pictures of open reduction and internal fixation with PHILOS.

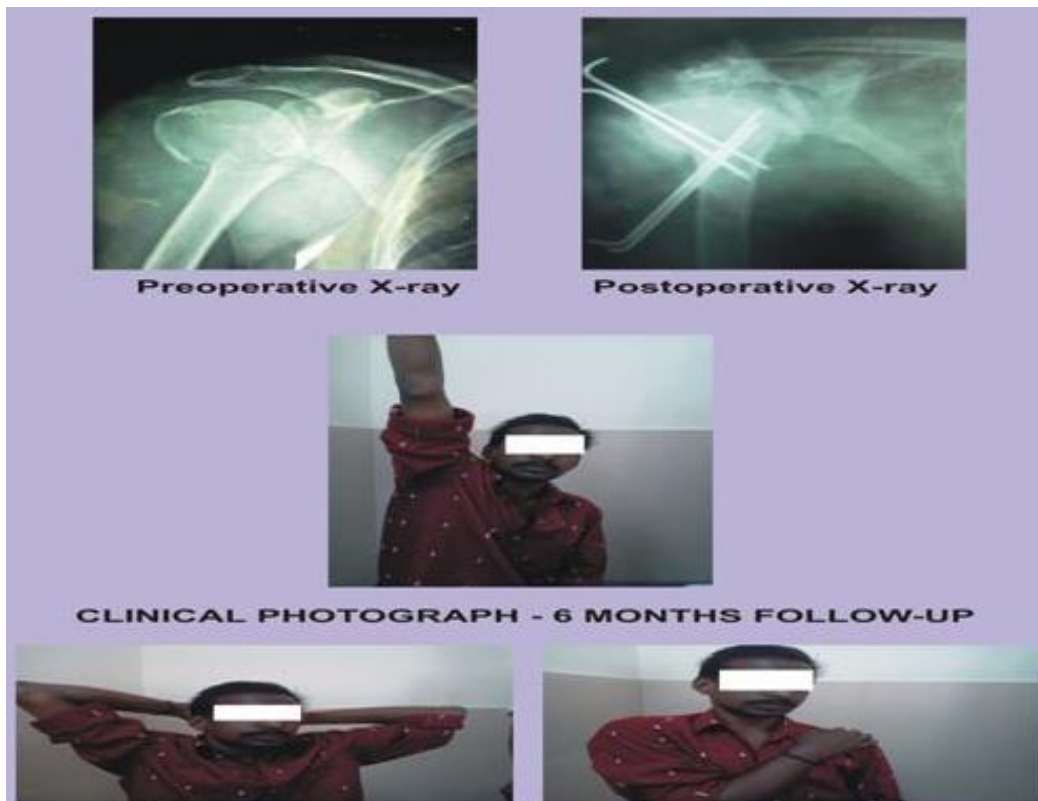

Fig. 2: Clinical and X-ray pictures of closed reduction and percutaneous K wire fixation.

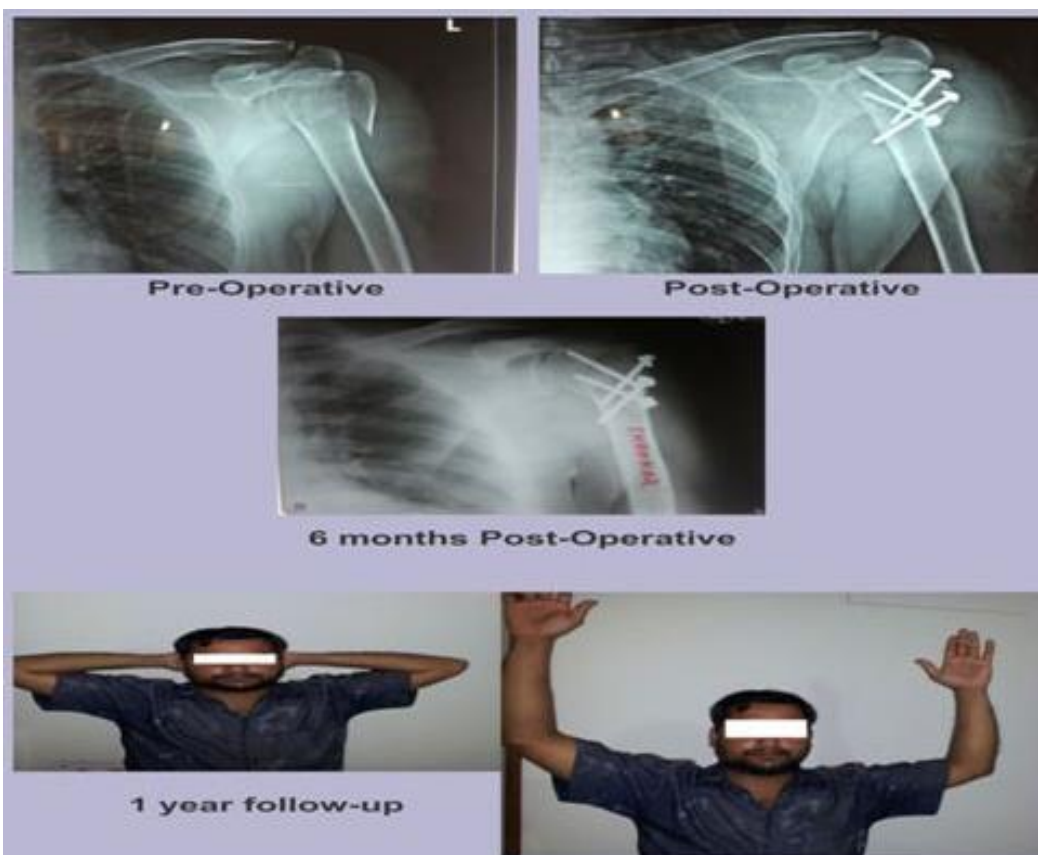


Fig. 3: Clinical and X-ray pictures of closed reduction and percutaneous suture fixation.

Discussion

The incidence of proximal humerus fractures has increased in last few years but the best management in these injuries is still uncertain. Historically conservative management was considered better than surgical intervention (Young et al 1985) but that may be due to unavailability of better plates and fluoroscope. However, with the introduction of angular stable plates, functional results after surgery have improved and are comparable with our study (Gerber et al, Geran et al, Brian et al).

It is very important to achieve near anatomical reduction before inserting the implant. If adequate reduction is not achieved and medial buttress is insufficient, secondary loss of reduction is possible.

Different studies which have used Neer's scoring system for assessment of results, demonstrate a fairly similar pattern of results with 70 - 80% patients having satisfactory to excellent results and 20 - 30% having un-satisfactory to failure results.

Table 13: Overall results on basis of Neer's Scoring System

Grading	Roland P. Jacob	Present Series
Excellent	21%	36%
Satisfactory	53%	31%
Unsatisfactory	10%	25%
Failure	16%	8%

Jaberg H, Warner JJ and Jakob RP (1992) in their study on percutaneous pinning of unstable fractures of the proximal end of the humerus found that results were good or excellent in thirty-four patients (71%), fair in ten (21%) and poor in four (8%). We have found excellent to satisfactory in 10 patients (35%) and fair in 19 patients (65%). The difference in results may be due to the follow up period. Jaberg et al. had a follow up of 7 years (average 3 years) while we have only 1 year follow up results.

Resch et al (1997) did a study on percutaneous screw fixation in 3 and 4 part proximal humeral fractures and found very good results comparable to our study.

Harrison et al (2012) did a study on percutaneous fixation for proximal humeral fractures and prevalence of osteonecrosis and found the prevalence to be 26%. They also found post traumatic arthritis in 37% patients. We observed only 1 case of osteonecrosis and no case of arthritis but it could be due to the fact that our study duration was 12 months as compared to 128 months in the study of Harrison et al.

Not many studies have been done on this topic in Indian patients with a medium sample size. Banshiwal et al did a study on PHILOS plating but used a different score and Siwach et al had a small sample size.

We had only one case of avascular necrosis of humeral head in PHILOS group which was

asymptomatic clinically (1.3%). Banshiwal et al found similar results. It is much less than 6-10% reported by Frankhauser et al and Kettler et al. As we did not obtain MRI routinely, the true prevalence may have been higher.

Screw penetration in head is a dreaded complication of PHILOS plating. Though we did not have any screw protrusion at the time of surgery as we used fluoroscopy in all cases, 1 patient had 2mm penetration at 8 weeks follow up due to varus subsidence. He later required screw removal but did not have clinically worse outcome. Our study size was insufficient to draw any conclusion regarding this difference.

6 patients with initial tuberosity migration of >5 mm had mechanical subacromial impingement with decreased initial range of motion (1 required plate removal) but the final score was not discernibly different from those with <5 mm displacement. Again our study size was insufficient to draw any conclusion regarding this difference.

Major limitations of our study were modest sample size, short follow up period and relatively costly PHILOS plate compared to conventional plates. Further research in the field is needed to evaluate long term effectiveness, rate of complications and safety.

Conclusion

Fractures of the proximal humerus are complex injuries involving two articulating surfaces, the glenohumeral joint and the subacromial arch. The options of management modality depend on the pattern of the fracture, the quality of the bone encountered, the patient's goals and the surgeon's familiarity with the techniques. Principle of fixation is reconstruction of the articular surface, restoration of the anatomy, stable fixation, minimal injury to the soft tissues and preserving the vascular supply. Treatment options for these displaced fractures include closed reduction and percutaneous screws fixation (31% cases), closed reduction and percutaneous k-wires fixation (26% cases) and open reduction and internal fixation (43% cases). Biologically the technique of closed reduction and percutaneous pinning is good from the standpoint of retaining the vascularity of the humeral head. It can be used for un-displaced or displaced two, three or four part fracture of the proximal humerus without comminution. It can also be used in the elderly who are unfit for surgery. It can be useful as an alternative to open -reduction and internal fixation of un-displaced and displaced fractures of the proximal humerus. Patients who have two part greater tuberosity avulsion fracture are best treated by closed reduction and percutaneous screws fixation. Patients who have metaphyseal comminution and/or displaced fractures are more appropriately treated by open reduction and internal fixation with a plate. An adequate surgical

technique minimizes complications and an aggressive rehabilitation regime ensures the best possible result.

Competing interest': The authors declare that they have no competing interests'.

Acknowledgement: None.

References:

1. Anthony F. Depalma and Richards Cautilli. Fractures of the upper end of the humerus. Clin.ortho.20,1971:73-93.
2. Neer CS II, Rockwood CA: Fractures and dislocations of the shoulder, in Rockwood CA, Green DP (eds): Fracture in adults, Philadelphia, PA, Lippincott, 1984:675-721.
3. Wijnman, Roolker, Patt, Raaymakers, Marti. Open reduction and Internal fixation of three and four part fractures of the proximal part of the humerus. JBJS (Am).Nov.2002,84-A:1919-1920.
4. Campbell's operative orthopaedics. Fracture about proximal humerus in adults. 10th Ed., Vol – 3: 2990 – 2994.
5. Michael A. Wirth. Proximal humerus fractures. American Academy of Orthopaedic Surgeons, 2002:1-55.
6. Neer CS II: Displaced proximal humeral fractures: Part I. Classification and evaluation. J Bone Joint Surg Am 1970; 52:1077-1089.
7. Herscovici D Jr et al. Percutaneous fixation of proximal humeral fractures. ClinOrthop2000;375:97-104.
8. Kocalkowski A, Wallace WA: Closed percutaneous K-wire stabilization for displaced fracture of the surgical neck of the humerus. Injury 1990., 21:209-212.
9. Jaberg et al: Percutaneous stabilization of the unstable fracture of the proximal humerus. JBJS Am. 1992; 74:508-15.
10. Roland P. Jakob, et al: Four part valgus impacted fractures of the proximal humerus. JBJS Br. March 1991; 73-B:295-297.
11. Herbert Resch et al: Percutaneous fixation of the three and four part fractures of the proximal humerus. JBJS Br. March 1997; 79-B:295-299.
12. Esser RD Treatment of three and four part fractures of the proximal humerus with a modified Cloverleaf plate. J Orthop Trauma 1994; 8:15-22.
13. Chen CY et al: Closed management and percutaneous fixation of unstable proximal humerus fractures. J Trauma 1998; 45:1039-45.
14. Rowel DJ, Mc Grory JE: Percutaneous pinning of the proximal part of the humerus: An anatomical study. JBJS Am. 2001; 83:1695-99.
15. Bigliani LU, Flatow E.L. Fractures of the proximal humerus, In Rockwood CA, Matsen FA (eds): The Shoulder, ed. Philadelphia, PA, Saunders ; 1998: 337-389.
16. Hawkins et al: Internal fixation techniques for the proximal humeral fractures. Clin Orthop 1987; 223:77-85.
17. Kristiansen B, Christensen SW: Plate fixation of proximal humeral fractures. Acta Orthop Scand 1986; 57:320-323.
18. Neer CS II: Displaced proximal humeral fractures: Part II. Treatment of three and four part displacement. J Bone Joint Surg Am. 1970; 52:1090-1103.
19. Williams GR Jr, Wong KL: Two-part and three-part fractures: Open reduction and internal Fixation versus closed reduction and percutaneous pinning. Orthop Clin North Am 2000;31 :1-21.
20. C. Gerber, C. M. L. Werner, P. Vienne. Internal fixation of complex fractures of the proximal humerus. JBJS Br. 2004; 86-B: 848-853.
21. Evan L Flatow, Frances Cuomo, Michael, Seth, Stephen, Louis Bigliani. Open Reduction and Internal fixation of two part displaced fractures of the greater tuberosity of proximal part of the humerus. JBJS(Am).Sept. 91,73-A, No.8:1213 –1214.
22. Moonot P. et al. Early Results for treatment of three and four part fractures of the proximal humerus using the PHILOS plate system. JBJS Br.2007; 89-B :1206-1208.
23. Kannus P.et al: Osteoporotic fractures of the proximal humerus in elderly Finnish persons: Sharp increase in 1970-1998 and alarming projections for the new millennium. Acta Orthop Scand 2000; 71:465-470.
24. Lee SH, Dargent-Molina P, Breart G. Risk factors for fractures of the proximal humerus: Results from the EPIDOS prospective study. J Bone Miner Res:2002; 17:817-825.
25. Chun J, Groh G, Rockwood CA: Two-part fractures of the proximal humerus. J Shoulder Elbow Surg 1994; 3:273-287.
26. Green A, Izzi J Jr: Isolated fractures of the greater tuberosity of the proximal humerus. J Shoulder Elbow Surg 2003; 12:641-649.
27. Cuomo F, et al: Open reduction and internal fixation of two and three part displaced surgical neck fractures of the proximal humerus. J Shoulder Elbow Surg. 1992; 1:287-295.
28. Hawkins RJ, Bell RH, Gurr K. The three part fracture of the proximal humerus. JBJS Am 1986; 68:1410-1414.
29. Naranja RJ Jr, Lannotti JP: Displaced three- and four part proximal humerus fractures: Evaluation and management. J Am AcadOrthopSurg 2000; 8:373- 382.
30. Gerber C, Hersche O, Berberat C: The clinical relevance of posttraumatic avascular necrosis of the humeral head. J Shoulder Elbow Surg 1998; 7:586-590.