

Content available at: <https://www.ipinnovative.com/open-access-journals>

Indian Journal of Orthopaedics Surgery

Journal homepage: <https://www.ijos.co.in/>

## Original Research Article

# Percutaneous autologous bone marrow injection in the treatment of delayed union of long bone fractures after definitive fixation

Zaheer Parveez Islam<sup>1</sup>, Ujjal Kar<sup>1,\*</sup>, Abhinab Gogoi<sup>1</sup><sup>1</sup>Dept. of Orthopaedics, Assam Medical College and Hospital, Dibrugarh, Assam. Fax: India

## ARTICLE INFO

## Article history:

Received 05-11-2021

Accepted 11-12-2021

Available online 24-03-2022

## Keywords:

Delayed union

Long bone fractures

Definitive fixation

Bone marrow injection

## ABSTRACT

**Background:** The purpose of this study was to assess the results of percutaneous autologous bone marrow injection in the treatment of delayed union of long bone fractures after definitive fixation. It has been a gruelling job for the orthopaedic surgeons to deal with the delayed union after definitive fixation due to the lack of patient compliance for reoperation like classical bone grafting technique for delayed union and non-union, unfavourable fracture site morphology for external compression, post-operative surgical wound issues etc., The percutaneous autologous bone marrow injection is a reasonable choice in this scenario for the treatment of Delayed union of long bone fractures after definitive fixation.

**Materials and Methods:** The study was performed in the department of orthopaedics Assam Medical College and Hospital, Dibrugarh, Assam, India for a period of 2 years from July 2019 to June 2021. A total of 23 patients were taken with delayed union of long bone fractures after definitive fixation. These 23 patients were treated with percutaneous autologous bone marrow injection and followed up for 6 months.

**Results:** The results were evaluated on the basis of clinico-radiological criteria of union, and found to be excellent in 60.86% (14/23), good in 17.39% (4/23) and poor in 21.73% (5/23) cases.

**Conclusion:** The percutaneous autologous bone marrow injection provides cellular stimulation and promotes fracture healing without the necessity for opening the fracture site. Hence it is an effective method to bring about successful outcome of delayed union of long bone fractures after definitive fixation without adding any significant complication to the patient and the fracture site.

This is an Open Access (OA) journal, and articles are distributed under the terms of the [Creative Commons Attribution-NonCommercial-ShareAlike 4.0 License](https://creativecommons.org/licenses/by-nc-sa/4.0/), which allows others to remix, tweak, and build upon the work non-commercially, as long as appropriate credit is given and the new creations are licensed under the identical terms.

For reprints contact: [reprint@ipinnovative.com](mailto:reprint@ipinnovative.com)

## 1. Introduction

It is very challenging for the orthopaedic surgeons to deal with the delayed union and possible future non-union of fractures which may be caused by various factors like complex fracture patterns, compromised surrounding soft tissues, a short distal bone segment, mechanical instability of the fracture, compromised vascular integrity at the fracture site, long term use of NSAIDs and patient's biology or comorbidities even after employing standard fixation methods.<sup>1,2</sup> Various methods have been used to overcome this burden of delayed union such as traditional

bone grafting technique, electrical stimulation, ultrasound therapy, induce membrane technique, bone transport etc.<sup>3</sup> But, surgical treatment of delayed union with additional surgical fixation or bone grafting may further halt the union process by hindering the blood supply at the fracture site, compromising soft tissues, increasing risk for infections etc.<sup>2</sup>

All the stages of bone healing process require the interaction of cells and biologically active molecules, which are abundantly available in the bone marrow.<sup>1</sup> Thus the bone marrow contains the osteoprogenitor cells which are capable of forming new bone.<sup>2</sup> The osteogenic effect of marrow is related to cell density and the various studies in animal

\* Corresponding author.

E-mail address: [uk.ujjalakar@gmail.com](mailto:uk.ujjalakar@gmail.com) (U. Kar).

models reveal that marrow can induce osteogenesis when injected into animal non-union models.<sup>4</sup> But, there has been only a few case series reports of the use of autologous bone marrow injection in the treatment of delayed union. Since it is a simple and percutaneous procedure, it can be carried out in the minor OT without any skilled or expertise hands. It's a day care procedure not requiring hospital admission and the materials required for the procedure are very cost effective. The procedure does not require to open up the delayed union site, thus less chance of surgical site infection and no disturbance of already set union process and vascularity of the fracture site. It can prevent the future non-union by treating the current delayed union process.<sup>4</sup> Even if the procedure fails to deal with delayed union it will not incur a loss as it is a non-invasive procedure and there is still the chance to adopt other traditional methods to address this complication. Thus the percutaneous autologous bone marrow injection is a safe and effective procedure to treat the delayed union of long bone fractures after definitive fixation. The aim of this study is to evaluate the clinico-radiological outcome of autologous percutaneous bone marrow injection in the treatment of delayed union of long bone fractures after definitive fixation.

## 2. Materials and Methods

This case series study was carried out in the department of orthopaedics Assam medical college and Hospital, Dibrugarh, Assam, India from July 2019 to June 2021. A total of 25 long bone fracture patients fixed with internal and external fixation devices with delayed union were treated with percutaneous autologous bone marrow injections. All were adult patients with age group between 18-65 years and sex distribution was 19 males and 6 females. But, two male patients were excluded as one was lost to follow up while the other had a revision surgery, thus dropping the total number of patients from 25 to 23.

### 2.1. Inclusion criteria

1. Patients with delayed union of long bone fractures after definitive fixation.
2. Patients with adult age group (18-65 years).
3. All fractures with stable internal and external fixation devices.
4. Adequate soft tissue envelope around the fracture site.
5. Patients after all other methods of fracture compression being exhausted (like dynamisation, external compression etc.).

### 2.2. Exclusion criteria

1. Fractures with active infection.
2. Patients with pathological fractures.
3. Patients with comorbidities.

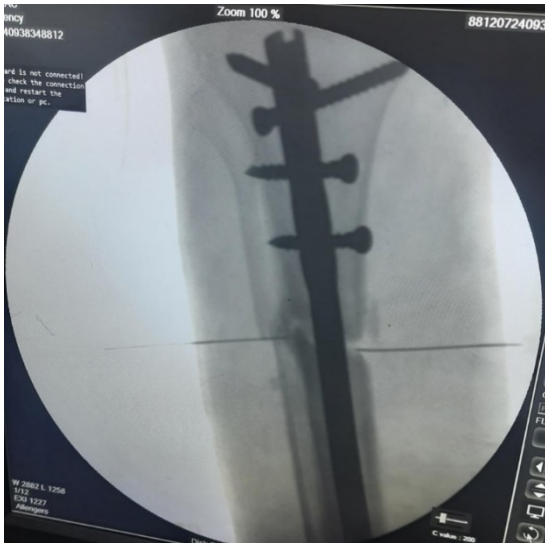### 4. Patients with neurovascular injury.

All routine pre-procedure investigations including the radiological investigations were done to rule out any active infection. Proper clinical and biochemical evaluation done for all the patients who met the inclusion criteria to rule out any co-morbidities affecting the progress of union. A written informed consent was taken from all the patients; they were fully explained about the whole procedure, cost of the procedure and complications of anaesthesia. All the percutaneous bone marrow injections were given in the operation theatre. The patient was placed in supine position, the fracture site and the graft site were prepped and draped separately to avoid cross contamination. The entire procedure was done under local infiltration of 2% lignocaine injection. Now an 18-gauge I.V cannula was inserted under fluoroscopic guidance into the site of the delayed union. A 16-gauge Thomas bone marrow aspiration needle<sup>5</sup> was inserted manually into the anterior iliac crest between the outer and inner table. The marrow was aspirated into a 10ml preheparinized plastic syringe with the needle always turned 45 degree for each aspiration. The marrow was aspirated in small fractions at a time (around 5ml) to reduce the degree of dilution by peripheral blood and to maximize the number of progenitors in the graft site. The aspirated bone marrow is then injected slowly (to limit cellular extravasation) into the previously marked site i.e. through the 18-gauge I.V cannula in the delayed union site. A compression dressing was given after the procedure and the patient was discharged on the same day. The same surgeon performed the bone marrow aspiration and injection into the graft site at all times. We injected 40-50 cc of bone marrows for femur and tibia, 20cc for humerus and 10cc for radius and ulna in all the cases of delayed union.<sup>3</sup>

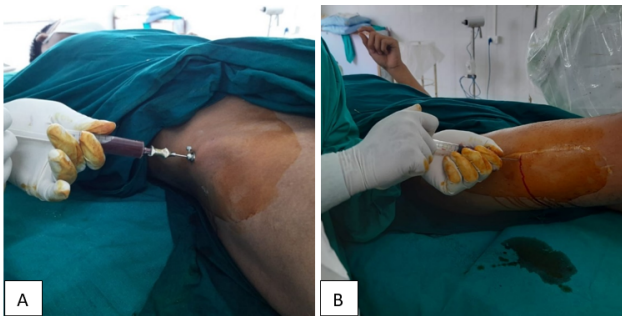
The patients were followed up at an interval of 3-4 weeks to assess the union clinico-radiologically. Clinico-radiological evaluation of the union was carried out by painless total weight bearing without macromobility at the fracture site with radiographic evidence of healing on at least 3 of the 4 cortices at the original fracture site as described by Heckman.<sup>6,7</sup> According to the criteria the results are graded as excellent when the fractures unites within 16 weeks of bone marrow injection, good when union occurs within 24 weeks and poor when union delay more than 24 weeks. After this procedure if the union is still not progressed then the patients were counselled for other methods to be adopted.

## 3. Results

In this case series study 25 patients with long bone fractures with delayed union were treated with percutaneous autologous bone marrow injections and followed up for a period of 6 months. Out of these 25 patients 1 patient was lost in the follow up and one had revision surgery. Hence, we



**Fig. 1:** Two 18G I.V. cannula was fixed into the delayed union site under fluoroscopic guidance.



**Fig. 2:** (a): Bone marrow aspiration from anterior iliac crest with 16G Thomas bone marrow aspiration needle and collected in 10ml pre-heparinised plastic syringe; (b): Bone marrow injection at the delayed union site with 18G I.V. cannula (which had been previously located under fluoroscopic guidance)

conducted the study only on 23 patients who were followed up on regular basis up to 6 months after giving bone marrow injection. 73.91% (17/23) patients were male and 26.08% (6/23) patients were female. 73.91% (17/23) had met with a road traffic accident, 21.73% (5/23) had a history of fall and 4.34 (1/23) had got injured from sports activity. The right sided fracture was 60.86% (14/23) and left sided was 39.13% (9/23). Out of these 23 patients, 39.13% (9/23, Gustilo and Anderson<sup>8</sup> type 1=4, type 2=1, type 3A = 2 and type 3B = 2) patients were open fractures and 60.86% (14/23) were closed fractures as given in Table 2. In this study 17.39% (4/23) had femur fractures, 39.13% (9/23) had tibia fractures, 17.39% (4/23) had humerus fractures, 17.39% (4/23) had radius fractures and 8.69% (2/23) had ulna fractures.

The patients were divided into three age groups according to their age for the simplicity, (Table 1). In this

study 47.82% (11/23) were having linear fractures, 39.13% (9/23) were comminuted fractures and 13.04% (3/23) were having segmental fractures. Out of the 23 cases 43.47% (10/23) were initially fixed with open reduction and internal fixations, 43.47% (10/23) had closed reduction and internal fixation and 13.04% (3/23) had open reduction and external fixation as given in Table 3.

The minimum time from injury to percutaneous autologous bone marrow injection was 3 months and maximum 6 months, with an average of 4.29 months. A few patients had some pain and discomfort at the donor site for a few days and subsided eventually. With this procedure, femoral fractures united in 100%(4/4) cases, tibia in 77.77%(7/9) cases, humerus in 50%(2/4) cases, radius in 75%(3/4) cases and ulna 100%(2/2) cases, given in Table 4.

As mentioned earlier we injected different amount of bone marrow injection for different bones and the results are as follows (Table 5)

The results were found to be excellent in 60.86% (14/23) cases, good in 17.39% (4/23) cases and poor in 21.73% (5/23) cases (Table 6)

#### 4. Discussion

Delayed union of a fracture is defined as no significant radiographic progression of healing for three consecutive months after injury.<sup>4</sup> There are different methods to address the delayed union, like use of demineralised bone matrix (DBM),<sup>9</sup> recombinant bone matrix protein (rhBMP),<sup>10,11</sup> platelet-rich plasma,<sup>12,13</sup> ultrasound,<sup>14</sup> extracorporeal shock waves,<sup>14</sup> the traditional autologous bone grafting which is also classically described as the gold standard in the treatment of non-union<sup>15</sup> etc. However, all these methods are relatively costly, time consuming, devoid of complication free and requires expertise hand to carry out. On the other hand, the method of autologous bone grafting carries the risk of serious morbidity of donor site and recipient site.<sup>16</sup> In our study we treated 23 cases of delayed union of long bone fractures with autologous bone marrow injection without any post-procedure serious complication. Out of the 23 cases, the primary surgery was done with open reduction and plate fixation for 4 cases of humerus fracture, 3 cases of radius fracture and one ulna fracture case. Close reduction and nail fixation was done for 2 cases of fracture shaft of femur, 6 cases of fracture tibia, one cases of radius and ulna fracture each. Open reduction and nail fixation was done for one open type 2 fracture shaft of femur and one open type3A fracture tibia. Open reduction and external fixation with Ilizarov fixator was done for two open type-3B fracture tibia cases. Open reduction and external fixation with LRS fixator was done for one open type-3A fracture shaft of femur.

The average union rate in our cases was 78.26% which is comparable with the average union rate of 65% and 62.2%

**Table 1:** Age and sex distribution in the study group (n=23)

Age (years)	Male	Female	Total	%
18-20	3	-	3	13.04
21-40	9	2	11	47.82
41-65	5	4	9	39.13
Total	17	6	23	100

**Table 2:** Type of fractures and their distribution (n=23)

Type of fracture	Overall number	Tibia	Femur	Humerus	Radius	Ulna
Closed fracture	14	4	2	3	4	1
Open type 1 fracture	4	2	-	1	-	1
Open type 2 fracture	1	-	1	-	-	-
Open type 3A fracture	2	1	1	-	-	-
Open type 3B fracture	2	2	-	-	-	-
Linear fracture	11	3	3	2	2	1
Comminuted fracture	9	4	1	2	2	-
Segmental fracture	3	2	-	-	-	1

**Table 3:** Types of initial fixation and their distribution (n=23)

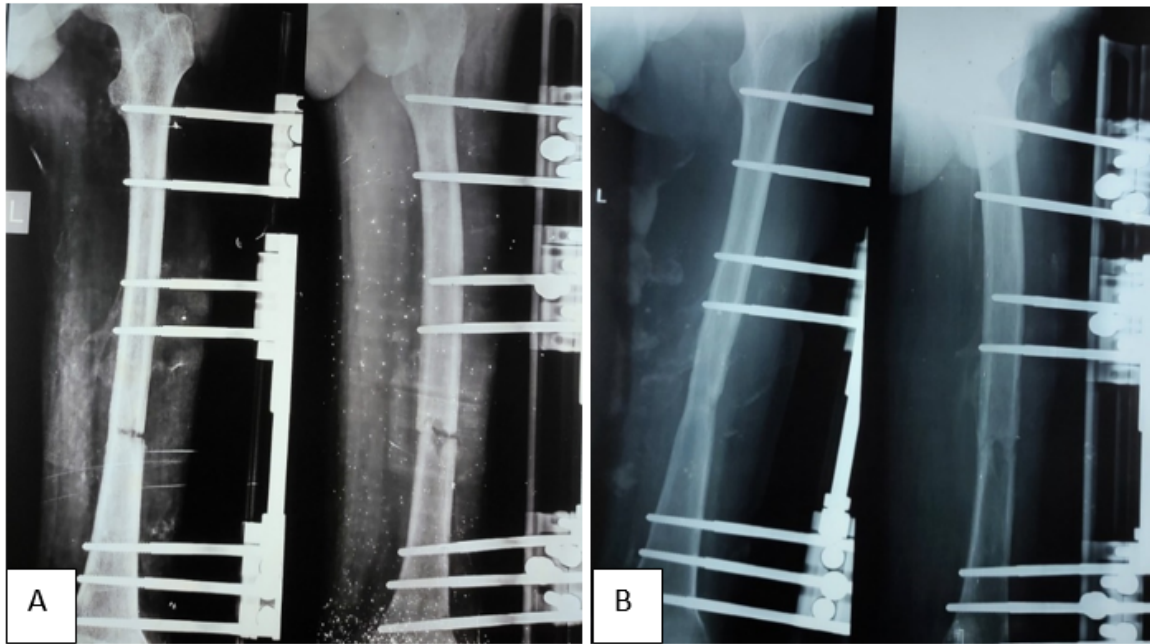
Type of fixation	Overall number	Tibia	Femur	Humerus	Radius	Ulna
Open reduction and internal fixation	10	1	1	4	3	1
Closed reduction and internal fixation	10	6	2	-	1	1
Open reduction and external fixation	3	2	1	-	-	-
Plate fixation	8	-	-	4	3	1
Nail fixation	12	7	3	-	1	1
Open reduction and internal fixation with nail	2	1	1	-	-	-

**Table 4:** Results according to individual bone (n=23)

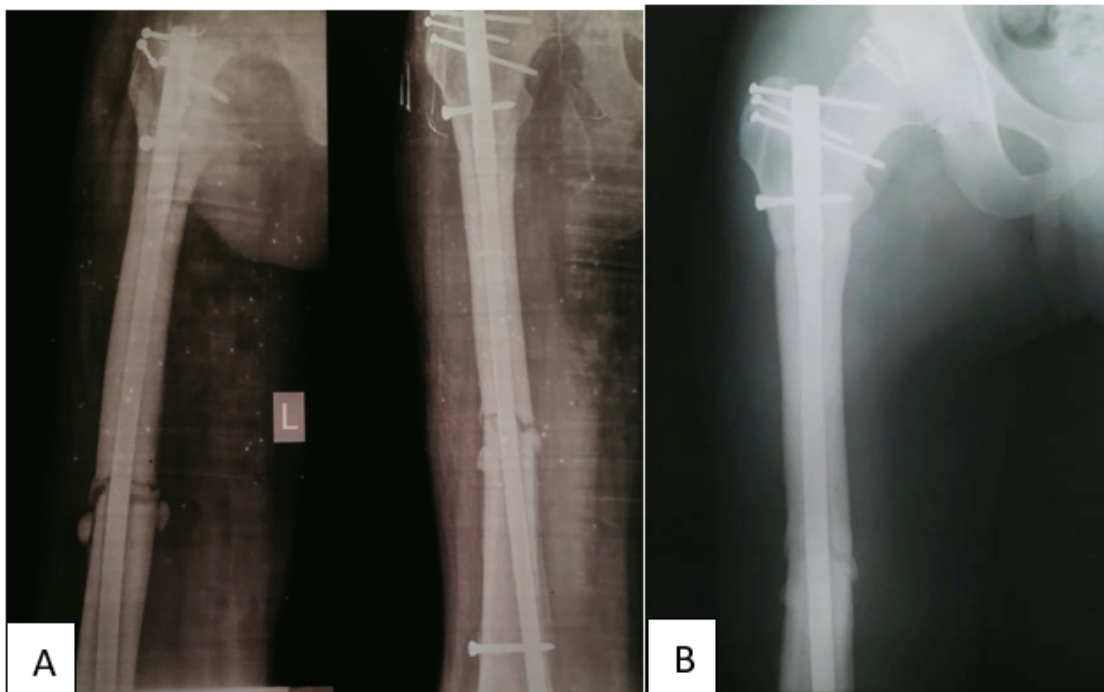
Bone	Number	United	%
Femur	4	4	100
Tibia	9	7	77.77
Humerus	4	2	50
Radius	4	3	75
Ulna	2	2	100

**Table 5:** Results according to the amount of bone marrow injection (n=23)

Bone	Amount of bone marrow injection(cc)	Number	United	%
Femur	<50 (>40)	4	4	100
	<40	0	-	-
Tibia	<50 (>40)	6	6	100
	<40	3	1	33.33
Humerus	<20	1	0	0
	>20	3	2	66.66
Radius	<10	3	2	66.66
	>10	1	1	100
Ulna	<10	2	2	100
	>10	0	-	-



**Fig. 3: Case No 1: a:** A 5 months old post-operative case of open type 3A fracture shaft of femur left side with LRS fixator in delayed union; (BMI given at 5 months after primary surgery) **b:** Union noticed after 2 months 10 days of giving bone marrow injection at the delayed union site



**Fig. 4: Case No 2: a:** A 4 and half months old fracture shaft of femur left side fixed with intramedullary interlocking nail for femur in delayed union; (BMI was given at 4 and half months after primary surgery) **b:** Union noticed after 3 months of giving bone marrow injection at the delayed union site

**Table 6:** Outcome of bone marrow injection (n=23)

Result	Number	%
Excellent	14 (T <sub>5</sub> , F <sub>3</sub> , H <sub>2</sub> , R <sub>2</sub> , U <sub>2</sub> )	60.86
Good	4 (T <sub>2</sub> , F <sub>1</sub> , R <sub>1</sub> )	17.39
Poor	5 (T <sub>2</sub> , H <sub>2</sub> , R <sub>1</sub> )	21.73

T= Tibia, F= Femur, H= Humerus, R= Radius, U= Ulna

**Table 7:** Comparison of results with other studies

Study and year	No. of bones studied	Union rate (%)
Jean-Baptiste Gross et al. <sup>6</sup> in 2015	41	62.2
Laurent Galois et al. <sup>15</sup> in 2009	-	65
Houston L. Braly et al. <sup>2</sup> in 2013	11	81.8
Ashok K Singh et al. <sup>17</sup> in 2013	12	83.33
Ramji Lal Sahu et al. <sup>3</sup> in 2017	93	88.17
John F. Connolly et al. <sup>4</sup> in 1989	10	90
Present study (Zaheer et al.)	23	78.26

in the study conducted by Laurent Galois et al.<sup>15</sup> and Jean-Baptiste Gross et al.<sup>6</sup> respectively.

The average union time in our cases was 3.53 months which is very similar with the average union time of 3 months (12 weeks) in the study conducted by Ramji Lal Sahu et al.<sup>3</sup>

The average time since injury to bone marrow injection was 4.29 months in our cases which is comparable with the average time of 4.1 months from injury to bone marrow injection as mentioned by John F. Connolly et al.<sup>4</sup> in their article.

In our study 43.47% patients presented to us with primary surgery of both open and close reductions with internal fixations, rest of the 13.04% presented with open reduction and external fixations which is considerably similar to the studies conducted by Ashok K Singh et al.<sup>17</sup> and Ramji Lal Sahu et al.<sup>3</sup>

In our study 17.39% patients presented to us with femur fractures, out of which 100% union rate with average union time of 3.35 months was achieved after bone marrow injection. On the other hand Joao Antonio Matheus Guimaraes et al.<sup>1</sup> found 50% union rate with average union time of 5 months after bone marrow injection in their study of 16 cases with femoral shaft non unions after locked intramedullary nailing.

We achieved 77.77% of union rate in tibia fractures after bone marrow injection with an average union time of 3.61 months which is somewhat comparable with the 90% union rate with an average union time of 4 months in the study conducted by John F. Connolly et al.<sup>4</sup> in their study of delayed union of tibia treated with autologous marrow injection.

We observed that adequate quantity of bone marrow injection is necessary for individual bones to achieve an effective outcome which is in accordance with the results drawn by Ramji Lal Sahu et al.<sup>3</sup>

In our study with percutaneous autologous bone marrow injection we achieved excellent results in 60.86% cases, good in 17.39% cases and poor in 21.73% cases which can be compared with the results found by Ramji Lal Sahu et al.<sup>3</sup> in their study.

Many studies revealed the good outcomes after using percutaneous bone marrow injection with composite graft in the treatment of simple bone cyst, congenital pseudoarthrosis of tibia and in the treatment of delayed union in difficult conditions like cancer patients.<sup>3</sup>

Park et al. and many others have established that with composite bone graft or with other ceramics the bone marrow injection is a valuable treatment option for the treatment of non-union, bone cyst etc.<sup>18–20</sup>

Laurent Galois et al.<sup>15</sup> mentioned that optimal results of bone marrow injection can be achieved if given at the period of delayed union rather than non-union which justifies our study.

John et al. in their study of autologous marrow injection for delayed unions of the tibia recommended that early bone marrow injection of high risk fractures offers an ideal preventive methodology to stimulate osteogenesis without any significant morbidity.<sup>4</sup>

Autologous bone marrow injection is a relatively simple technique that can be performed in a minor OT with local anesthetic agents and hence it is very cost effective. It also avoids a number of serious donor or recipient site problems that may arise from the traditional bone grafting technique.<sup>4</sup> The bone marrow injection is safe, as the material injected is autogenous, so there is no risk of disease transmission or immune reaction.<sup>3</sup> The most significant role of autologous bone marrow injection is that it provides the early treatment of fractures whenever there is a query of future non-union at the fracture site, hence it can be used as a preventive method for future non-union in vulnerable cases.<sup>4</sup>

The limitations of our study are the lack of comparison group with other methods of delayed union treatment,

sample size was comparatively small and the duration of the study was less.

## 5. Conclusion

Treatment of delayed union of long bone fractures after definitive fixation is a challenging task for the orthopaedic surgeons. There are various treatment modalities to manage delayed union, such as traditional bone grafting, induce membrane technique, ultrasound treatment, electric shock wave therapy, demineralised bone matrix (DBM), recombinant bone matrix protein (rhBMP), platelet-rich plasma, external compression by external fixators, dynamization etc. But all these techniques are relatively expensive and require an experienced and skilful hand. On the other hand, the percutaneous autologous bone marrow injection is a simple and effective technique to deal with the delayed union as it is a day care procedure, provides cellular stimulation at the fracture site, promotes fracture healing, very cost effective and can be performed under local anaesthesia without exploring the fracture site and thereby potentially avoiding the major surgical risk and most importantly it can prevent the fracture from future non-union. However to come into a definitive conclusion a long term multicentric study with a comparison group with the other methods are necessary.

## 6. Consent

Written informed consent were taken from all the patients under this study for this publication carrying all the clinical data and images.

## 7. Source of Funding

None.

## 8. Conflict of Interest

There is no conflict of interest.

## References

- Antonio J, Guimarães M, Eugenia M, Duarte L, Cury MB, Isabel CC, et al. The effect of autologous concentrated bone-marrow grafting on the healing of femoral shaft non-unions after locked intramedullary nailing. *Injury*. 2014;45(Suppl 5):S7–S13.
- Braly HL, Connor DPO, Brinker MR. Percutaneous Autologous Bone Marrow Injection in the Treatment of Distal Meta-diaphyseal Tibial Nonunions and Delayed Unions. *J Orthop Trauma*. 2013;27(9):527–33.
- Sahu RL. Percutaneous autogenous bone marrow injection for delayed union or non-union of long bone fractures after internal fixation. *Rev Bras Ortop*. 2017;53(6):668–73.
- Connolly FJ, Roy G, Tiedeman J, Dehne R. Autologous Marrow Injection for Delayed Unions of the Tibia: A Preliminary Report. *J Orthop Trauma*. 1989;3(4):276–82.
- Thomas ED, Storb R. Technique for human marrow grafting. *Blood*. 1970;36(4):507–15.
- Gross J, Diligent J, Bensoussan D, Galois L. Percutaneous autologous bone marrow injection for treatment of delayed and non-union of long bone: a retrospective study of 45 cases. *Biomed Mater Eng*. 2015;25(1 Suppl):187–97.
- Heckman JD, Ryaby JP, McCabe J, Frey JJ, Kilcoyne RF. Acceleration of tibial fracture-healing by non-invasive, low-intensity pulsed ultrasound. *J Bone Joint Surg Am*. 1994;76(1):26–34.
- Kim PH, Leopold SS. Gustilo-Anderson classification. *Clin Orthop Relat Res*. 2012;470(11):3270–4.
- Khan SN, Cammisa FP, Sandhu HS, Diwan AD, Girardi FP, Lane JM. The biology of bone grafting. *J Am Acad Orthop Surg*. 2005;13(1):77–86.
- Friedlaender GE, Perry CR, Cole JD, Cook SD, Cierny G, Muschler GF, et al. Osteogenic protein-1 (bone morphogenetic protein-7) in the treatment of tibial nonunions: A prospective, randomized clinical trial comparing rhOP-1 with fresh bone autograft. *J Bone Joint Surg Am*. 2001;83A(Suppl 1):S151–8.
- Dimitriou R, Dahabreh Z, Katsoulis E, Matthews SJ, Branfoot T, Giannoudis PV. Application of recombinant BMP-7 on persistent upper and lower limb non-unions. *Injury*. 2005;36(Suppl. 4):S51–9.
- Gandhi A, Dumas C, O'Connor JP, Parsons JP, Lin SS. The effects of local platelet rich plasma delivery on diabetic fracture healing. *Bone*. 2006;38(4):540–6.
- Gerard D, Carlson ER, Gotcher JE, Jacobs M. Effects of platelet-rich plasma on the healing of autologous bone grafted mandibular defects in dogs. *J Oral Maxillofac Surg*. 2006;64(3):443–51.
- Roussignol X, Currey C, Duparc F, Dujardin F. Indications and results for the Exogen™ ultrasound system in the management of non-union: A 59-case pilot study. *Orthop Traumatol Surg Res*. 2012;98(2):206–13.
- Galois L, Bensoussan D, Diligent J, Pinzano A, Henrionnet C, Choufani E, et al. Autologous bone marrow graft and treatment of delayed and non-unions of long bones: technical aspects. *Biomed Mater Eng*. 2009;19(4-5):277–81.
- Ebraheim NA, Elgafy H, Xu R. Bone-graft harvesting from iliac and fibular donor sites: techniques and complications. *J Am Acad Orthop Surg*. 2001;9(3):210–8.
- Singh AK, Shetty S, Saraswathy JJ, Sinha A. Percutaneous autologous bone marrow injections for delayed or non-union of bones. *J Orthop Surg (Hong Kong)*. 2013;21(1):60–4.
- DiBella C, Dozza B, Frisoni T, Cevolani L, Donati D. Injection of demineralized bone matrix with bone marrow concentrate improves healing in unicameral bone cyst. *Clin Orthop Relat Res*. 2010;468(11):3047–55.
- Bajada S, Harrison PE, Ashton BA, Cassar-Pullicino VN, Ashammakhi N, Richardson JB. Successful treatment of refractory tibial nonunion using calcium sulphate and bone marrow stromal cell implantation. *J Bone Jt Surg - Ser B*. 2007;89(10):1382–6.
- Park IH, Micic ID, Jeon IH. A study of 23 unicameral bone cysts of the calcaneus: Open chip allogeneic bone graft versus percutaneous injection of bone powder with autogenous bone marrow. *Foot Ankle Int*. 2008;29(2):164–70.

## Author biography

**Zaheer Parveez Islam**, Assistant Professor

**Ujjal Kar**, Post Graduate Trainee  <https://orcid.org/0000-0003-3403-0817>

**Abhinab Gogoi**, Senior Resident

**Cite this article:** Islam ZP, Kar U, Gogoi A. Percutaneous autologous bone marrow injection in the treatment of delayed union of long bone fractures after definitive fixation. *Indian J Orthop Surg* 2022;8(1):10-16.