

Content available at: <https://www.ipinnovative.com/open-access-journals>

Indian Journal of Orthopaedics Surgery

Journal homepage: <https://www.ijos.co.in/>

## Original Research Article

## Muscle pedicle bone graft in ununited fracture neck of femur in children

Govind Mohan Jee<sup>1,\*</sup>, Nitin Kumar<sup>1</sup><sup>1</sup>Dept. of Orthopaedics, Jawahar Lal Nehru Medical College, Bhagalpur, Bihar, India

## ARTICLE INFO

## Article history:

Received 03-11-2021

Accepted 29-12-2021

Available online 24-03-2022

## Keywords:

Children

Fracture neck of femur

Muscle pedicle

## ABSTRACT

**Background:** Delayed presentation of fracture neck of femur is not uncommon in our scenario and is difficult to treat because of precarious vascularity and bony defect at fracture site.

**Aims:** The purpose of the present study is the analysis of functional outcome of the muscle pedicle bone graft procedure in ununited fracture neck of femur in children and adolescents.

**Materials and Methods:** Sixteen patients with ununited fracture neck of femur (presenting late) in children and adolescents were treated with quadratus femoris based muscle pedicle bone graft along with open reduction and internal fixation. Mean age of the patient was 14.25 year (range 12-16 years). Boys dominated our series (n= 10 i.e.62.50%). Road traffic accident was the leading cause. Average injury –surgery interval was 5.88 week (range 3-9 week). A minimum follow up was two years. There were 2 Transepiphyseal, 11 Transcervical and 3 Cervicotrochanteric fractures.

**Result:** Most of the cases showed union in 16 to 24 weeks. In one case there was implant failure.

**Analysis:** The result was analysed using Harris Hip Score. We had 11 (68.75%) excellent, 2 (12.50%) Good, 2(12.50%) Fair and one (06.25%) Poor results in our series.

**Conclusion:** Quadratus femoris based Muscle pedicle bone with internal fixation is a very effective method to address the difficult problem of non-union fracture neck of femur. There was statistically significant association (p value <.005) between accuracy of reduction and functional outcome.

This is an Open Access (OA) journal, and articles are distributed under the terms of the [Creative Commons Attribution-NonCommercial-ShareAlike 4.0 License](https://creativecommons.org/licenses/by-nc-sa/4.0/), which allows others to remix, tweak, and build upon the work non-commercially, as long as appropriate credit is given and the new creations are licensed under the identical terms.

For reprints contact: [reprint@ipinnovative.com](mailto:reprint@ipinnovative.com)

## 1. Introduction

AK Gupta et al. in a clinical study of 32 patients 14 to 62 years reported union in 89.5%. The results were excellent in 15 cases, good in 4 cases and poor in 6 cases. Ununited fracture neck of femur in children and adolescent is a common problem in developing countries where treatment is often delayed. It is a challenging entity to address. The problem associated with delayed presentation are structural bone gap at the fracture site, poor osteogenic potential at fracture margins, hypovascularity of proximal fragment and interposed avascular scar tissue in between the fragment. Osteogenesis or osteosynthesis is the only option in this

age group. Different treatment modalities available are open reduction and internal fixation with fibular grafting, valgus osteotomy with and without internal fixation and muscle pedicle bone graft with internal fixation. Although open reduction and internal fixation with or without bone grafting and valgus osteotomy do give acceptable result, the muscle pedicle bone graft has definitely an edge over them as it simultaneously addresses all the problems associated with ununited fracture neck of femur without disturbing proximal femoral anatomy.<sup>1</sup> It bridges the structural bone gap, stimulates osteogenesis and improves vascularity of femoral head.<sup>2</sup> The aim of anatomical reduction, stable fixation and augmented osteogenesis at fracture site is completely achieved by quadratus femoris muscle pedicle bone grafting with internal fixation resulting in accelerated

\* Corresponding author.

E-mail address: [mdrgovind@gmail.com](mailto:mdrgovind@gmail.com) (G. M. Jee).

union and better functional outcome.

## 2. Aims of the Study

Present study was undertaken to analyse the result of muscle pedicle bone graft in ununited fracture neck of femur in children and adolescents.

## 3. Material and Methods

Sixteen patients of ununited fracture neck of femur (presenting late i.e. more than 3 weeks) in the children and adolescent were treated with quadratus femoris based muscle pedicle bone graft with internal fixation between 2004 to 2019. Pathological fracture, recent fracture and compound fracture were excluded from study. Mean age was 14.25 years (standard deviation 1.27 and range 12 to 16 years). Boys dominated our series (n=10 i.e. 62.50%) and right side was more commonly involved (n=12 i.e.75%). All of them were investigated for their fitness for spinal block or general anaesthesia. Steps of procedure including patient positioning, surgical procedure, provisional fixation and definitive fixation were discussed and documented. Radiographic evaluation included A-P View in 15 degree internal rotation, and Lateral view. Average delay in presentation was 5.88 weeks (range was 3-10 weeks). We had 02 transepiphyseal, 11 transcervical and 3 cervicotrochanteric fracture in our series. All the fractures were displaced and having some absorption of femoral neck.

## 4. Surgical Procedure

Spinal block was used in the procedure. Prone position on fracture table with radiolucent top was used. Fracture site was exposed through posterior approach and sclerosed margins of the fragments were freshened. Fracture was reduced with appropriate neck shaft angle and fixed with Moors pin/ knowels pin or 4 mm /7mm partially threaded cancellous screws. Any rotation or tilt was corrected. The fixation was augmented with quadratus femoris muscle pedicle bone graft harvested from intertrochanteric crest area with a bone pedicle of length 2 cm, width 1 cm and depth 1 cm. The graft was secured to the proximal femoral head fragment with 3.5mm cortical screw or 4mm cannulated cancellous screw. Soft tissue closure was done over drain.

### 4.1. Postoperative Care

First dressing change was done on third postoperative day and drain was removed at the same time. Sutures were removed on 14<sup>th</sup> day. Usually on 5<sup>th</sup> postoperative day quadriceps exercises was started. Non weight bearing was ensured for 4 months or till radiological union.

### 4.2. Followup

Patients were followed up at 2 weeks, 4 weeks, 6 weeks, 8 weeks, regularly at 6 week interval for next 6 month and then at three month interval up to two year. Radiographic analysis was performed at each follow up with special attention to extent of callus formation, alignment of fragments and hard ware integrity.

**Table 1:** Shows age distribution of the patient

Age of patient (year)	No. of patient (%)
12 -13 years	03 (18.75)
13.1-14 years	04 (25.00)
14.1-15 years	02 (12.50)
15.1-16 years	07(43.75)

**Table 2:** Shows radiological classification

Radiological type	No. of patient (%)
Transepiphyseal	02(12.5)
Transcervical	11(68.75)
Cervicotrochanteric	03(18.75)

**Table 3:** Shows delay in presentation

Delay (weeks)	No. of patient (%)
3	02(12.50)
4	02(12.50)
5	04(25.00)
6	04(25.00)
7	02(12.50)
8	01(06.25)
9	01(06.25)

**Table 4:** Shows time of radiological union

Time in weeks	No. of patients (%)
16– 20	04(25.00)
21- 24	06 (37.50)
25 -28	04 (25.00)
29-32	01 (06.25)
Non-union	01 (06.25)

**Table 5:** Shows complications encountered in our series

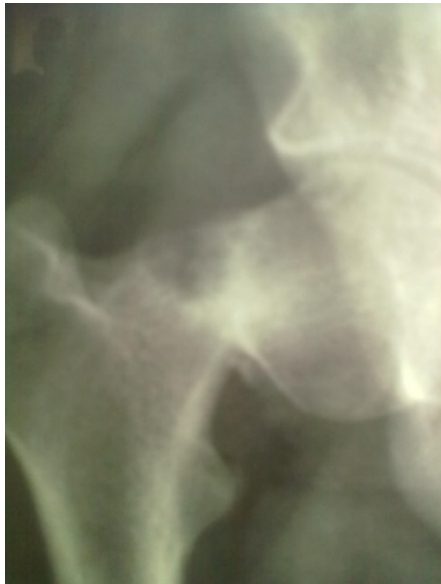
Complications encountered	No. of patients (%)
Infection	00 (00.00)
Coxa vara	02 (12.50)
Nonunion	01 (06.25)
Premature closure of physis	00 (00.00)
Osteonecrosis	02 (12.50)
Chondrolysis	00 (00.00)
Shortening	02 (12.50)

**5. Observation**

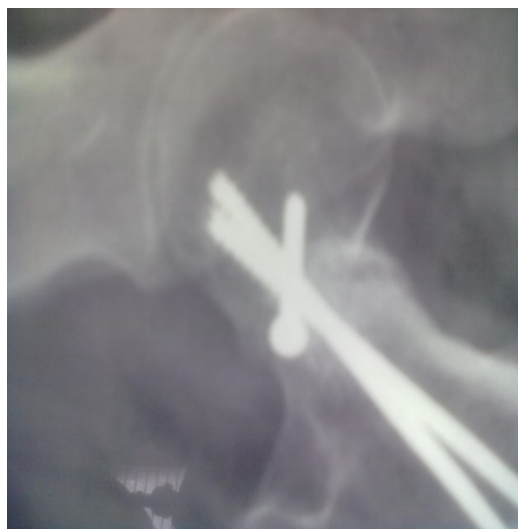The result was analysed using Harris hip score and graded as excellent, good, fair and poor.

**Table 6:**

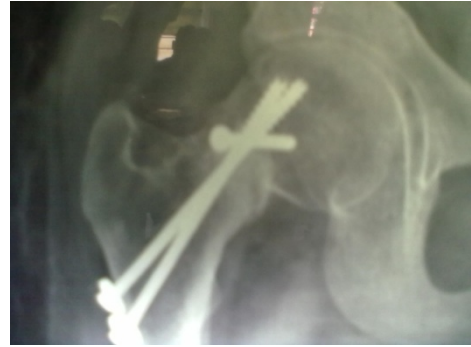Result	Harris hip Score	No. of patients (%)
Excellent	90-100	11(68.75)
Good	80-89	02 (12.50)
Fair	70-79	02 (12.50)
poor	< 70	01(06.25)



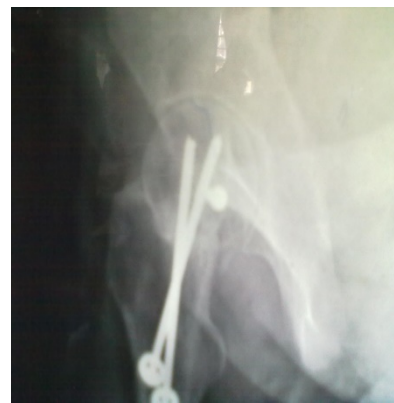**Fig. 1:** Case 1: Preoperative x-ray



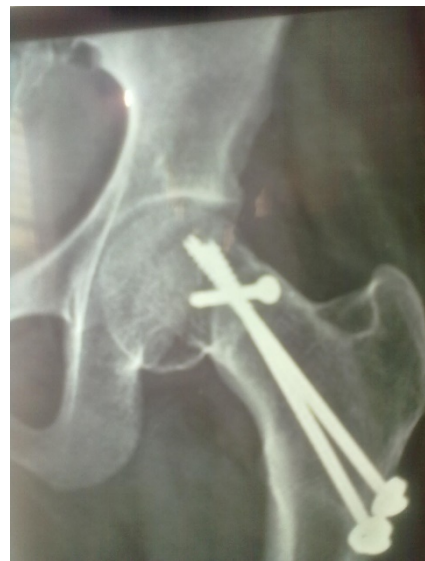**Fig. 2:** Case 1: Postoperative at 6 weeks



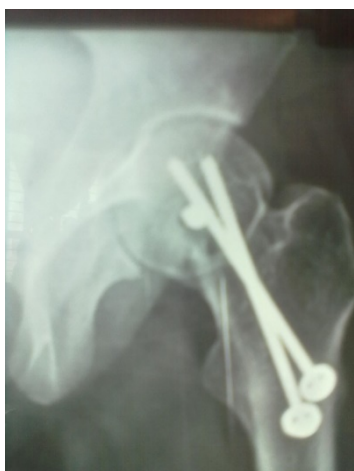**Fig. 3:** Case 1: Postoperative x-ray at 10 week AP view



**Fig. 4:** Case 1: Postoperative x-ray at 10 week lateral view



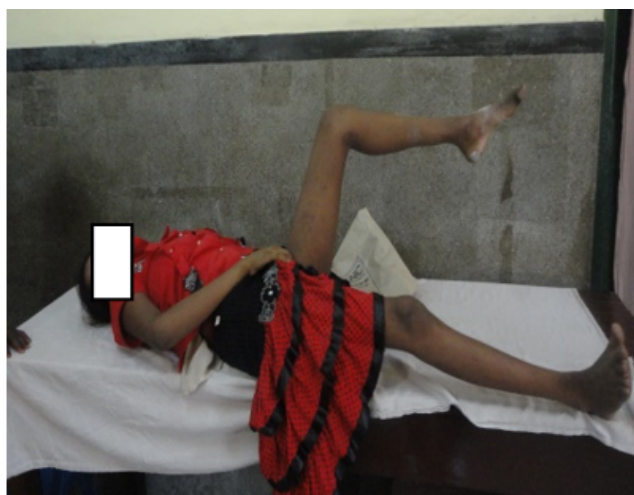**Fig. 5:** Case 1: Postoperative at 16 weeks



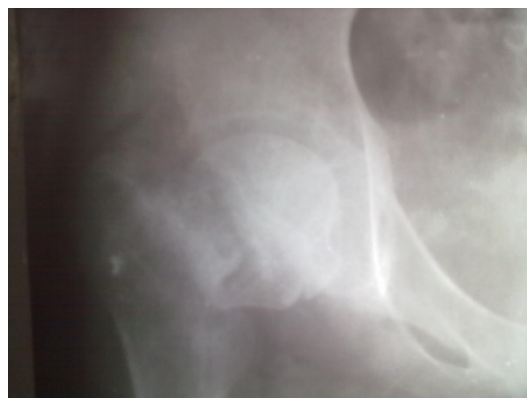**Fig. 6:** Case 1: Postoperative at 20 weeks



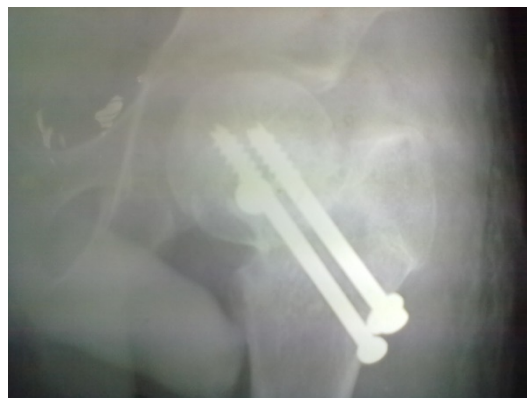**Fig. 8:** Case 1: Clinical photograph at 20 weeks postoperative



**Fig. 7:** Case 1 : Clinical photograph postoperative at 20 weeks



**Fig. 9:** Case 2: Preoperative x-ray



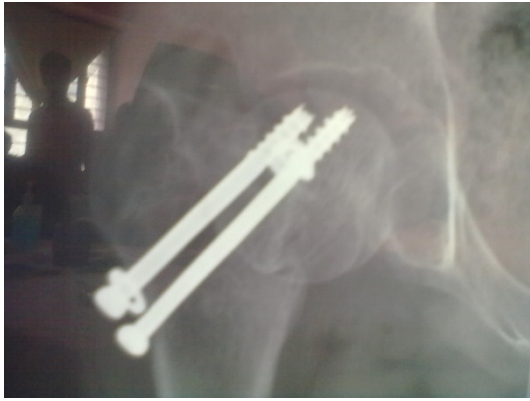**Fig. 10:** Case 2: Postoperative at 10 weeks

## 6. Discussion

Delayed presentation of fracture neck of Femur in paediatric age group is not uncommon in developing countries. Meyers Muscle pedicle bone graft has been a well recommended procedure for fracture neck non-union in adult with union rate of 95%.<sup>3</sup> Subtrochanteric valgus osteotomy in paediatric age groups give variable result.<sup>4</sup>

Delima DF et al., in a clinical study of 16 patients with ununited transcervical femoral fractures, age 12 to 40 years treated with open reduction and internal fixation with Meyers muscle pedicle graft reported radiological union in 13 patients.<sup>5</sup>

AK Gupta et al in a clinical study of 32 patients aged 14 to 62 years reported union in 89.5%. The results were excellent in 15 cases, good in 4 cases and poor in 6 cases. Complications like Avascular necrosis (n=2), transient foot drop (n=2), coxa vara (n=1) were noted in the study.<sup>2</sup>



**Fig. 11:** case 2: Postoperative x-ray at 16 weeks



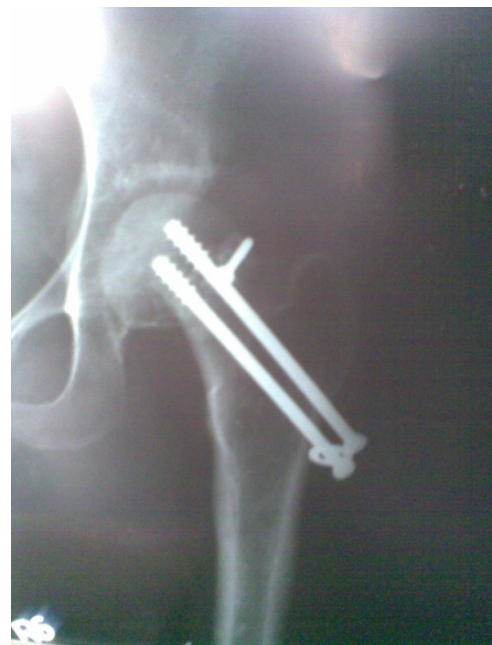**Fig. 14:** Case 2 : Clinical photograph



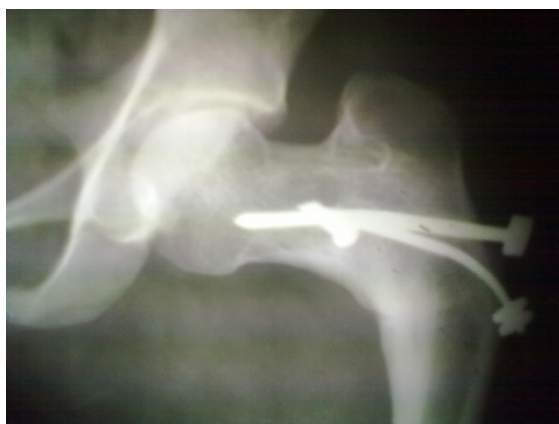**Fig. 12:** Case 2: Clinical photograph



**Fig. 13:** Case 2: Clinical photograph



**Fig. 15:** Case 3: Postoperative X-ray



**Fig. 16:** Case 4: Coxa vara with bending of implant

Harun Yasin Tuzun et al. in his series of 16 patients has reported radiological union at average of 7 months and only one patient (6%) had avascular necrosis.<sup>6</sup>

In our series of sixteen cases we had 68.75% (n=11) excellent, 12.50% (n=2) good, 12.50 (n=2) fair and 06.25% (n=1) poor result.

## 7. Conclusion

Muscle pedicle bone graft with internal fixation has proved to be an efficient method of treatment of ununited fracture neck of femur in children and adolescent as it improves the vascularity of femoral head, bridges the structural gap at fracture site and enhances osteosynthesis at fracture site simultaneously without altering the anatomy of proximal femur.

## 8. Source of Funding

None.


## 9. Conflict of Interest

The author declares no conflict of interest.

## References

1. Gupta AK, Rastogi S, Nath R. Internal fixation and muscle pedicle bone grafting in femoral neck fractures. *Indian J Orthop.* 2008;42(1):39–42.
2. Baksi DP. Internal fixation of ununited femoral neck fractures combined with muscle-pedicle bone grafting. *J Bone Joint Surg Br.* 1986;68(2):239–45.
3. Meyers MH, Harvey JP, Moore TM. The muscle pedicle bone graft in the treatment of displaced fractures of femoral neck: indications, operative technique and results. *Orthop Clin North Am.* 1974;5(4):779–92.
4. Ratliff AHC. Fractures of the neck of the femur in children. *J Bone Joint Surg (Br).* 1962;44-B(3):528–42.
5. Delima DF, Tanna DD. The quadratus femoris graft in old transcervical femoral fractures. *J Postgrad Med.* 1989;35(3):152–56.
6. Tuzun HY, Türkkan S, Erşen Ö, Arsenishvili A, Kürklü M. results of quadratus femoris muscle pedicle grafting (Meyers procedure in the management of ununited femoral neck fractures. *Hip Int.* 2021;31(4):562–7.

## Author biography

**Govind Mohan Jee**, Associate Professor  <https://orcid.org/0000-0002-2581-0865>

**Nitin Kumar**, Senior Resident

**Cite this article:** Jee GM, Kumar N. Muscle pedicle bone graft in ununited fracture neck of femur in children. *Indian J Orthop Surg* 2022;8(1):17-22.