

## Anterior cruciate ligament Ganglion cyst: A diagnostic dilemma

Ravindra Chauhan<sup>1</sup>, Naveen BM<sup>2,\*</sup>, HS Agarwal<sup>3</sup>

<sup>1</sup>Classified Specialist, Dept of Orthopaedics, Base Hospital, Delhi cantt. New delhi

<sup>2</sup>Clinical Tutor, Dept of Orthopaedics, AFMC, Pune-411040

<sup>3</sup>Commandant, Military Hospital Kirkee

**\*Corresponding Author:**

E-mail: drnaveenbm@yahoo.co.in

**Key words:** Ganglion, ACL, Arthroscopic resection, Internal derangement of knee

Access this article online	
Quick Response Code:	Website: www.innovativepublication.com
	DOI: 10.5958/2395-1362.2016.00018.9

### Introduction

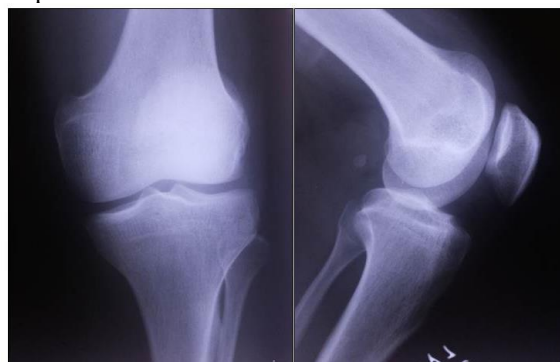
Ganglion cyst is a tumour like cystic lesion arising from tendon sheath or a joint capsule which contains a gelatinous material consisting of hyaluronic acid and various other mucopolysaccharides. These can be solitary or multilocular. Dorsum of the hand is the most common location[1]. However, ganglion cysts around the knee are not infrequent. They usually are extra articular[2]. Intra articular ganglion cyst arising from cruciates is very rare. These are usually asymptomatic with diagnosis made incidentally on MRI or arthroscopy[3]. The symptoms may include pain, stiffness and mechanical locking. Some may have history of trauma but these lesions mimic internal derangement of knee. Here, we report a case of ganglion cyst of anterior cruciate ligament.

### Case summary

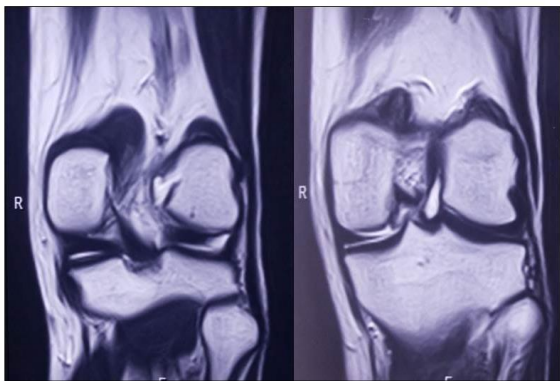
A 26 year old serving soldier presented with insidious onset of pain and stiffness in left knee of 03 months duration. Pain aggravated on extremes of flexion, however there were no symptoms of locking or giving away of the knee. There was no history of trauma. Examination of knee was normal with no swelling, effusion or point tenderness. Quadriceps wasting was minimal. Knee movements were normal except for pain full terminal restriction in flexion (final 20 degrees). The cruciate and collateral ligaments were clinically intact. McMurray's test for both menisci was negative. Patellar tracking was normal with no tenderness or crepitus on patellofemoral motion. Presumptive diagnosis of internal derangement of knee was made, possibly a chondral lesion or a meniscal tear. Plain radiographs of the knee were reported as normal. MRI showed a moderate sized (measuring 33x12x 6mm) well defined intrarticular cystic lesion along the

posterior surface of anterior cruciate ligament which was hyper intense on T2 and hypo intense on T1 images. There was no meniscal or chondral pathology reported.

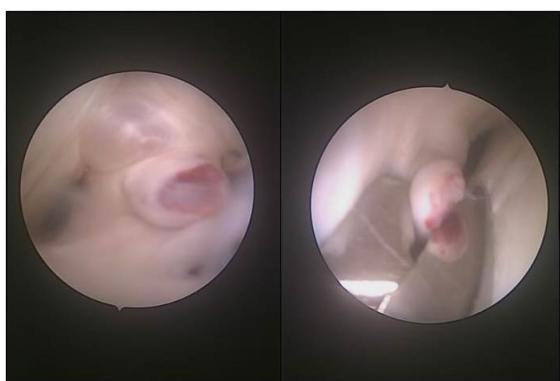A standard two-portal arthroscopy revealed normal articular surfaces, normal posterior cruciate ligament and normal menisci. A cyst was visualized within the substance of ACL on posterolateral aspect close to its femoral attachment. It was ovoid in shape measuring about 20 mm in diameter. The cyst was well demarcated and its origin from the ACL was clearly seen. It was thin-walled and translucent. There were no adhesions or signs of inflammation surrounding the swelling. Puncturing the cyst resulted in extrusion of clear gelatinous material. The area around the ACL was probed, and all the septa were broken. The cyst with its entire wall was excised using suction assisted power shaving. The integrity and the tension in the ACL checked after the removal of cyst and found to be satisfactory. All other structures within the knee joint were normal. Gross examination of cyst wall revealed multiple greyish-white membranous pieces largest measuring 1.1x0.4x0.3 cm. Microscopy showed a cyst lined by fibrofatty tissue with areas of fibrinoid change and leukocyte infiltration. However, no epithelial lining was seen which confirmed the diagnosis of ganglion cyst. The postoperative course was uneventful with resolution of pain and stiffness. Six months postoperatively, the patient was asymptomatic and clinical examination was normal, hence no MRI scan was performed.



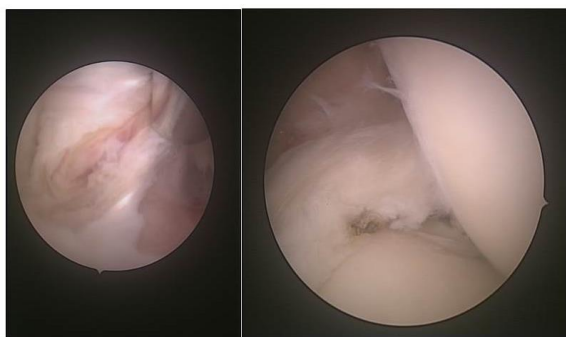
**Fig. 1: Pre-Operative Radiograph showing the normal knee joint**



**Fig. 2: Pre-Operative MRI scan showing the ACL Ganglion Cyst**



**Fig. 3: Intra Operative arthroscopic photograph showing the ACL Ganglion Cyst**



**Fig. 4: Post-operative arthroscopic photograph after complete resection of cyst**

## Discussion

Caan in 1924 reported the presence of a ganglion cyst in the knee joint following an autopsy of an elderly male [4], following which only occasional cases have been reported. In recent years with the frequent use of imaging modalities especially MRI and minimally invasive procedures like arthroscopy, such cases are have shown an increased incidence. Ganglion cyst is a cystic swelling which usually has its origin close to joints and tendons. The most common site of such a cyst is the dorsum of the hand. However it has also been reported in other musculoskeletal regions. Review of literature shows prevalence of intra articular

ganglion cysts to be only 1.3% on MRI and 0.6% on arthroscopy. About 20% are seen in relation to the anterior cruciate ligament, making it a very rare lesion[5]. The most common site for intra articular ganglion cysts in knee joint is ACL, followed by PCL and medial meniscus. The cruciate ligament ganglion cysts can increase in size to lie between the two cruciates or may intersperse within the fibers. Cysts arising from the ACL usually have their origin from the tibial insertion. However in our case, the cyst was seen to arise from the substance of the ACL close to the femoral attachment.

Aetiopathogenesis of Ganglion cysts have been explained by two postulated theories. The first regards the cyst to be a result of mucinous degeneration of connective tissue[6] while the other postulates it as a result of herniation of synovial tissue through a defect in the joint capsule or tendon sheath[7]. Interestingly, the relationship to previous trauma is uncertain. Krudwig et al[3] reported 85 cases of intra-articular ganglion cysts, with 9 being symptomatic and 76 asymptomatic. The symptomatic patients had no history of trauma as in our case. Despite the absence of a history of trauma, it is postulated that repetitive microtrauma during joint and soft tissue motion liberates mucin and hyaluronic acid from ligament fibres which can act as a trigger[5]. Histopathologically ganglion cysts are not true cysts as they lack an epithelial lining. This evidence refutes the theory of synovial herniation while favoring a degenerative cause[8]. Clinically, ganglion cyst present as internal derangement of the knee.

MRI is the considered the investigation of choice. The preferred treatment is arthroscopic excision of the cyst[9]. However it has been documented that some of ganglion cysts may disappear spontaneously with conservative management[10]. There have been anecdotal reports of successful treatment following CT-guided aspiration, hinting that any damage to the cyst wall may cause its resolution. However it is pertinent to mention that a recurrence is very rare following complete resection but can occur following aspiration.

## Conclusion

Though rare, intra-articular ganglion cysts should be considered in cases of internal derangement of the knee with symptoms of pain, stiffness and locking, particularly in the absence of overt trauma. Because of their rare occurrence, diagnosis of such cases may be difficult clinically. MRI can be helpful in the diagnosis and arthroscopic resection is the treatment of choice.

**Conflict of Interest: None**

**Source of Support: Nil**

## References

1. L. E. Thornburg, "Ganglions of the hand and wrist," *The Journal of the American Academy of Orthopaedic Surgeons*, vol. 7, no. 4, pp. 231–238, 1999.
2. F. D. Beaman and J. J. Peterson, "MR imaging of cysts, ganglia, and bursae about the knee," *Radiologic Clinics of North America*, vol. 45, no. 6, pp. 969–982, 2007.
3. W. K. Krudwig, K. K. Schulte, and C. Heinemann, "Intraarticular ganglion cysts of the knee joint: a report of 85 cases and review of the literature," *Knee Surgery, Sports Traumatology, Arthroscopy*, vol. 12, no. 2, pp. 123–129, 2004.
4. Caan P. Cyst formation (ganglion) in an anterior cruciate ligament of the knee. *Deutsch Z Chir* 1924; 186:403–408
5. L. T. Bui-Mansfield and R. A. Youngberg, "Intraarticular ganglia of the knee: prevalence, presentation, etiology, and management," *American Journal of Roentgenology*, vol. 168, no. 1, pp. 123–127, 1997.
6. Fealy S, Kenter K, Dines JS, Warren RF. Mucoid degeneration of the anterior cruciate ligament. *Arthroscopy* 2001;17:37–39.
7. Kaatee R, Kjartansson O, Brekkan A. Intraarticular ganglion between the cruciate ligaments of the knee. *Acta Radiol* 1994;35:434–436.
8. D. Bergin, W. B. Morrison, J. A. Carrino, S. N. Nallamshetty, and A. R. Bartolozzi, "Anterior cruciate ligament ganglia and mucoid degeneration: coexistence and clinical correlation," *American Journal of Roentgenology*, vol. 182, no. 5, pp. 1283–1287, 2004.
9. M. F. Brown and D. J. Dandy, "Intra-articular ganglia in the knee," *Arthroscopy*, vol. 6, no. 4, pp. 322–323, 1990.
10. G. S. Huang, C. H. Lee, W. P. Chan et al., "Ganglion cysts of the cruciate ligaments: MR findings with clinical correlation," *Acta Radiologica*, vol. 43, no. 4, pp. 419–424, 2002.