



Original Research Article

To evaluate the outcome of fracture supracondylar humerus managed with percutaneous lateral pinning in children

Pravin Kumar Jangde¹, Sanjay Kumar Ghilley^{2,*}¹Dept. of Orthopaedics, LAM Government Medical College, Raigarh, Chhattisgarh, India²Dept. of Orthopaedics, Chhattisgarh Institute of Medical Sciences, Bilaspur, Chhattisgarh, India

ARTICLE INFO

Article history:

Received 26-03-2022

Accepted 24-05-2022

Available online 20-09-2022

Keywords:

Supracondylar humerus fracture

CRIF with k wire

Lateral pinning. Flynn's criteria

ABSTRACT

Background: CRIF with K-wire fixation is the treatment of choice in fractures supracondylar humerus in children. The study was done in thirty patient to evaluate the outcome of percutaneous lateral pinning using k wire.

Materials and Methods: Thirty case of displaced fracture supracondylar in children managed with CRIF with percutaneous lateral pinning using k- wire. The average age group of children was 7.4 year (minimum 5year of age and maximum-13year year). The fracture was immobilised for three weeks. Follow up was done at 3, 6, 9,12,24 week and all the complication were recorded. Evaluation was done on the basis of Flynn's criteria by measuring loss of elbow motion and carrying angle.

Results: Out of 30 patient 26 patients had excellent results, 2 patient had good results, 1 patient had fair result and 1 patient had poor result according to Flynn's criteria.

Conclusion: CRIF with k -wire by percutaneous lateral pinning in displaced fracture supracondylar humerus in children is an excellent modality of treatment with good functional outcome and minimum complication.

This is an Open Access (OA) journal, and articles are distributed under the terms of the [Creative Commons Attribution-NonCommercial-ShareAlike 4.0 License](https://creativecommons.org/licenses/by-nc-sa/4.0/), which allows others to remix, tweak, and build upon the work non-commercially, as long as appropriate credit is given and the new creations are licensed under the identical terms.

For reprints contact: reprint@ipinnovative.com

1. Introduction

Supracondylar fractures of the humerus comprise 17% of all childhood fractures and also are the commonest elbow injuries in children.¹ These fractures are often complicated by neural and vascular injuries and malunion leading to cubitus varus deformity.² The classification of these fractures by Gartland was modified by Wilkins to allow for the rotational deformity: type I (undisplaced), type IIA (angulated, posterior cortex intact, no rotation), type IIB(angulated, posterior cortex intact, rotational deformity), and type III (displaced with no cortical contact).³

There are various treatment option available for fracture supracondylar humers like close reduction and pop casting,

skeletal traction, CRIF with k-wire, ORIF.⁴⁻⁶

Conservative management with pop casting leads to various comlication like loss of reduction, malunion, cubitus varus deformity. ORIF with k wire gives anatomical reduction but it has some disadvantages like more blood loss, chances of infection, elbow stiffness, longer hospital stay.

The main aim is to evaluate the functional outcome and advantage of fracture supracondylar humerus treated by CRIF with k wire through percutaneous lateral pinning.

2. Materials and Methods

This is a prospective study conducted in at LAM Government Medical College, Raigarh, (C.G.) from February 2021 to February 2022 in 30 cases of closed

* Corresponding author.

E-mail address: sanjay.lifegud@gmail.com (S. K. Ghilley).

displaced fracture supracondylar humerus without vascular compromise (Gartland type II and III) in children upto age 14 years. 21 male and 9 female were included in the study. CRIF with k-wire through percutaneous lateral pinning was done in all cases.

2.1. Exclusion criteria

Open fracture, old malunited fracture, pathological fracture, patient not willing for surgery.

2.2. Technique of CRIF with k-wire through percutaneous lateral pinning

Under general anaesthesia the patient is placed supine with an arm table. Ensure adequate AP and lateral images can be obtained without the arm being moved.

Closed reduction done by traction, medial/lateral correction, reduction of extension reduction is confirmed by image intensifier by taking AP and lateral view. After adequate reduction achieved percutaneous lateral pinning with k wire (1.5/2mm) is performed under image intensifier by keeping the elbow in flexion and forearm in pronation to prevent displacement.(Figure 1)

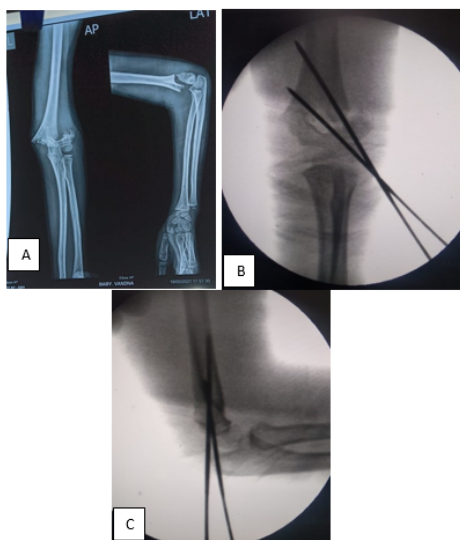


Fig. 1: a: Preoperative x-ray; b: Post op x-ray (ap view); c: Post op x-ray (lateral view)

Post procedure an above-elbow back slab is applied with the arm in 80–90° of flexion ensuring that good circulation in the fingers is maintained.

After proper evaluation. The patients were discharged on day one postoperative and advised to follow up after one week for clinical and radiological check-up or any other complication. K-wires and slab removal done on 3rd week. After clinical and radiological evaluation physiotherapy started. Patients were followed up on 6, 9, 12, 24 week.

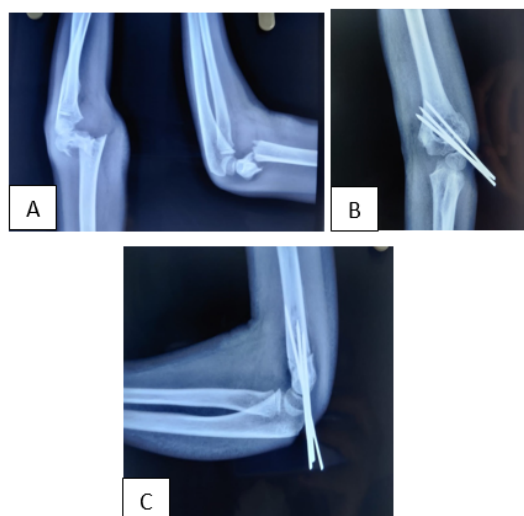


Fig. 2: a: Preoperative x-ray; b: Post op x-ray (ap view); c: Post op x-ray (lateral view)

Evaluation was done on the basis of Flynn's criteria by measuring loss of elbow motion and carrying angle.

3. Results

In our study out of thirty, there were 21 male child and 9 female child. The mean age was 7.4 year. The minimum age was 5 year and maximum was 13 year.

The major cause of injury was fall from height (60%), fall on ground while playing (30%), road traffic accident (20%). Out of 30 cases 20 cases were of right side. Out of 30 cases 18(60%) cases were of Gartland type III and 12 (40%) cases were of Gartland type II.

In our study according to Flynn's criteria⁷ (Table 1) out of 30 cases, 26 patient (87%) had excellent result having the range of motion loss and carrying angle loss was less than 5 degrees, 2 patient (7%) had good result, 1 patient (3%) had fair and 1(3%) patient had poor result because of Loss of range of motion was more than 15 degrees or carrying angle loss was more than 15 degrees. Only one patient had complication of pin tract infection.

4. Discussion

Supracondylar fracture have been conventionally considered as orthopaedic emergency because of its dreaded complication like vascular injury, compartment syndrome, Volkmann's ischemia. Supracondylar fracture should be reduced accurately. There are different modality for management of displaced fracture supracondylar humerus in children like closed reduction with pop casting, traction, CRIF with percutaneous pinning by k-wire, ORIF with k- wire fixation. Each modality have its own advantages and disadvantage like closed reduction with

Table 1: Flynn's criteria for assessment of reduction

Result	Cosmetic factor: Carrying angle(^o)	Functional factor: motion loss (^o)	Number of patient	Percentage %
Excellent	0-5	0-5	26	87
Good	>5-10	>5-10	2	7
Fair	>10-15	>10-15	1	3
Poor	>15	>15	1	3

Table 2: Comparing results with other series

Series	Satisfactory		Unsatisfactory	
	Excellent	Good	Fair	Poor
Bhan S et al. ⁸	72%	3.20%	21.30%	4.50%
Laud N S et al. ⁹	0%	94%	2%	4%
Pirone A et al. ¹⁰	67%	11%	0%	22%
Our study	87%	7%	3%	3%

pop casting leads to loss of reduction, malunion, cubitus varus deformity. Cross pinning prone for nerve injury, ORIF may leads to infection, blood loss, elbow stiffness. Supracondylar fracture should be reduced accurately and stabilized.

In this study after accurate reduction fracture fixation done by k-wire through percutaneous lateral pinning.

In our study, pintract infection was seen in one cases i.e. 3% of the patients. The observation was similar to all the other studies done like Fowels J et al.¹¹ were pin tract infection was 7.7%. Where as in Hamid RM,¹² Charles S¹³ study were pin tract infection was 7.2%.

We had satisfactory (excellent and good) results in 28 cases (90%) of which is comparable with other studies. Two patients (6%) had unsatisfactory result.(Table 2)

5. Conclusion

CRIF with K-wire fixation through percutaneous lateral pinning is a safe procedure that give stable fixation without any neurovascular complication.

6. Source of Funding

None.

7. Conflict of Interest

None.

8. Acknowledgment


The original research was conducted in LAM Govt. Medical College Raigarh.


References

- Cheng JC, Lam TP, Maffulli N. Epidemiological features of supracondylar fractures of the humerus in Chinese children. *J Pediatr Orthop B*. 2001;10(1):63–7.
- Meyer CL, Kozin SH, Herman SJ, Safer S, Abzug JM. Complications of pediatric supracondylar humeral fractures. *Instr Course Lect*. 2015;64:483–91.

- Wilkins KE. Fractures and Dislocations of the Elbow Region In Rockwood. In: Wilkins KE, King RE, editors. Fractures in Children. vol. 3. Philadelphia: J.B. Lippincott; 1991. p. 509–828.
- Mangwani J, Nadarajah R, Paterson JMH. Supracondylar humeral fractures in children: ten years' experience in a teaching hospital. *J Bone Joint Surg Br*. 2006;88(3):362–5.
- Anwar W, Rahman N, Iqbal MJ. Comparison of the two methods of percutaneous K wire fixation in displaced supracondylar fracture of humerus in children. *J Postgrad Med Inst*. 2011;25(4):356–61.
- Qayyum N. What to do with Gartland type III supracondylar fractures of humerus in children- study of 84 patients. *J Pak Orthop Assoc*. 2008;20(1):71–5.
- Flynn JC, Matthews JG, Beriot RL. Blind pinning of displaced supracondylar fracture of humerus in children. *J Bone Joint Surg Am*. 1974;56(2):263–72.
- Bhan S. Technique of closed reduction and crossed percutaneous pinning of widely displaced supracondylar fractures of humerus in children. *Orthop Today*. 2003;4:214–8.
- Laud NS, Kumta S, Suryanarayana. Open reduction of displaced supracondylar fracture of the humerus in children result of 100 consecutive cases. *Clin Ortho India*. 1988;2:41–55.
- Pirone AM, Graham HR, Krajchich JI. Management of displaced extension -type supracondylar fractures of the humerus in children. *J Bone Joint Surg Am*. 1988;70(5):641–50.
- Fowles JV, Kassab MT. Displaced supracondylar fractures of the elbow in children. *J Bone Joint Surg Br*. 1974;56(3):490–500.
- Hamid RM, Charles S. crossed pin fixation of displaced supracondylar humerus fracture in children. *CORR*. 2000;376:56–61.
- Mehlman C, Strub WM, Roy DR, Wall EJ, Crawford AH. The effect of surgical timing on the perioperative complications of treatment of supracondylar humerus fractures in children. *J Bone Joint Surg Am*. 2001;83(3):323–7.

Author biography

Pravin Kumar Jangde, Associate Professor  <https://orcid.org/0000-0002-9203-638X>

Sanjay Kumar Ghilley, Assistant Professor  <https://orcid.org/0000-0001-5132-824X>

Cite this article: Jangde PK, Ghilley SK. To evaluate the outcome of fracture supracondylar humerus managed with percutaneous lateral pinning in children. *Indian J Orthop Surg* 2022;8(3):219-221.