

Content available at: <https://www.ipinnovative.com/open-access-journals>

Indian Journal of Orthopaedics Surgery

Journal homepage: <https://www.ijos.co.in/>

Case Report

A case of staged revision cementless Total Hip Arthroplasty following post traumatic periprosthetic Vancouver type B fracture after hemiarthroplasty

Rahul Puranik¹, Prithviraj Anil Paigude^{1,*}, Shubham Nitin Katti¹, Saiel Kumarjuvekar¹, Hitarth Gathani¹, Rohit Jadhav¹

¹B J Government Medical College, Pune, Maharashtra, India



ARTICLE INFO

Article history:

Received 17-10-2022

Accepted 29-10-2022

Available online 30-11-2022

Keywords:

Periprosthetic

Vancouver

Total hip arthroplasty

Hemiarthroplasty

Girdlestone

ABSTRACT

The overall incidence of different types of periprosthetic fractures is on the rise constantly due to the increasing volume of primary joint arthroplasties and revision arthroplasties. Skills pertaining to advanced complex trauma and arthroplasty are necessary to manage these injuries. In spite of various algorithms and classifications available regarding management of these injuries, it is necessary for the treating surgeon to understand that the treatment of periprosthetic fractures needs to be individualised optimal for that particular patient. We present our experience in a case of post traumatic periprosthetic Vancouver type B fracture after hemiarthroplasty treated with staged revision cementless long stem Total Hip Arthroplasty (THA).

This is an Open Access (OA) journal, and articles are distributed under the terms of the [Creative Commons Attribution-NonCommercial-ShareAlike 4.0 License](https://creativecommons.org/licenses/by-nc-sa/4.0/), which allows others to remix, tweak, and build upon the work non-commercially, as long as appropriate credit is given and the new creations are licensed under the identical terms.

For reprints contact: reprint@ipinnovative.com

1. Introduction

Arthroplasties are one of the most common and successful surgeries worldwide. This has given rise to increased number of Periprosthetic fractures. Periprosthetic fractures of the femur are associated with high levels of morbidity and are challenging for the treating surgeon as well. Common causes of these injuries include trauma, poor positioning of the implants and other several patient specific factors.¹ One of the most common classifications systems include the Vancouver classification.² Successful outcome of these debilitating injuries require a very specific skill set pertaining to arthroplasty and complex advanced trauma. The economic burden on healthcare systems due to these injuries is also significant.³ Respect for the soft tissue, fundamentals of fracture management, composite implant solutions along with appropriate achievement of length, rotation and alignment is necessary for optimal management

of the complex injuries.

2. Case Report

A 60-year-old male, presented to us with history of trauma to left hip following road traffic accident while driving a two-wheeler. At presentation, he did not suffer from any other injuries and was hemodynamically stable.

Patient was an operated case of same side cemented bipolar hemiarthroplasty one year ago in another hospital in view of displaced fracture neck of femur and did not have any complaints prior to the hospital.

Evaluation: Radiographs involving anteroposterior view of pelvis with both hips and orthogonal views of the affected hip were taken and they showed periprosthetic Vancouver type B fracture with deformation of the implant stem. Signs of infection were ruled out.

Management: A detailed staged procedure was planned following normal pre anesthetic check up. In the first setting, the patient underwent surgery under spinal anaesthesia in

* Corresponding author.

E-mail address: prithvirajpaigude8111@gmail.com (P. A. Paigude).

lateral decubitus. Using the previous incision via Southern Moore approach, the implant and cement was removed using revision hip surgery instruments and the fractures in the metaphyseal region were managed with open reduction internal fixation (ORIF) using interfragmentary screws and a bridging proximal femoral locking plate providing the patient with a girdlestone arthroplasty. Girdlestone arthroplasty was the plan of action due to current financial reasons of the patient.

After an uneventful post operative period, the patient was discharged with girdlestone arthroplasty and advised continuous skin traction to maintain the hip joint volume, limb length and abductor function. Four months post operatively the patient presented with complete radiological and clinical union of the fracture site and maintenance of the hip joint volume.

The patient was operated now for a left sided Cementless long stem total hip replacement with prior implant removal under spinal anaesthesia using the same approach. Post operatively, the patient was stable with no distal neurovascular deficit and no limb length discrepancy. Patient has excellent functional outcome post-operatively as per the Harris hip score.

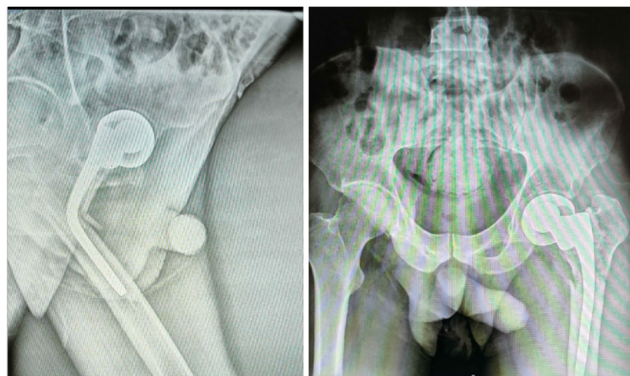


Fig. 1: AP and Lat radiographs showing Vancouver type B periprosthetic fracture in an operated hemiarthroplasty

3. Discussion

Periprosthetic femur fractures following arthroplasties are challenging scenarios. Various factors such as the patient specific characteristics, the appropriate fixation methods (ORIF vs revision), the decision making and planning of the surgical management (fracture classification, the stability of the existing prosthesis, the existing bone stock), configuration of the construct play a crucial role in their management. In spite of various algorithms and classifications available regarding management of these injuries, it is necessary for the treating surgeon to understand that the treatment of periprosthetic fractures needs to be individualised optimal for that particular patient. Consercative management of periprosthetic femur fractures

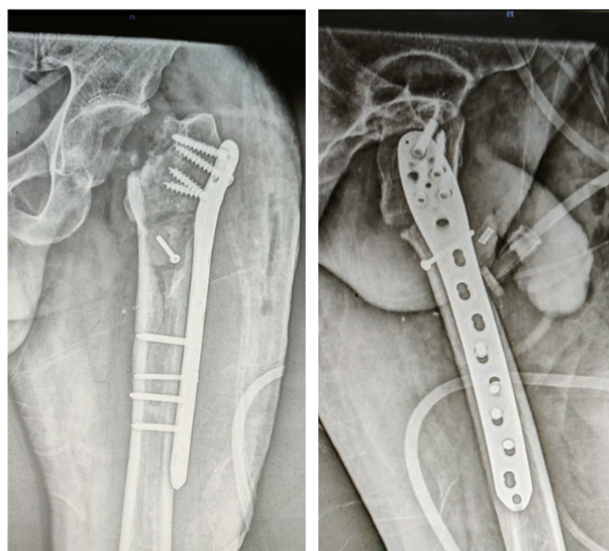


Fig. 2: AP and lateral radiographs showing immediate post operative fixation with girdlestone arthroplasty

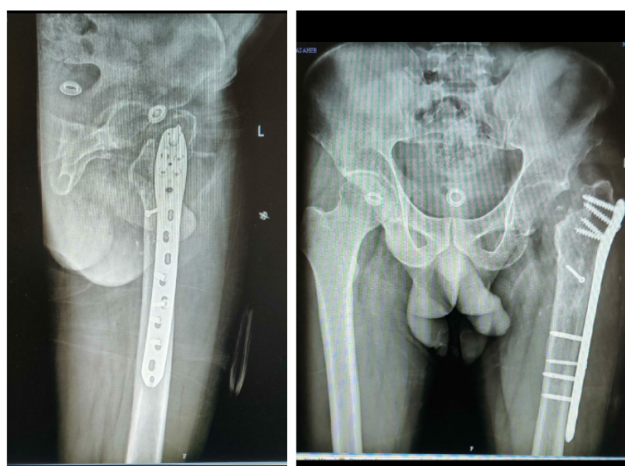


Fig. 3: Lateral and AP radiographs showing complete union at 4 months post operatively with girdlestone arthroplasty

has been associated with poor outcomes in the form of non union, delayed union and malunions leading to increased morbidity and mortality.⁴

Amongst the Vancouver subtypes for periprosthetic fractures, type B specifically represent challenging conditions determining whether (1) loose existing prosthesis (B2 subtype) or not (B1 subtype); (2) compromised existing bone stock (B3 subtype), which demand more advanced techniques in revision arthroplasty. The management is targeted in order to achieve normal mechanical and anatomical alignment of the affected limb, providing a stable implant with maintaining the bone stock, thus leading to early fracture union providing the patient with early post operative rehabilitation and return to activities of

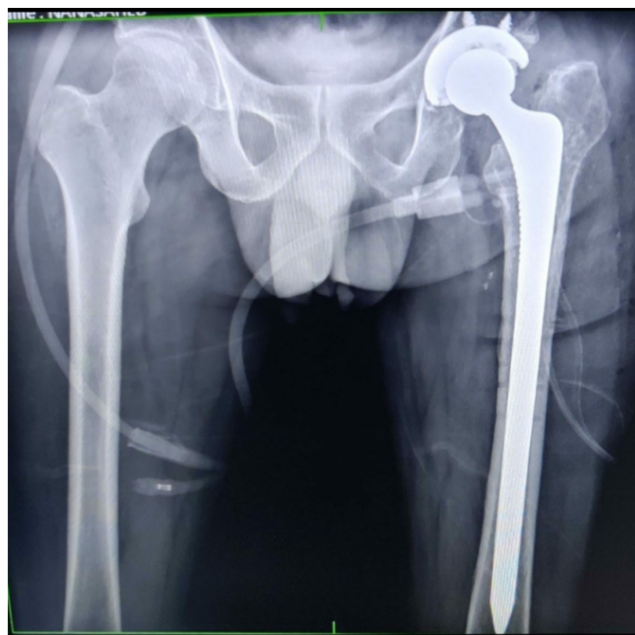


Fig. 4: Final post operative x-ray showing uncemented long stem total hip replacement

daily living as soon as possible.

Bridging locking plates is nowadays a favourite technique of internal fixation. Bridging plates act as extra medullary splints, providing fixed angle constructs ideal for fixation of the osteoporotic/penic bone.

Leg length discrepancy, abductor dysfunction and bone loss are the common technical difficulties faced during conversion of girdlestone or excision arthroplasties to total hip arthroplasties.^{5,6} The clinical outcome for conversion from girdlestone to Total Hip Arthroplasty (THA) is comparable with conventional revision surgery.⁷ Many authors show improved function, pain and range of motion after conversion of excision or girdlestone Arthroplasty to total hip Arthroplasty.⁸ Some authors suggest one year to be optimal time interval between removal and reinsertion of implants.⁹

Long porous coated cement less stem which bypasses the defect or the fracture are required while treating type B Vancouver periprosthetic fractures.^{10,11} Some authors have found the management of type B fractures with ORIF alone have poor outcomes compared to revision surgery.^{12,13}

The results of our study were similar to other studies with good functional outcome following revision staged long stem Cementless Arthroplasty following Periprosthetic femur fractures with an interval girdlestone Arthroplasty.

4. Conclusion

Periprosthetic femur fractures are complex Orthopedic pathologies and require a intricate knowledge and skill of trauma as well as Arthroplasty in order to provide optimal

care for the patient and ensure satisfactory functional outcome. In our experience, we were able to achieve good results following staged revision Arthroplasty using girdlestone Arthroplasty and ORIF as an interval in financially stringent conditions in a case of Periprosthetic complex Vancouver type B fracture after hemiarthroplasty. However, long term and multicentric studies are required for further information pertaining to such scenarios.

5. Abbreviations

ORIF - Open reduction internal fixation; THA - Total hip Arthroplasty; AP - Anteroposterior

6. Source of Funding

No funding sources

7. Conflict of Interest


None declared.


References


- Franklin J, Malchau H. Risk factors for periprosthetic femoral fracture. *Injury*. 2007;38(6):655–60.
- Duncan CP, Masri BA. Fractures of the femur after hip replacement. *Instr Course Lect*. 1995;44:293–304.
- Jones AR, Williams T, Paringe V, White SP. The economic impact of surgically treated peri-prosthetic hip fractures on a university teaching hospital in Wales 7.5-year study. *Injury*. 2016;47(2):428–31.
- Giannoudis PV, Kanakaris NK, Tsiroidis E. Principles of internal fixation and selection of implants for periprosthetic femoral fractures. *Injury*. 2007;38(6):669–87.
- Charlton WP, Hozack WJ, Teloken MA, Rao R, Bissett GA. Complications associated with re-implantation after Girdlestone arthroplasty. *Clin Orthop Relat Res*. 2003;407:119–26.
- Dallari D, Fini M, Carubbi C, Giavaresi G, Rani N, Piccolo ND, et al. Total hip arthroplasty after excision arthroplasty: indications and limits. *Hip Int*. 2011;21(4):436–40.
- Garcia-Rey E, Madero R. Clinical outcome following conversion of Girdlestone's resection arthroplasty to total hip replacement: a retrospective matched case-control study. *Bone Joint J*. 2014;96-B(11):1478–84.
- Charlton WP, Hozack WJ, Teloken MA, Rao R, Bissett GA. Complications associated with re-implantation after Girdlestone arthroplasty. *Clin Orthop Relat Res*. 2003;407:119–26.
- Schröder J, Saris D, Besselaar PP, Marti RK. Comparison of the results of the Girdlestone pseudoarthrosis with reimplantation of a total hip replacement. *Int Orthop*. 1998;22(4):215–8.
- Abdel M, Cottino U, Mabry TM. Management of periprosthetic femoral fractures following total hip arthroplasty: a review. *Int Orthop*. 2015;39(10):2005–10.
- Thomsen PB, Jensen NJF, Kampmann J, Hansen TB. Revision hip arthroplasty with an extensively porous-coated stem - excellent long-term results also in severe femoral bone stock loss. *Hip Int*. 2013;23(4):352–8.
- Khan T, Grindlay D, Ollivere BJ, Scammell BE, Manktelow ARJ, Pearson RG. A systematic review of Vancouver B2 and B3 periprosthetic femoral fractures. *Bone Joint J*. 2017;99-B(4 Supple B):17–25.
- Lindahl H, Garellick G, Regné H, Herberts P, Malchau H. Three hundred and twenty-one periprosthetic femoral fractures. *J Bone Joint Surg Am*. 2006;88(6):1215–22.

Author biography


Rahul Puranik, Associate Professor  <https://orcid.org/0000-0003-0638-7165>

Prithviraj Anil Paigude, Resident Doctor  <https://orcid.org/0000-0001-6792-5567>

Shubham Nitin Katti, Resident Doctor  <https://orcid.org/0000-0001-8457-8931>

Saiel Kumarjuvekar, Resident Doctor  <https://orcid.org/0000-0003-2409-1675>

Hitarth Gathani, Resident Doctor  <https://orcid.org/0000-0002-0555-9167>

Rohit Jadhav, Resident Doctor  <https://orcid.org/0000-0003-4294-0482>

Cite this article: Puranik R, Paigude PA, Katti SN, Kumarjuvekar S, Gathani H, Jadhav R. A case of staged revision cementless Total Hip Arthroplasty following post traumatic periprosthetic Vancouver type B fracture after hemiarthroplasty. *Indian J Orthop Surg* 2022;8(4):302-305.