

Content available at: <https://www.ipinnovative.com/open-access-journals>

Indian Journal of Orthopaedics Surgery

Journal homepage: <https://www.ijos.co.in/>

Case Report

Spinal tuberculosis at an uncommon site (L5-S1): A case report and review of literature

Sagar Arora^{1,*}, Kapil Bansal¹, Raj Bahadur¹, Nitish Garg¹, Jaspreet Kaur²

¹Dept. of Orthopaedics, Guru Gobind Singh Medical College, Faridkot, Punjab, India

²Dept. of Anaesthesia, Guru Gobind Singh Medical College, Faridkot, Punjab, India



ARTICLE INFO

Article history:

Received 10-11-2022

Accepted 18-11-2022

Available online 30-11-2022

Keywords:

Spinal tuberculosis

Lumbosacral

Antitubercular

TB

ABSTRACT

Lumbosacral junction represents an uncommon site for tuberculosis with very few cases reported. We present a case report of 42-year old male with diagnosis of Spinal tuberculosis at L5-S1 who was treated with Posterior decompression and pedicle screw fixation along with the cover of ATT.

This is an Open Access (OA) journal, and articles are distributed under the terms of the [Creative Commons Attribution-NonCommercial-ShareAlike 4.0 License](https://creativecommons.org/licenses/by-nc-sa/4.0/), which allows others to remix, tweak, and build upon the work non-commercially, as long as appropriate credit is given and the new creations are licensed under the identical terms.

For reprints contact: reprint@ipinnovative.com

1. Introduction

Spinal tuberculosis is the commonest form of skeletal tuberculosis, accounting 50% and mainly involves the thoracolumbar and thoracic region.^{1,2} Lumbosacral junction represents an uncommon site for tuberculosis with very few cases reported.³⁻⁵ In this article, we present a case report of Spinal Tuberculosis at an uncommon site i.e Lumbosacral junction which was treated successfully along with relevant review of literature.

2. Case Report

A 42 year-old gentleman presented with the chief complaint of pain in his lower back region from the last 3 months which was gradual in onset, progressive dull aching pain, bilaterally radiating to both lower limbs which was more on left side along with numbness. Patient had a history of low-grade fever and weight loss. There was no specific history of direct contact with TB patients. Patient is on Anti-tuberculosis medicine for the last 1 month.

On examination, the patient was calm, conscious, and well oriented to time, place, and person. His CVS, Pulmonary, and abdominal system were normal. There was no significant inspeactory finding. On palpation, Localised tenderness was present over the lumbosacral region. His motor and sensory examination revealed no deficit in the upper limbs. However, in the lower limbs, plantar flexion at the ankle had a power of 4/5 MRC grading. Motor Power at Hip and Knee were normal. Sensory examination revealed impaired sensation to touch in the L5-S1 distribution in both lower limbs. Straight leg raise was 40 degrees on the left side. Knee reflex and ankle jerk were normally elicitable. Superficial abdominal reflexes were normally present. Plantar reflexes were absent on both lower limbs.

Investigations: Hematology reports showed 9 g/dl hemoglobin, elevated erythrocyte sedimentation rate (55 mm/1 h), and C-Reactive protein (20 mg/l). Other parameters were within normal range.

Plain Radiograph of the lumbosacral spine anteroposterior and lateral views showed reduced disc space between L5 and S1 with irregular margins (Figure 1). MRI of lumbosacral region T1-weighted, T2-weighted, and Short Tau Inversion Recovery (STIR), axial and sagittal

* Corresponding author.

E-mail address: sagar.arora504@gmail.com (S. Arora).

images showed erosion and signal alteration in the L5 and S1 Vertebrae, altered signal intensity involving L5–S1 disc, and thecal sac compression (Figures 2, 3, 4 and 5).

Treatment: The patient underwent posterior decompression and pedicle screw fixation at L5 and S1.(Figure 6) Granulation tissue which was present around the sac was removed and abscess was evacuated from the paradiscal region by cutting down the PLL. Bone graft was taken from the posterior iliac crest and L5-S1 transverse process fusion was done. Samples were taken and sent for Histopathology, CBNaat and for AFB culture. CBNaat and culture were positive for Mycobacterium Tuberculosis. Histopathological report showed granulomas with epithelioid cells and Langhans giant cells suggestive of tuberculosis. On follow-up, there was significant improvement and the patient was completely pain free.

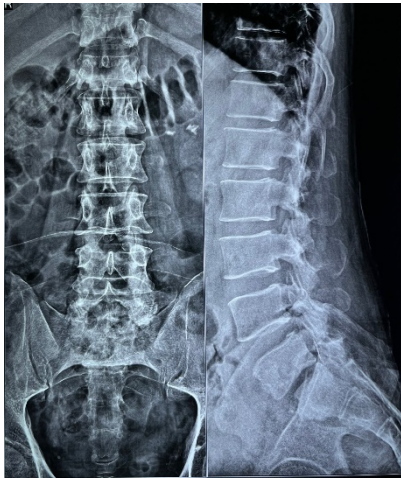

Fig. 1:

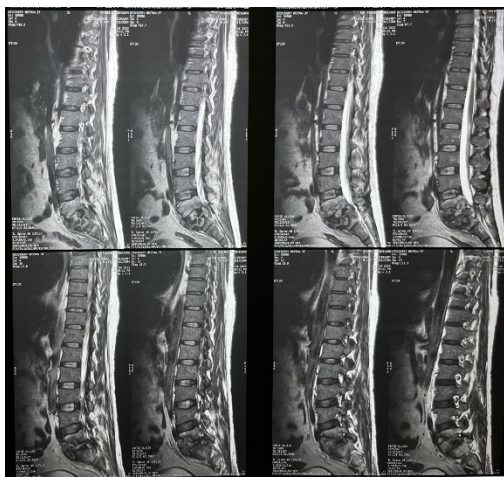


Fig. 2:

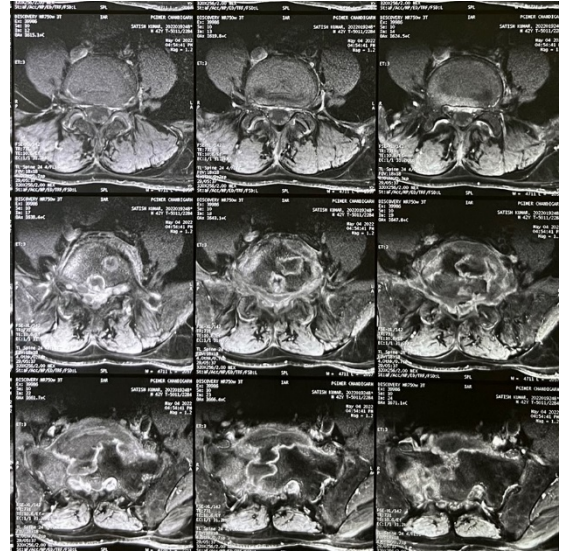


Fig. 3:

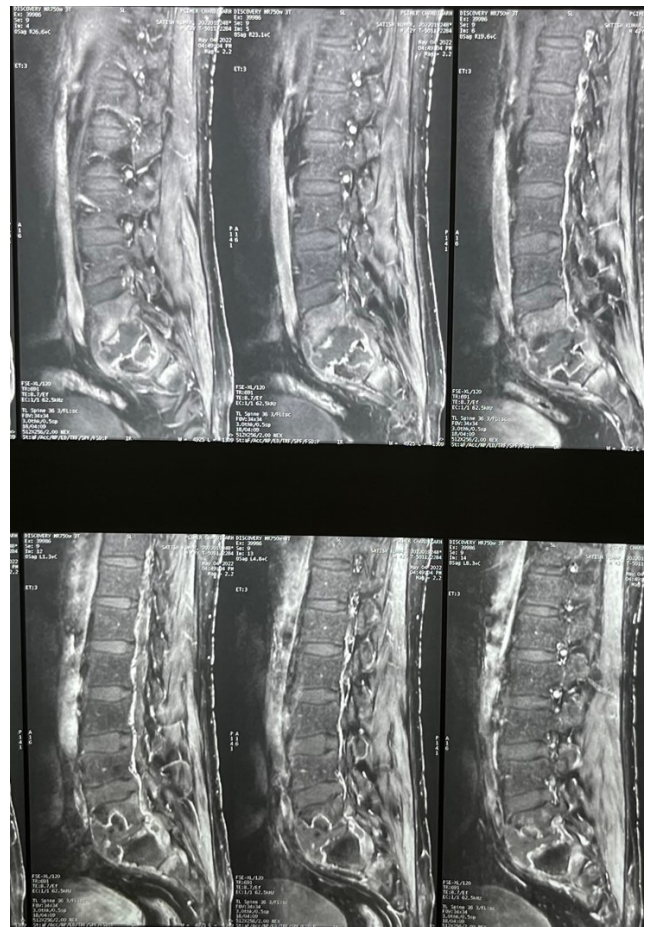


Fig. 4:

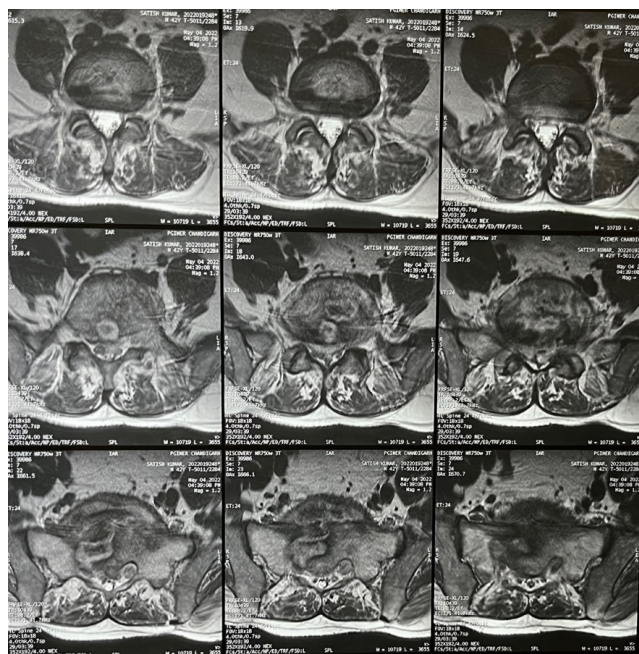


Fig. 5:

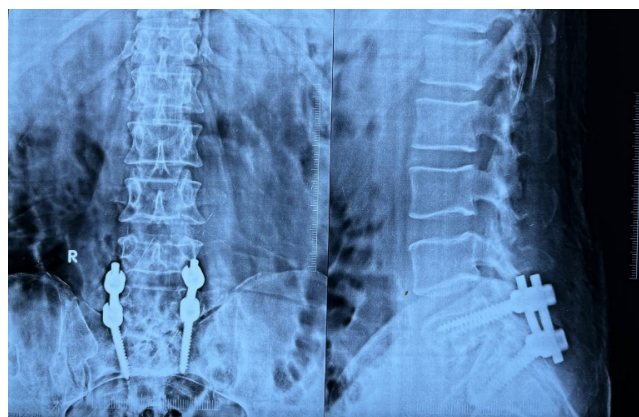


Fig. 6:

3. Discussion

Tuberculosis has been around mankind for a very long time. Percival Pott first described tuberculosis of the spinal column in 1779, but till date, there are no acknowledged and clear-cut treatment guidelines available. Lumbosacral tuberculosis clinically presents with low back pain with or without neurological compromise.^{6,7} This different behaviour of lumbosacral tuberculosis in comparison to other sites of the spine is due to the capacious spinal canal and floating nerve roots (relatively tolerant to compression by an abscess or by granulation tissue).^{8,9} Diagnosis of spinal tuberculosis is made clinically, microbiologically and radiologically. Microbiological confirmation requires the demonstration of acid-fast bacilli on microscopy or culture of material obtained following a biopsy of the

lesion.¹⁰ Polymerase chain reaction is a very effective method for bacteriological diagnosis of tuberculosis as it can detect as few as 10–50 tubercle bacilli.¹¹ Radiological investigation comprised of plain radiographs, computed tomographic scan, and MRI. Disc space narrowing, irregular margins, abnormal paravertebral masses, and abnormal calcifications in the soft tissue are the usual findings on plain radiograph.¹² CT helps in delineating the encroachment of the spinal canal by posterior extension of inflammatory tissue, bone, or disk material.¹³ MRI is the investigation of as it shows better details of the pathology and demonstrates spinal canal compromise.¹⁴ Once the diagnosis of skeletal tuberculosis is established, conservative management with an adequate course of antituberculosis can result in a good outcome.^{15,16} Certain conditions such as compression of neural structures or persistent pain and/or instability demand surgical intervention under the cover of antitubercular chemotherapy are recommended.⁸ Potential benefits of surgery were less kyphosis, immediate relief of compressed neural tissue, quicker relief of pain, higher percentage of bony fusion, quicker bony fusion, less relapse, earlier return to previous activities, and less bone loss.¹⁷ Various surgical approaches are present such as anterior fusion, posterior fusion or combined approach. However, the approach used depends upon the symptoms and radiological findings.

4. Conclusion

Spinal Tuberculosis at lumbosacral junction is not only uncommon region wise but also behaves uncommonly with pain and minimal neurological deficits. Antitubercular therapy with surgical intervention is the mainstay treatment with added advantages of surgery such as thorough debridement and stabilization resulting in quicker pain relief and neurological recovery.

5. Source of Funding

None.

6. Conflict of Interest

None.

References

1. Yao DC, Sartoris DJ. Musculoskeletal tuberculosis. *Radiol Clin North Am.* 1995;33:679–89.
2. Jain AK, Dhammi IK. Tuberculosis of the spine: a review. *Clin Orthop Relat Res.* 2007;460:39–49.
3. Tuli SM. Results of treatment of spinal tuberculosis by 'middle-path' regime. *J Bone Joint Surg Br.* 1975;57(1):13–23.
4. Wellons JC, Zomorodi AR, Villavicencio AT, Woods CW, Lawson WT, Eastwood JD. Sacral tuberculosis: a case report and review of the literature. *Surg Neurol.* 2004;61(2):136–9.
5. Patel P, Patel D, Shah K, Agarwal D. Tuberculosis of the lumbosacral junction. *Ind J Orthop.* 2000;34:252–5.
6. Desai SS. Early diagnosis of spinal tuberculosis by MRI. *J Bone Joint Surg Br.* 1994;76(6):863–9.

7. Patankar T, Krishnan A, Patkar D, Kale H, Prasad S, Shah J, et al. Imaging in isolated sacral tuberculosis: a review of 15 cases. *Skeletal Radiol.* 2000;29(7):392–6.
8. Bhojraj S, Nene A. Lumbar and lumbosacral tuberculous spondylodiscitis in adults. Redefining the indications for surgery. *J Bone Joint Surg Br.* 2002;84(4):530–4.
9. Karaeminogullari O, Aydinli U, Ozerdemoglu R, Ozturk C. Tuberculosis of the lumbar spine: outcomes after combined treatment of two-drug therapy and surgery. *Orthopedics.* 2007;30(1):55–9.
10. Skaf GS, Kanafani ZA, Araj GF, Kanj SS. Non-pyogenic infections of the spine. *Int J Antimicrob Agents.* 2010;36(2):99–105.
11. Singh UB, Seth P. PCR diagnosis of tuberculosis-experience in India. *Indian J Pediatr.* 2002;69(Suppl 1):20–4.
12. Moore SL, Rafii M. Imaging of musculoskeletal and spinal tuberculosis. *Radiol Clin North Am.* 2001;39(2):329–42.
13. Ridley N, Shaikh MI, Remedios D, Mitchell R. Radiology of skeletal tuberculosis. *Orthopedics.* 1998;21(11):1213–20.
14. Maiuri F, Iaconetta G, Gallicchio B, Manto A, Briganti F. Spondylodiscitis. Clinical and magnetic resonance diagnosis. *Spine (Phila Pa 1976).* 1997;22(15):1741–6.
15. Nussbaum ES, Rockswold GL, Bergman TA, Erickson DL, Seljeskog EL. Spinal tuberculosis: a diagnostic and management challenge. *J Neurosurg.* 1995;83(2):243–7.
16. Rezaei AR, Lee M, Cooper PR, Errico TJ, Koslow M. Modern management of spinal tuberculosis. *Neurosurgery.* 1995;36(1):87–97.
17. Leong JC. Tuberculosis of the spine. *J Bone Joint Surg Br.* 1993;75(2):173–5.

Author biography

Sagar Arora, Senior Resident

Kapil Bansal, Professor

Raj Bahadur, Professor

Nitish Garg, Junior Resident

Jaspreet Kaur, Junior Resident

Cite this article: Arora S, Bansal K, Bahadur R, Garg N, Kaur J. Spinal tuberculosis at an uncommon site (L5-S1): A case report and review of literature. *Indian J Orthop Surg* 2022;8(4):306-309.