



Original Research Article

Technique of tension band wiring in patella fracture management-our experience

Veerabhadra Javali^{1,*}, Mahindra S N¹¹Dept. of Orthopedics, Karwar Institute of Medical Sciences, Karwar, Karnataka, India

ARTICLE INFO

Article history:

Received 16-11-2022

Accepted 29-11-2022

Available online 14-03-2023

Keywords:

Patella fractures

K-wires

Tension band wiring (TBW)

ABSTRACT

Background: Fractures of the patella account for about 1% of all skeletal injuries. Displaced patella fractures often result in disruption of the extensor mechanism of the knee. Open reduction and internal fixation is the recommended treatment to restore the extensor mechanism. Tension band wiring (TBW) technique using K-wires and stainless steel wires is the most commonly used. The purpose of this study is to study surgical outcome of patella fractures treated with tension band wiring (TBW) technique and functional outcome of patella fractures treated with TBW technique.

Materials and Methods: It is a Retrospective study of 21 patients carried out from July 2019 to February 2021 admitted to orthopedic ward at our institution. All patients underwent same surgical technique and similar postoperative and physiotherapy protocol. Bostman scoring system was used to perform functional assessment.

Results: In our study there were 14 males and 7 females. Fracture union was achieved in all patients. The mean bostman score was 26.54 at the final follow up. We had 4 complications: 1 superficial infection of the surgical wound, 1 knee stiffness and 2 cases of symptomatic implant. We had 8 excellent, 9 good and 4 satisfactory result.

Conclusion: Tension band wiring technique for transverse patella fractures can be a very good option with effective fixation method and relatively easy surgical procedure.

This is an Open Access (OA) journal, and articles are distributed under the terms of the [Creative Commons Attribution-NonCommercial-ShareAlike 4.0 License](https://creativecommons.org/licenses/by-nc-sa/4.0/), which allows others to remix, tweak, and build upon the work non-commercially, as long as appropriate credit is given and the new creations are licensed under the identical terms.

For reprints contact: reprint@ipinnovative.com

1. Introduction

Fractures of patella are common injuries seen in adults. Patellar fractures are commonly seen in the age group of 20-50 years and comprise about 1% of all skeletal injuries.¹ Fractures can be displaced and undisplaced. The fracture pattern can be transverse, vertical, stellate or comminuted. Transverse fracture patterns are the most common type. Displaced fractures are associated with failure of extensor mechanism at knee.^{2,3} The other consequence of these displaced fractures is mismatch of the patellofemoral articulation. In such cases, open reduction and internal fixation is the recommended treatment to get anatomic

reduction, stable fixation, restore the extensor mechanism as well and allow early knee movements and rehabilitation.

Tension band wiring (TBW) technique using K-wires and stainless steel wires is the most commonly used. In our setup we have come across patella fractures frequently and hence present study taken up to evaluate the outcome of patella fractures.

2. Materials and Methods

This study is a retrospective study of 21 patients carried out from July 2019 to February 2021 admitted to orthopedic ward at our hospital treated with open reduction and internal fixation with TBW. Patient detailed history was taken to know the duration and the mode of injury. Radiographs

* Corresponding author.

E-mail address: drjavali@yahoo.co.in (V. Javali).

of the knee obtained. Patients were recruited according to particular inclusion and exclusion criteria.

1. Inclusion criteria consisted of the patients between 18 years to 60 years age and displaced transverse patella fractures.
2. Exclusion criteria were those with comminuted patella fractures, patella fractures with associated other injuries, polytrauma patients and surgically unfit patients.

All patients after obtaining physical fitness and consent underwent surgery. AO Tension band wiring was the method used for all.⁴ After regional (spinal anaesthesia) patient in supine position parts prepared painted and draped. A linear vertical skin incision taken over the patella and sequential dissection carried out to reach fracture site. Fracture anatomically reduced using a pointed reduction forceps or tenaculum and fluoroscopy guidance. Then two parallel Kirschner wires (K-wires) inserted for securing the reduction. Stainless steel wire (18 gauge wire) was applied as close as possible to the angle between patella and K-wire exposed ends under the tendon, in a figure-of-8 pattern in a vertical orientation. Confirming the reduction once again, the construct is tightened by knotting the stainless steel wires at superolateral aspect of the patella. After tightening the figure-of-eight wire, proximal pin ends were bent, shortened, turned them towards the quadriceps tendon, and driven them into the patella to prevent skin irritation and loosening. The distal pin ends were cut to remove the sharp points and not bent, for easier removal.

All patients underwent similar antibiotic prophylaxis, postoperative and physiotherapy protocol. Static Quadriceps strengthening exercises were started and the patients were mobilized on day 1 unless patient is not very keen and having pain, with full weight-bearing walking. Wound inspections were done on day 2, and if necessary subsequent dressing or directly suture removed on day 10. Patients were followed up every 2 weeks once for first month and then once in month till last follow up. Each time clinical and functional assessment was carried out. Both clinical and radiological assessments were done for fracture healing and functional recovery. Patients were evaluated using the Bostman scoring.⁵

3. Results

Our study included 21 patients with 14 males and 7 females. The mean age of the patients in our study was 43.7 years ranging from 21 to 57 years. The most common type of injury slip and fall 11(52.34%), followed by Road traffic accident 8(38.09%) and 2(9.5%) were sports playtime injuries. The right patella was dominantly involved. Patient demographics and variables is depicted in Table 1.

The mean time for presentation to our hospital after injury was 2.2 days ranging from 1 to 7 days. Patients had

Table 1: Patient demographics and variables

Patient variables	Numbers	
Sex	Male	14 (66.6%)
	Female	7 (33.4%)
Age group	18-30 years	7 (33.3%)
	31-45 years	9 (42.8%)
	46-60 years	5 (23.8%)
Mode of injury	Fall	11 (52.34%)
	Road side accident	8 (38.09%)
	Sports injury(playtime)	2 (9.5%)
Side of injury	Right	13 (61.9%)
	Left	8 (38.09%)

surgery within a mean period of 3 days after presentation. Follow up period ranged between 5 months to 2 years four months. Fracture union was achieved in all patients. The average duration of radiological union was 10.2 weeks. We had 4 complications 1 superficial infection of the surgical wound, 1 knee stiffness and 2 cases of symptomatic implant. The mean bostman score was 26.54 at the final follow up. we had 8 excellent, 9 good and 4 satisfactory result (Table 2).

Table 2: The mean Bostman's score in our study

Bostman's knee score (at final follow up)	Total no of patients
Excellent (28-30)	8
Good (20-27)	9
Satisfactory (<20)	4

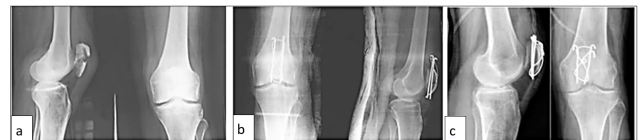


Fig. 1: Radiological illustrations of Patella fracture preoperative (a), Immediate postoperative (b) at final follow up (c)

Figure 1 shows example of one of the patients pre and post-operative images of patella fracture fixation using TBW with successful fracture union achieved in our study.

4. Discussion

The tension band wiring (TBW) technique is a common surgical fixation method followed especially for transverse patella fracture.⁶ It converts the anterior tension forces into compression forces at the articular surface through the extensor mechanism. The purpose of the current study is to determine the surgical and functional outcome of TBW of transverse fracture patella in our setup.

In our study, males were more commonly involved than females with a mean age of 43.7 years Slip and fall was the common mode of injury in our study with right patella being

most involved. In a study by Akhilesh Rathi similar results of patient variables seen with males being most commonly involved with a mean age 40 years and right patella was more involved.⁷ In a study by Sun et al., comparatively females were more involved than males and left patella was predominantly involved which is opposite of the results we have got.⁸ In another study by Huang et al., females were predominantly involved and however fall was the commonest mode of injury as of ours.⁹

The mean union time in our study was 10.2 weeks. Gangadhara Reddy Kota et al. reported that the mean time of fracture union as 14 weeks.¹⁰ In another study by Singh V et al., the average period of union was 12-14 weeks.¹¹ In our study, we noticed 4 complications 1 superficial infection of the surgical wound, 1 knee stiffness and 2 cases of symptomatic implant accounting totally 19.04%. Infection case was managed with daily dressings along with proper antibiotics course. Knee stiffness was probably due to non-compliance of the patient and resolved partially with physiotherapy, symptomatic implant patients were reassured till the fracture union and both the cases underwent implant removal with further no complaints. In some earlier studies the incidence of postoperative infection after fixation of patellar fractures ranged from 3% to 10%, which was similar to the overall incidence of 2.8% in our study.^{12,13} In a study by T K Ong et al., None of the complications were seen.¹⁴ In a study by Khan I et al., the average Bostman score being 27.36 which is near similar score of 26.54 at the final follow up in our study.¹⁵

5. Conclusion

We conclude that Tension band wiring technique for transverse patella fractures can be a very good option with effective fixation method and relatively easy surgical procedure. It acts on the principle of conversion of the tensile forces to compressive forces on knee flexion, facilitating early fracture union and active knee mobilisation.

6. Source of Funding

None.

7. Conflict of Interest

None.


8. Ethical Approval

Approval taken from the institutional ethical committee.

References

- Bostrom A. Fracture of the patella. A study of 422 patellar fractures. *Acta Orthop Scand Suppl.* 1972;143:1-80.
- Benjamin J, Bried J, Dohm M, Mcmurtry M. Biomechanical evaluation of various forms of fixation of transverse patellar fractures. *J Orthop Trauma.* 1987;1(3):219-22.
- Carpenter JE, Kasman RA, Patel N, Lee ML, Goldstein SA. Biomechanical evaluation of current patella fracture fixation techniques. *J Orthop Trauma.* 1997;11(5):351-6.
- Muller ME, Allgower M, Schneider R, Willinger H. Manual of Internal Fixation: Techniques Recommended by the AO Group. Berlin: Springer-Verlag; 1979. p. 248-53.
- Bostman O, Kiviluoto O, Nirhamo J. Comminuted displaced fractures of the patella. *Injury.* 1981;13(3):196-202.
- Weber MJ, Janecki CJ, Mcleod P, Nelson CL, Thompson JA. Efficacy of various forms of fixation of transverse fractures of the patella. *J Bone Joint Surg Am.* 1980;62(2):215-20.
- Rathi A, Swamy MKS, Prasantha I, Consul A, Bansal A, Bahl V. Percutaneous tension band wiring for patellar fractures. *J Orthop Surg (Hong Kong).* 2012;20(2):166-9.
- Sun Y, Sheng K, Li Q, Wang D, Zhou D. Management of comminuted patellar fracture fixation using modified cerclage wiring. *J Orthop Surg Res.* 2019;14:324.
- Huang PH, Hsu CH, Hsu SL, Liu HC. Treatment of displaced fractures of the patella: Tension band wiring technique with the one-end or both-ends K-wire bending fixation method. *J Orthop Surg (Hong Kong).* 2021;29(1). doi:10.1177/23094990211015501.
- Kota GR, Vamshi D. Patellar Fractures Treated by Modified Tension Band Wiring: A Clinical Study in a Teaching Hospitals. *Ann Int Med Den Res.* 2016;2(1):142-5.
- Singh V, Gundavarpu A, Sharma A, Patel T. Management of displaced patella fracture with modified tension band wiring and percutaneous cannulated screws- a dilemma. *Int J Res Orthop.* 2021;7:351-6.
- Haajanan J, Karaharju E. Fractures of the patella. One hundred consecutive cases. *Ann Chir Gynaecol.* 1981;70(1):32-5.
- Hung LK, Chan KM, Chow YN, Leung PC. Fractured patella: operative treatment using the tension band principle. *Injury.* 1985;16(5):343-7.
- Ong TK, Chee EK, Wong CL, Thevarajan K. Fixation of Comminuted Patellar Fracture with Combined Cerclage and Tension Band Wiring Technique. *Malaysian Orthop J.* 2008;2(2):40-2.
- Khan I, Dar MY, Rashid S, Butt MF. Internal Fixation of Transverse Patella Fractures Using Cannulated Cancellous Screws with Anterior Tension Band Wiring. *Malays Orthop J.* 2016;10(2):21-6.

Author biography

Veerabhadra Javali, Associate Professor  <https://orcid.org/0000-0001-9886-164X>

Mahindra S N, Assistant Professor  <https://orcid.org/0000-0003-1675-2197>

Cite this article: Javali V, Mahindra S N. Technique of tension band wiring in patella fracture management-our experience. *Indian J Orthop Surg* 2023;9(1):1-3.