

Content available at: <https://www.ipinnovative.com/open-access-journals>

Indian Journal of Orthopaedics Surgery

Journal homepage: <https://www.ijos.co.in/>

## Original Research Article

## Functional outcome of intra-articular distal humerus fractures treated with locking compression plates – A prospective study

Gagandeep Gupta<sup>1</sup>, Sagar<sup>1,\*</sup>, Sameer Khan<sup>1</sup><sup>1</sup>Dept. of Orthopaedics, Maharishi Markandeshwar Institute of Medical Sciences & Research, Mullana, Haryana, India

## ARTICLE INFO

## Article history:

Received 01-05-2023

Accepted 20-05-2023

Available online 30-05-2023

## Keywords:

Intraarticular distal humerus fracture

Transolecranon

Chevron osteotomy

Bi columnar locking compression plates

MEPS

## ABSTRACT

**Aim & Objectives:** To evaluate the clinical and functional outcome of intra-articular distal humerus fractures treated with locking compression plates.**Materials and Methods:** A total number of 25 patients with intraarticular fractures of the distal humerus, from March 2021 to September 2022 were enrolled in the study. All patients were subjected to relevant investigations after which were taken up for surgical fixation of the fracture with bicolumnar distal humerus locking compression plates applied in orthogonal configuration through a posterior transolecranon approach. Patients were followed up at intervals of 6 weeks, 3 months and 6 months for assessing union and the functional recovery at each follow-up.**Results:** The study population consisted of 19 men and 6 women with mean age of 43.08±11.89 years. Motor Vehicle Accidents (MVA) were the most common cause of injury accounting for 56% of the cases. Most common fracture pattern was AO 13C2, which was observed in 44% of the cases. Mean duration of the fracture healing was 13.40 ± 1.83 weeks. Mean range of flexion arc was 111.20 ± 14.53 degrees. There were 16 patients with excellent MEPS outcome while six patients had good outcome and three patients had reported fair outcome. There were three cases of joint stiffness though had fair MEPS score. Two cases had superficial skin infection and two cases had reported hardware irritation.**Conclusion:** Bi columnar distal humerus locking compression plate is a stable and safe implant for management of intraarticular fractures of distal humerus. The present study shows promising results when the plates are applied in orthogonal configuration through posterior chevron osteotomy approach. A good anatomical fixation allows early mobilization which improves the functional outcome.This is an Open Access (OA) journal, and articles are distributed under the terms of the [Creative Commons Attribution-NonCommercial-ShareAlike 4.0 License](https://creativecommons.org/licenses/by-nc-sa/4.0/), which allows others to remix, tweak, and build upon the work non-commercially, as long as appropriate credit is given and the new creations are licensed under the identical terms.For reprints contact: [reprint@ipinnovative.com](mailto:reprint@ipinnovative.com)

## 1. Introduction

One of the most challenging injuries to repair is a distal humerus fracture. They account for 2-6 percent of all fractures and 30 percent of all elbow fractures.<sup>1</sup> RTA being the most common cause in young population.<sup>2,3</sup> The majority of distal humerus fractures feature a complicated pattern that includes both the medial and lateral columns as well as the articular surface (AO type C injury).<sup>4</sup> The treatment of these fractures has

always been a contentious issue. For these intra-articular fractures, ORIF is the treatment of choice. The goal of treatment is to achieve a painless and functional joint. Bryan-Morrey in their study revealed the permissible range of motion should be at least 30 to 130 degrees.<sup>5</sup> In order to obtain desirable functional outcome following distal humerus fracture, adequate reduction and restoration of fracture must be done for early rehabilitation.<sup>6</sup> The AO/ASIF group has recommended a number of treatment methods for distal humerus fractures. Bicolumnar dual plating or orthogonal/90-90 plating is the gold standard procedure.<sup>7</sup> Double-plate osteosynthesis procedures in

\* Corresponding author.

E-mail address: [sagar3244@gmail.com](mailto:sagar3244@gmail.com) (Sagar).

various configurations have been the treatment of choice in recent years. Few studies on locking compression plates based on clinical and biomechanical functions suggest that LCPs can help with primary stability in distal humerus fracture osteosynthesis.<sup>8</sup> The aim of present study is to evaluate the functional outcome of intra-articular distal humerus fractures treated with locking compression plates applied in orthogonal 90-90° pattern.

## 2. Aims

The aim of the study is to evaluate the functional outcome of intra-articular distal humerus fractures treated with locking compression plates.

## 3. Objectives

1. To assess the clinical and functional outcome.
2. To evaluate the complications if any.

## 4. Materials and Methods

1. Period of study: 18 Months
2. Number of cases: 25

### 4.1. Inclusion criteria

1. Age group: Adults (18 to 60 years) of both sexes.
2. Closed intra-articular distal humerus fracture of type C (AO classification)

### 4.2. Exclusion criteria

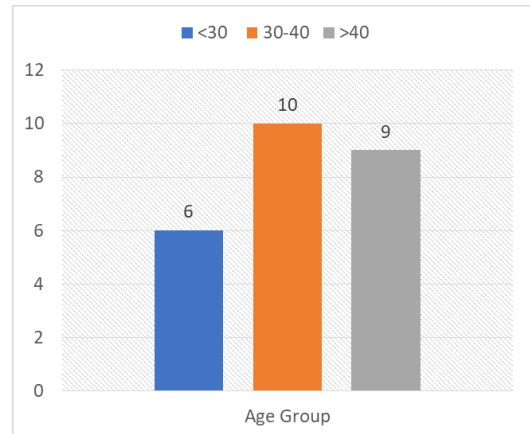
1. Age less than 18 years and Above 60 years.
2. Associated neurovascular injury.
3. Open fracture.
4. Other associated fractures in same limb.
5. Patients of poly-trauma with other associated injuries.

### 4.3. Follow-up and functional assessment

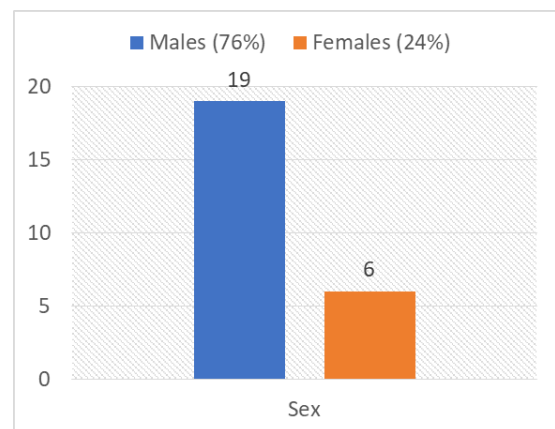
1. Regular follow up was done in OPD to access the progress of fracture union and functional status of the elbow at 6<sup>th</sup> postoperative week and thereafter at 3 months and 6 months.
2. The functional status of the involved limb was assessed using Mayo-Elbow Score (MEPS) at each follow up visit.

## 5. Results

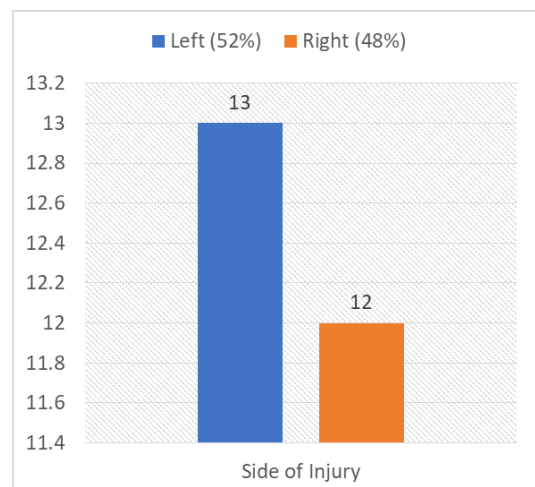
5.1. Age distribution, Sex distribution, Side of Injury, Mode of Injury, Fracture type according to AO Classification, Fracture union and Complications in Graphs 1, 2, 3, 4, 5, 6 and 7.



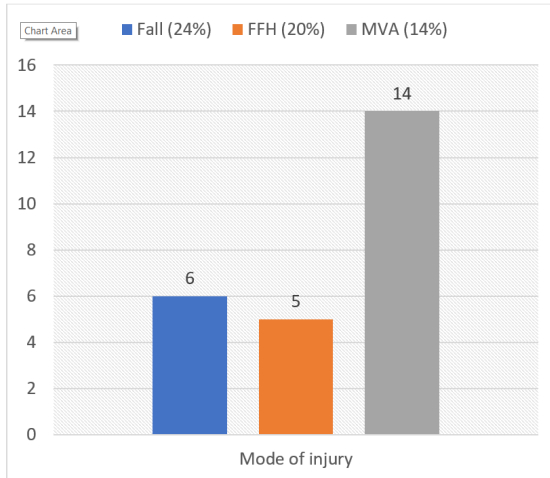
Graph 1: Age distribution



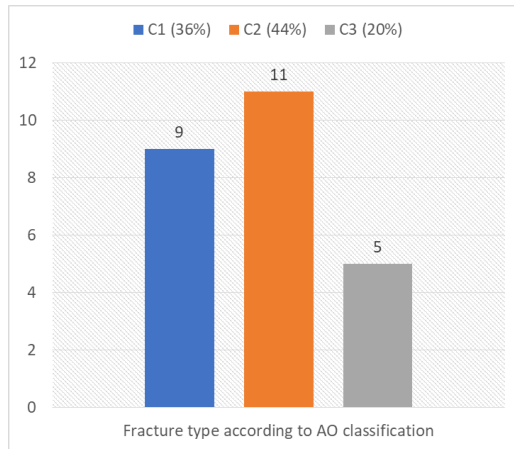
Graph 2: Sex distribution



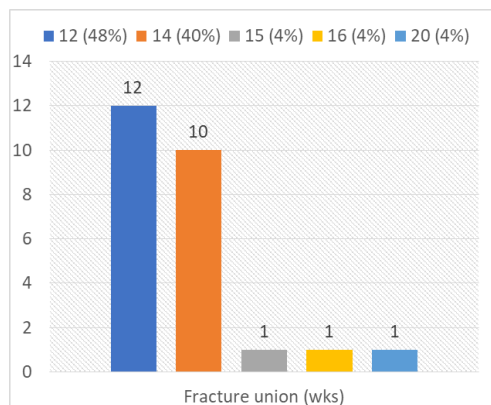
Graph 3: Side of injury



Graph 4: Mode of injury



Graph 5: Fracture type according to AO classification

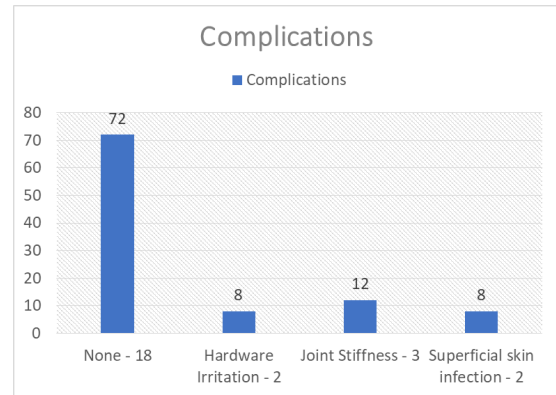


Graph 6: Fracture union

Table 1: Comparison of mean time of fracture union with AO fracture type

Fracture Type	C1 Mean (SD)	C2 Mean (SD)	C3 Mean (SD)	F	p-value
Fracture Union	12.44 (0.88)	13.27 (1.01)	16.80 (4.15)	8.923	0.002

Statistically significant difference was noted in the fracture union time with regard to AO fracture type signifies, less severe the fracture type earlier the fracture union as depicted in Table 1.



Graph 7: Complications

5.2. Functional outcome

5.2.1. Elbow range of motion

Among the study population the mean arc of flexion at 6 month follow up was  $111.20 \pm 14.53$  degree and mean extension deficit was  $10 \pm 4.56$  degree.

Progressive significant improvement was observed in the range of motion from initial mean ROM of  $89.20 \pm 12.56$  degree at 6 weeks to  $111.2 \pm 14.53$  degree at 6 month follow up ( $p=0.001$ ).

5.2.2. Mayo Elbow Performance score

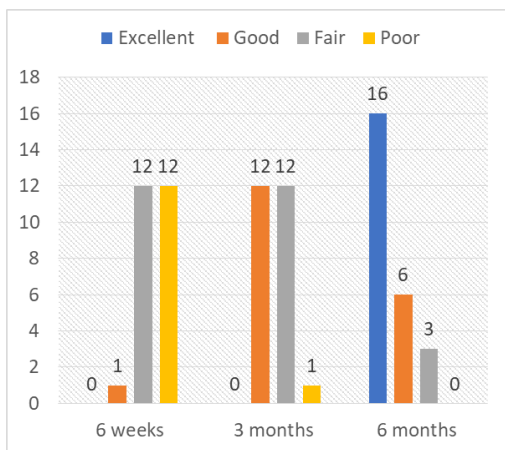
Among the study population Mayo Elbow Performance score at 6 weeks, 3 months and 6 months as depicted in Graph 8.

The mean MEPS of the study population at the end of 6 month follow up was  $87.80 \pm 8.67$ .

Table 2: Comparison of MEPS score with AO fracture types

AO Type	C1	C2	C3	P value
MEPS 6 Wks	56.67	62.0	52.86	0.4
MEPS 3 M	70.83	76.0	70.0	0.3
MEPS 6 M	94.0	87.50	87.71	0.1

On comparison of MEPS score with AO fracture type, improvement was seen in final score with insignificant p



Graph 8: Mayo elbow performance score

values as depicted in Table 2.

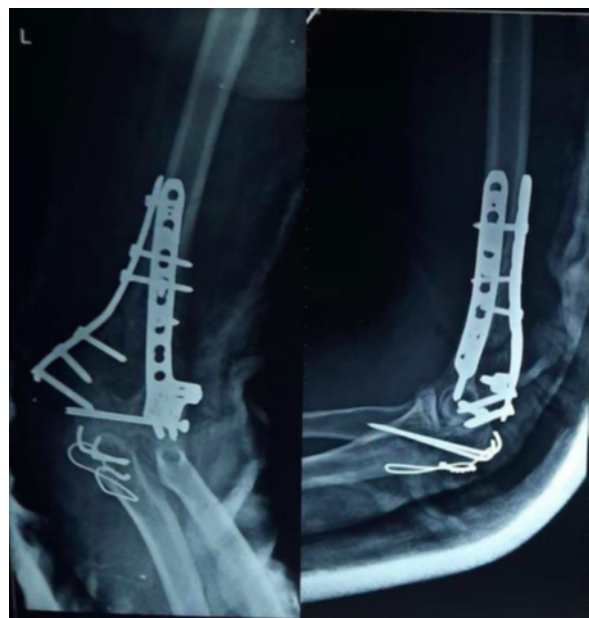

Fig. 2: Post op x-ray

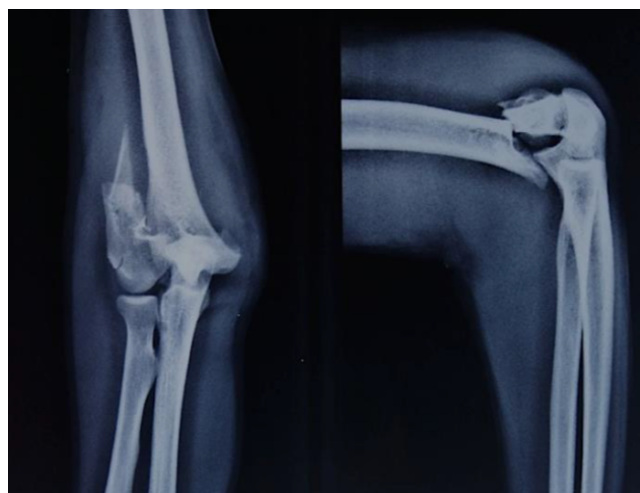

Fig. 1: Pre op x-ray

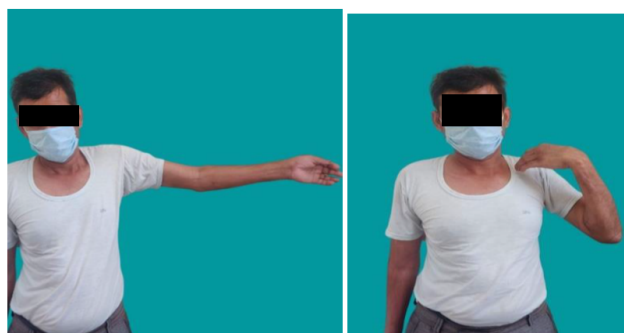

Fig. 3: Functional status at 6 month follow-up

**6. Discussion**

1. Distal humerus fractures in adults remain one of the most challenging fractures to reduce and fix.
2. An adequate return of the elbow range of motion to allow proper and a good functional outcome is major aim for restoration of a distal humerus fractures, especially in cases of intra-articular fracture of distal humerus.
3. These fractures warrant restoration of the articular surface as well as the geometry of the distal humerus along with stable fixation to allow for early healing and quick rehabilitation which are often difficult to achieve.<sup>9</sup>
4. In our study, most of fractures were AO type 13C2 constituting 44% of the fracture pattern. Followed by 13C1 (36%) and 13C3 (20%) of cases. The results were

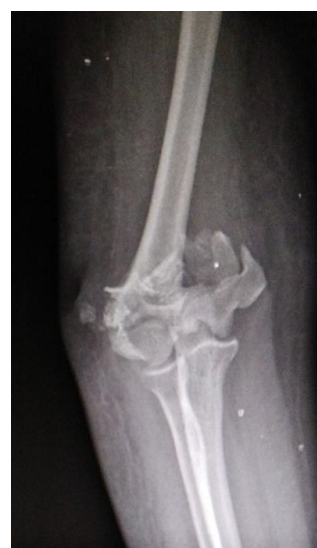
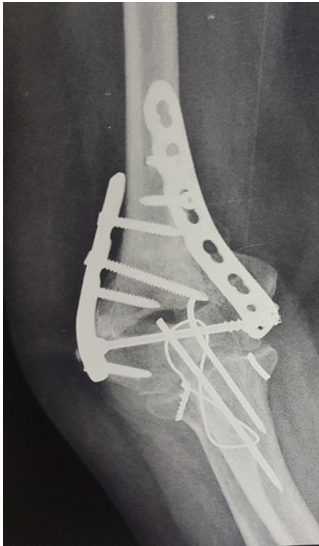
Fig. 4: Pre op x-ray



**Fig. 5:** Post op x-ray



**Fig. 6:** Functional status at 6 month follow-up

comparable with studies conducted by Pereles et al<sup>10</sup> and RE Hughes et al.<sup>11</sup>

5. Mean duration for fracture union in our study population was  $13.40 \pm 1.83$  weeks ranging from 12 to 20 weeks.
6. The average mean time taken by C1 type of fracture for union was  $12.44 \pm 0.88$  weeks which is significantly less when compared with mean time of C2 type fracture i.e.  $13.27 \pm 1.01$  weeks and of C3 type of fracture was  $16.80 \pm 4.15$  ( $p=0.002$ ). Our study was in concurrence with studies conducted by Kiran GU et al<sup>12</sup> and Singh V et al.<sup>13</sup>
7. The mean arc of flexion at 6 month follow up was  $111.20 \pm 14.53$  degree, with mean extension deficit was  $10 \pm 4.56$  degree. The similar results found by Gofton et al,<sup>14</sup> Kundel et al<sup>15</sup> and Aslam et al<sup>16</sup> in their study.

8. The mean MEPS at the end of 6 month follow up was  $87.80 \pm 8.67$ .
9. At 6 months excellent results were found in 64% patients, good results in 24% patients, fair results in 12% patients. Our study is closely comparable with CD Deepak et al,<sup>17</sup> Imran Mang et al<sup>18</sup> and Singh V. et al.<sup>13</sup>
10. Out of 25 operated cases, majority of cases (72%) had no complications. Three patients (12%) reported joint stiffness with decreased range of elbow motion being 20-80°, 20-75° and 20-80° respectively. Two patients (8%) had superficial skin infection, which was managed by regular dressing and antibiotic coverage. Two patients reported hardware irritation. Out of which one patient required k-wire removal at osteotomy site under local anaesthesia. Singh V et al<sup>13</sup> reported a complication rate 22.23%

## 7. Conclusion

Distal humerus fractures are complex fractures and represent 2% of all fractures. Despite being uncommon, distal humerus fractures pose the greatest challenge in terms of surgical fixation and absolute anatomical reduction. Anatomic restoration of the articular surface should be a priority during open reduction internal fixation. Good functional outcomes are expected with articular surface restoration, reconstruction of elbow joint and early rehabilitation.

In our study we treated 25 patients of distal humerus intra articular fracture with open reduction and internal fixation using 3.5mm distal humerus locking compression plates and functional outcome was good to excellent in 88% patients.

To conclude distal humerus locking compression plate is a stable and safe implant in management of intraarticular fractures of the distal humerus.

However, a more comprehensive study with longer follow-up periods and larger sample size is essential to throw more light into the advantages, complications and possible disadvantages of the use of locking compression plate with special attention to the long-term outcomes.

## 8. Source of Funding

None.

## 9. Conflict of Interest


None.


## References

1. Rose SH, Melton LJ, Morrey BF, Ilstrup DM, Riggs BL. Epidemiologic features of humeral fractures. *Clin Orthop.* 1982;168:24-30.
2. Robinson CM, Hill RM, Jacobs N, Dall G. Court-Brown CM. Adult distal humeral metaphyseal fractures: epidemiology and results of treatment. *J Orthop Trauma.* 2003;17(1):38-47.

3. Lill H, Korner J, Josten C. Fractures of distal humerus. In: Josten C, Lill H, editors. *Elbow Injuries, Biomechanics, Diagnostics, Therapy*. Darmstadt: Steinkopff; 2001. p. 163–82.
4. Mccarty LP, Ring D, Jupiter JB. Management of distal humerus fractures. *Am J Orthop (Belle Mead NJ)*. 2005;34(9):430–8.
5. Morrey BF, Askew LJ, Chao EY. A biomechanical study of normal functional elbow motion. *J Bone Joint Surg Am*. 1981;63(6):872–7.
6. Patel J, Motwani G, Shah H, Daveshwar R. Outcome after internal fixation of intraarticular distal humerus (AO type B & C) fractures: Preliminary results with anatomical distal humerus LCP system. *J Clin Orthop Trauma*. 2017;8(1):63–70.
7. Bista KB, Shrestha RP, Shrestha B, Kandel IS, Dakal RM. Functional outcome of the treatment of AO-ASIF type C distal humerus fracture using Lambda plate. *J Gandaki Med Coll-Nepal*. 2020;13(2):128–33.
8. Korner J, Lill H, Müller LP, Rommens PM, Schneider E, Linke B. The LCP-concept in the operative treatment of distal humerus fractures—biological, biomechanical and surgical aspects. *Injury*. 2003;34(Suppl 2):20–30.
9. Nauth A, Mckee MD, Risteovski B, Hall J, Schemitsch EH. Distal humeral fractures in adults. *J Bone Joint Surg Am*. 2011;93(7):686–700.
10. Pereles TR, Koval KJ, Gallagher M, Rosen H. Open reduction and internal fixation of the distal humerus: functional outcome in the elderly. *J Trauma Acute Care Surg*. 1997;43(4):578–84.
11. Hughes RE, Schneeberger AG, An KN, Morrey BF, and SWO. Reduction of triceps muscle force after shortening of the distal humerus: a computational model. *J Shoulder Elbow Surg*. 1997;6(5):444–8.
12. Deepak CD, Shruthikanth S. A study of functional outcome of distal humerus fractures managed by locking compression plate. *Int J Orthop*. 2018;4(4):575–8.
13. Mang I, Taufiq I, Najjad MK, Iqbal MN. Functional outcome of elbow reconstruction after using precontoured Locking Compression Plate. *J Pak Orthop Assoc*. 2014;26(1):35–8.
14. Kiran GU, Shashidhara H, Manjunath J, Akshay MK, Muralidhar A. A prospective study of functional outcome in intraraticular lower end of humerus fracture treated with dual plating. *Int J Orthop*. 2017;3(3):37–42.
15. Singh V, Uikey S, Ganvir A, Maravi DS, Gaur S. Outcome analysis of intercondylar humerus fractures treated by locking compression plates. *Int J Med Res Rev*. 2016;4(3):414–9.
16. Gofton WT, Macdermid JC, Patterson SD, Faber KJ, King GJ. Functional outcome of AO type C distal humeral fractures. *J Hand Surg*. 2003;28(2):294–308.
17. Kundel K, Braun W, Wieberneit J, Rüter A. Intraarticular distal humerus fractures: factors affecting functional outcome. *Clin Orthop Relat Res*. 1996;332:200–8.
18. Aslam N, Willett K. Functional outcome following internal fixation of intraarticular fractures of the distal humerus (AO type C). *Acta Orthop Belg*. 2004;70(2):118–22.

### Author biography

**Gagandeep Gupta**, Professor  <https://orcid.org/0000-0002-4980-1672>

**Sagar**, Junior Resident 3rd Year  <https://orcid.org/0009-0006-3373-8871>

**Sameer Khan**, Assistant Professor  <https://orcid.org/0009-0008-8202-1281>

**Cite this article:** Gupta G, Sagar, Khan S. Functional outcome of intra-articular distal humerus fractures treated with locking compression plates – A prospective study. *Indian J Orthop Surg* 2023;9(2):89-94.