

Content available at: <https://www.ipinnovative.com/open-access-journals>

Indian Journal of Orthopaedics Surgery

Journal homepage: <https://www.ijos.co.in/>

## Original Research Article

## Split transfer of tibialis anterior for equinovarus foot deformity in cerebral palsy

Manoj Kumar<sup>1,\*</sup>, Swati Sinha<sup>2</sup><sup>1</sup>Dept. of Orthopaedic Surgery, ESIC Medical College Bihta, Patna, Bihar, India<sup>2</sup>ESIC Medical College, Bihta, Patna, India

## ARTICLE INFO

## Article history:

Received 05-09-2022

Accepted 29-05-2023

Available online 04-09-2023

## Keywords:

Cerebral palsy

Equinovarus

Tendon transfer

## ABSTRACT

**Background:** Foot deformities in children with cerebral palsy are common. The various foot deformities are equinus, planovalgus, equinovarus, equinovalgus. Treatment for the flexible foot deformity should be with orthotics and manual therapy initially and then with tendon lengthening. Equinovarus deformity of the foot is a result of the muscle imbalance in which invertors of the foot, posterior and anterior tibialis muscle, overpower evertors. Untreated spastic equinovarus deformity may cause severe fixed foot deformity and painful callosities under metatarsal heads and on the lateral side of foot.

**Aims & Objective:** To evaluate the effectiveness of split transfer of tibialis anterior for equinovarus foot deformity in spastic cerebral palsy children.

40 spastic cerebral palsy (13 diplegic and 27 hemiplegic) children between the age of 5-15 years with equinovarus foot deformity were selected. The procedure adopted in all the cases was tendoachilles lengthening and split anterior tibialis tendon transfer to cuboid.

**Result:** The result was graded as good, fair and poor. In 28 of the cases varus deformity of the forefoot and midfoot got corrected with plantigrade foot, in 10 of the cases forefoot and midfoot supination was corrected but heel was in varus and in 2 of the cases there was no improvement.

**Conclusion:** Spastic T.A. is most often the cause of varus of forefoot. Split transfer utilises the spastic nature of the muscle to counter balance the deformity caused by the original muscle. Hence, it is better solution to the problem. However accurate diagnosis of deforming muscle, i.e. T.A or T.P. is essential to produce good result.

This is an Open Access (OA) journal, and articles are distributed under the terms of the [Creative Commons Attribution-NonCommercial-ShareAlike 4.0 License](https://creativecommons.org/licenses/by-nc-sa/4.0/), which allows others to remix, tweak, and build upon the work non-commercially, as long as appropriate credit is given and the new creations are licensed under the identical terms.

For reprints contact: [reprint@ipinnovative.com](mailto:reprint@ipinnovative.com)

## 1. Introduction

Cerebral palsy (CP) is a disorder of movement and posture caused by nonprogressive injury to immature brain.<sup>1</sup> The incidence is two to three per thousand live births.<sup>2</sup> Spastic CP is the most common subtype which is seen in 70% to 80% of CP patients.<sup>3</sup> In the patient with CP, there is change in muscle tone and posture which is evident both during rest and voluntary activity.<sup>4</sup> Foot deformities e.g., ankle equinus, equinovarus and equinovalgus, are common in patients with CP. Varus deformity which is

usually accompanied by equinus, is commonly caused by an abnormal posterior tibial muscle that is overactive or firing out of phase. In normal individuals posterior tibial muscle is active during stance phase to stabilize the foot and inactive during swing phase. In patients with CP the posterior tibial muscle contracts during swing phase causing varus position of the foot at heel strike. The anterior tibial muscle dysfunction may be associated. The gastrocnemius and soleus contracture usually accompanies the varus contracture and hence contributes to the varus deformity of foot. EMG studies are helpful in determining the activity of muscles.<sup>5</sup> 5 Spastic equinovarus deformity,

\* Corresponding author.

E-mail address: [manojkumar3861@gmail.com](mailto:manojkumar3861@gmail.com) (M. Kumar).

if left untreated, may cause severe fixed foot deformity and painful callosities under metatarsal heads and on the lateral side of the foot. The gait pattern becomes less effective and needs more energy.<sup>6</sup> Various methods of treatment had been advocated over the years for equino varus foot in patients with CP. The procedures practiced and recommended have been, split transfer of tibialis anterior tendon to the cuboid.<sup>7</sup> Split transfer of tibialis posterior tendon to the peroneus brevis tendon<sup>8</sup> split transfer of tibialis posterior tendon anteriorly through interosseous membraneto lateral cuneiform<sup>9</sup> rerouting of tibialis posterior tendon anterior to medial malleolus.<sup>10</sup> Tenotomy of tibialis posterior tendon.<sup>11</sup> Shortening of tibialis anterior tendon.<sup>12</sup> In this study the patients with forefoot varus and aquinus were treated by split transfer of tibialis anterior to the lateral cuneiform. Percutaneous lengthening of tendocalcaneus was performed in all patients. The outcome was analyzed. Split tendon transfer as compared to whole tendon transfer is considered more effective as it distributes equally the muscle power and eliminates the possibility of residual deformity or over correction.<sup>13</sup> Bony procedure is needed in rigid foot deformity.<sup>14</sup>

## 2. Aims and Objective

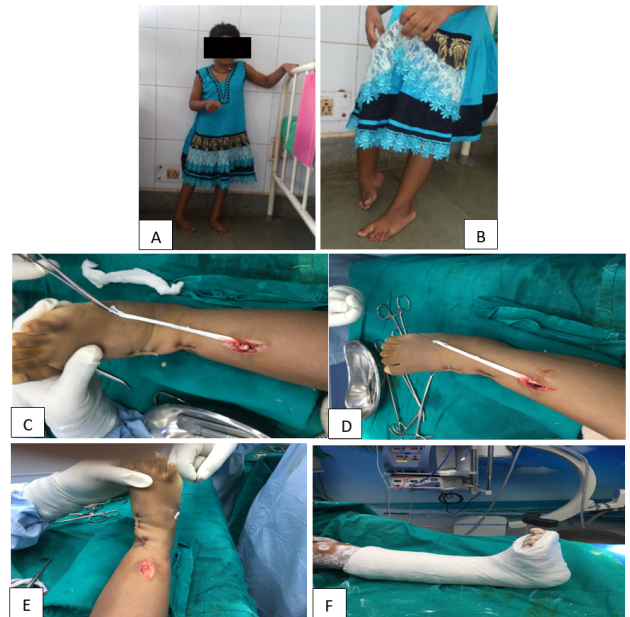
To evaluate the effectiveness of split transfer of tibialis anterior for equinovarus foot deformity in spastic cerebral palsy children.

## 3. Materials and Methods

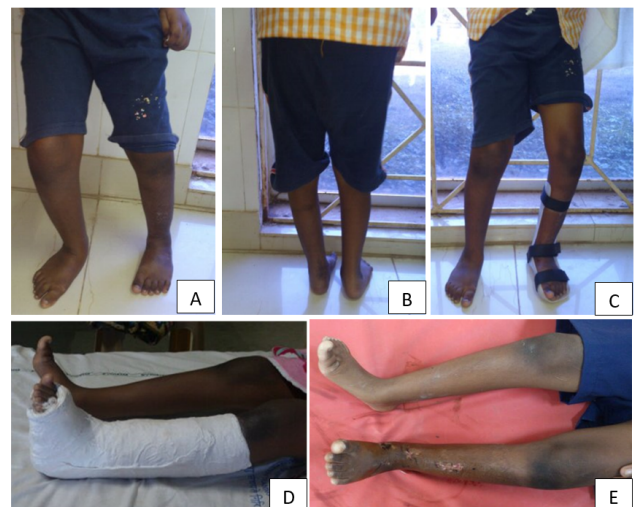A prospective non randomized study was carried out in the Department of Orthopaedic December 2014 to 2016. 40 (27 hemiplegic and 13 diplegic) spastic cerebral palsy children in the age group of 5 to 15 years with flexible varus foot deformity (predominantly forefoot and midfoot inversion) who were ambulatory or had potential for ambulation with confusion test positive were included in the study. The foot which showed overactivity of tibialis posterior were excluded from the study.

### 3.1. Procedure

Tendoachilles lengthening was done in all cases. Steindler's procedure was done if cavus was present. Split tibialis anterior tendon transfer to lateral cuneiform was done: (Hoffer et al 1974).<sup>7</sup> Post-operatively below knee cast was given for 6 weeks. Then ankle foot orthosis(AFO) was prescribed for 6 months along with tendon re-education program. Pre-treatment gross motor functional classification system (GMFCS) levels were compared to the patients' latest evaluations. Factors associated with outcomes and success rate were assessed.



**Fig. 1: Case 1-** A,B,C): The surgical procedure; D): Adequate length of the split tendon was achieved; E): The split tendon was passed subcutaneously into the incision made over the lateral cuneiform and was then inserted into the hole made in the bone under moderate tension; F): Post-operatively pop B.K. cast was given for 6 weeks



**Fig. 2: Case 2-** Post- op

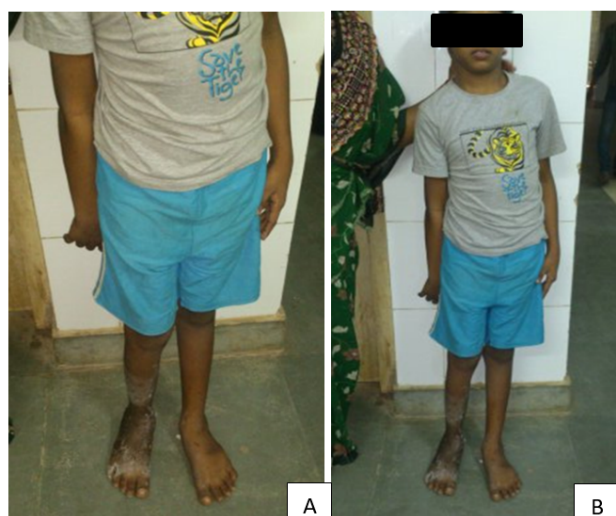

Fig. 3: Case 3- After the removal of below knee cast

### 3.2. Statistics

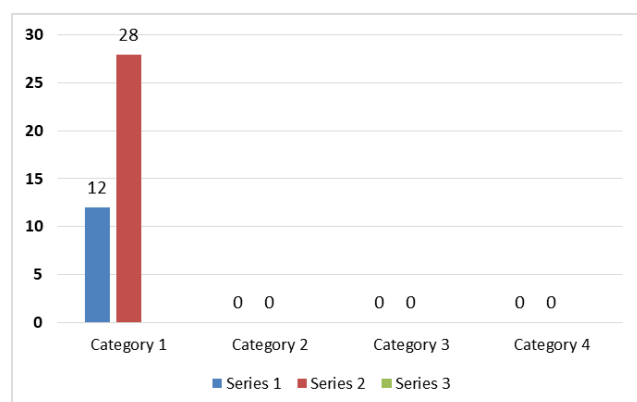
Hoffer's criteria

#### 1. Graded as

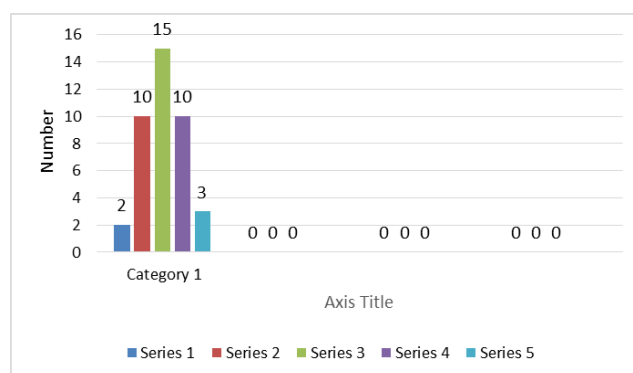
- (a) Very Good – 75%
- (b) Satisfactory – 25%
- (c) Poor – 5%

Table 1:

Cases	Outcome
28	No deformity post-operatively, total foot contact on the ground and proper shoe wearing
10	Mild varus, valgus or equinus deformity (Less than 50), Small foot contact and overnight braces were used
2	Over correction, under correction or equinus > 5 degrees and braces were used



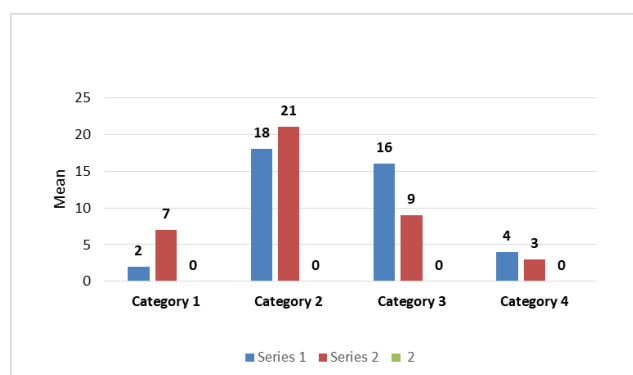
Graph 1: No of cases of unilateral foot



Graph 2: Age wise distribution

Table 2: According to GMFCS

GMFCS	Initial no. of children in different GMFCS level	Improvement in GMFCS level of CP children at follow up after 1.5yrs
I	3	5
II	21	23
III	12	9
IV	4	3
V	0	0



Graph 3: Mean value in improvement in GMFCS level of CP children

There is no significant difference between initial and follow-up data as witnessed by Wilcoxon's Signed Rank Test ( $p > 0.05$ ). But looking at the individual performances, some advantage of the treatment can be noticed.

### 4. Result

Forty patients (40 unilateral feet) were included in the study. Thirty two patients were male and eight patients were female. The age range at start of study was between five and fifteen years (mean age 10 years). Mean follow-up was 1.5 years (Range 1-2 years). 28 patients were hemiplegic and 12 patients were diplegic. The range of varus deformity was  $15^\circ$  to  $20^\circ$  and range of equinus was between  $16^\circ$  to  $25^\circ$ .

**Table 3:**

Sex	Number	Percentage%
Male	32	80
Female	8	20
Total	40	100

The result of the study was carried out using the clinical criteria of Hoffer. The feet were graded as very good in 75%, satisfactory in 25% and poor in 5% of cases. In the follow up period of one year, in 28 feet there was no deformity post-operatively, total foot contact on the ground and proper shoe wearing was present, in 10 feet there was mild varus or equinus deformity (less than 5°) and patient was prescribed ankle foot orthosis for overnight use, in 2 feet there was under correction of equinus (>5°) and orthosis was prescribed for daytime use. Percutaneous tendocalcaneus lengthening was done in all cases. Patients with excellent and very good results showed improvement in gait and were able to walk with plantigrade feet. They were wearing regular shoes and do not need brace. The patients with good results were advised to wear night splint. The patients with poor results needed brace during walking and at night as well. Pre-treatment gross motor functional classification system (GMFCS) levels were compared to the patients' latest evaluations. Factors associated with outcomes and success rate were assessed. As per Table 2, GMFCS Level improvement seen in 40 patients in Level I to V.

## 5. Discussion

Spastic tibialis anterior is most often the cause of varus–inversion deformity of forefoot and midfoot. When the tibialis anterior muscle is over-active or tight, it tends to pull the foot in. The muscles which balance this movement on the outside of the foot are often weak and unable to keep the foot in a normal position. Split transfer utilizes the spastic nature of the muscle to counter balance the deformity caused by the original muscle. This surgery balances the pull of the muscle so that the foot lifts straight up instead of pulling in. Hence, it is a better solution to the problem. However accurate diagnosis of deforming muscle, i.e. tibialis anterior or tibialis posterior is essential to produce good result. Percutaneous tendo calcaneus lengthening was done in all cases. Percutaneous tendo calcaneus lengthening has shorter operating time, lower complication rate and gives better active dorsal and plantar flexion abilities.<sup>15</sup> Lengthening of the tendon weakens the muscle. With additional lengthening of tendo calcaneus the planter flexion strength is reduced.

Equino varus deformity of foot in patients with cerebral palsy has been treated by various methods. Baker and Hill (1964)<sup>10</sup> advocated rerouting of the tibialis posterior tendon anterior to the medial malleolus with satisfactory results, but

Bisla et al (1976)<sup>16</sup> failed to achieve the adequate correction of deformity in their patients. Banks and Panagakos (1967)<sup>17</sup> described lengthening of tibialis posterior in these cases. On long term follow up many authors reported high incidence of recurrence after lengthening of tibialis posterior (Ruda and Frost 1971)<sup>14</sup> (Root et al 1987).<sup>18</sup> Lengthening of the tendon weakens the muscle. With additional lengthening of tendo calcaneus the planter flexion strength is reduced. Tenotomy of tibialis posterior tendon at the site of its insertion resulted in many cases into collapse of talonavicular joint. (Green et al 1983)<sup>11</sup> (Root et al 1987)<sup>18</sup> Kaufer H (1977)<sup>19</sup> and Kling TF et al (1985)<sup>8</sup> reported their results of split transfer of tibialis posterior tendon to the peroneus brevis passing posterior to the tibia. The results were satisfactory but their study included patients who developed spasticity after encephalitis and head injuries. Grzegorzewski A et al (2007)<sup>6</sup> reported 89% good clinical and functional results after 4.6 years of follow up after split tibialis posterior transfer to peroneus brevis tendon. M.J. Saji et al (1993),<sup>9</sup> reported their results of surgical procedure for spastic equinovarus deformity of foot in patients with cerebral palsy. They transfer the anterior half of the split tibialis posterior to the dorsum of the foot through the interosseous membrane on 23 feet in 18 children. In their 8.4 years of follow up, using the criteria of Kling et al. (1985)<sup>8</sup> excellent results were obtained in 14 feet, good in eight, and poor result in only one.

The result of the study was carried out using the clinical criteria of Hoffer. The feet were graded as very good in 75%, satisfactory in 25% and poor in 5% of cases. In the follow up period of one year, in 28 feet there was no deformity post-operatively, total foot contact on the ground and proper shoe wearing was present, in 10 feet there was mild varus or equinus deformity (less than 5°) and patient was prescribed ankle foot orthosis for overnight use, in 2 feet there was under correction of equinus (>5°) and orthosis was prescribed for daytime use. Percutaneous tendocalcaneus lengthening was done in all cases. Pre-treatment gross motor functional classification system (GMFCS) levels were compared to the patients' latest evaluations. Factors associated with outcomes and success rate were assessed. Patients with excellent and very good results showed improvement in gait and were able to walk with plantigrade feet.

## 6. Conclusion

Spastic T.A. is most often the cause of varus of forefoot. Split transfer utilises the spastic nature of the muscle to counter balance the deformity caused by the original muscle. Hence, it is better solution to the problem. However accurate diagnosis of deforming muscle, i.e. T.A or T.P. is essential to produce good result.

Timely surgical intervention with an individualized approach in the treatment of foot deformity has a definitive

role in the rehabilitation of cerebral palsy children. Long term follow-up is needed to see the actual effect of the surgery.

However accurate diagnosis of deforming muscle prior to surgery is essential to achieve the optimum results. The dynamic electromyography and gait analysis should be performed before surgery.

## 7. Source of Funding

None.

## 8. Conflict of Interest

None.

## References

1. Molnar GE. Long-term treatment of spasticity in children with cerebral palsy. *Int Disabil Stud.* 1987;9(4):170–2.
2. Kiely M, Lubin RA, Kiely JL. Descriptive epidemiology of cerebral palsy. *Public Health Rev.* 1984;12(1):79–101.
3. Gupta A, Srivastava A, Taly AB, Murali T. Single-stage multilevel soft-tissue surgery in the lower limbs with spastic cerebral palsy: Experience from a rehabilitation unit. *Indian J Orthop.* 2008;42(4):448–53.
4. Naeye RL, Peters EC, Bartholomew M, Landis JR. Origins of cerebral palsy. *Am J Dis Child.* 1989;143(10):1154–61.
5. Sawyer JR. Cerebral Palsy. In: Canale S, Beaty JH, editors. *Campbell's Operative Orthopaedics.* vol. 30. Pennsylvania: Mosby; 2007. p. 1366–80.
6. Grzegorzewski A, Borowski A, Pruszczyński B, Wranicz A, Domzalski M, Synder M. Split tibialis posterior tendon transfer on peroneus brevis for equinovarus foot in CP children. *Chir Narzadow Ruchu Ortop Pol.* 2007;72(2):117–20.
7. Hoffer MM, Reiswig JA, Garrett AM, Perry J. The split anterior tibial tendon transfer in the treatment of spastic varus hind foot of childhood. *Orthop Clin North Am.* 1974;5(1):31–8.
8. Kling TF, Kaufer H, Hensinger RN. Split posterior tibial-tendon transfers in children with cerebral spastic paralysis and equinovarus deformity. *J Bone Joint Surg Am.* 1985;67(2):67–94.
9. Saji MJ, Upadhyay SS, Hsu LC, Leong JC. Split tibialis posterior transfer for equinovarus deformity in cerebral palsy. Long-term results of a new surgical procedure. *J Bone Joint Surg.* 1993;75(3):498–501.
10. Baker LD, Hill LM. Foot alignment in the cerebral palsy patient. *J Bone Joint Surg Am.* 1964;46:1–15.
11. Green NE, Griffin PP, Shiavi R. Split posterior tibial tendon in spastic cerebral palsy. *J Bone Joint Surg Am.* 1983;65(6):748–54.
12. Rutz E, Baker R, Tirosh O, Romkes J, Haase C, Brunner R. Tibialis anterior tendon shortening in combination with Achilles tendon lengthening in spastic equinus in cerebral palsy. *Gait Posture.* 2011;33(2):152–7.
13. Vlachou M, Dimitriadis D. Split tendon transfers for the correction of spastic varus foot deformity: a case series study. *J Foot Ankle Res.* 2010;3:28. doi:10.1186/1757-1146-3-28.
14. Trehan SK, Ihekweazu UN, Root L. Long-term outcomes of triple arthrodesis in cerebral palsy patients. *J Pediatr Orthop.* 2015;35(7):751–5.
15. Jaddue DA, Abbas MA, Sayed-Noor AS. Open versus percutaneous tendo-Achilles lengthening in spastic cerebral palsy with equines deformity of the foot in children. *J Surg Orthop Adv.* 2010;19(4):196–9.
16. Bisla RS, Louis HJ, Albano P. Transfer of tibialis posterior tendon in cerebral palsy. *J Bone Joint Surg Am.* 1976;58(4):497–500.
17. Banks HH, Panagakos P. The role of the orthopedic surgeon in cerebral palsy. *Pediatr Clin North Am.* 1967;14(2):495–515.
18. Root L, Miller SR, Kirz P. Posterior tibial-tendon transfer in patients with cerebral palsy. *J Bone Joint Surg Am.* 1987;69(8):1133–9.
19. Kaufer H. Split tendon transfers. *Orthop Trans.* 1977;1:191.

## Author biography

Manoj Kumar, -  <https://orcid.org/0000-0001-5279-2212>

Swati Sinha, -

**Cite this article:** Kumar M, Sinha S. Split transfer of tibialis anterior for equinovarus foot deformity in cerebral palsy. *Indian J Orthop Surg* 2023;9(3):147-151.