

## A study on functional outcome of ilizarov fixation in the management of infected non-union of long bones

Perepa Ravi Sasanka Sreeram

Senior Resident, Dept. of Orthopaedics, Kasturi Medical College & Hospital, Guntur

Email: prssriram@gmail.com

### Abstract

**Introduction:** Nonunion of long bones especially tibia when associated with infection has always been a challenge to orthopaedic surgeons. This study is conducted to report the results of the use of this technique for treatment of infected nonunion of long bones and the study of complications encountered during treatment.

**Material & Methods:** An observational study was done on case records of 20 patients admitted and treated in Kasturi Medical College with Ilizarov fixator for infected nonunion of long bones between August 2012 to September 2014 were taken for demographic information, details of treatment, radiological features and number of complications.

**Results:** The mean age of the patients was 39.3 years with majority (65%) in the age group of 30-50 years. Out of the 20 patients, 17 were males and 3 were females. Out of the 20 cases treated with the Ilizarov fixator 19 cases sound union occurred without the need for any other intervention and complete resolution of infection was seen. Five patients had a limb length discrepancy of more than 2.5 cm. 70% had excellent bony results and 50% had excellent functional results.

**Keywords:** Infected non-union, Ilizarov fixation, Functional outcome

Access this article online	
Quick Response Code:	Website: www.innovativepublication.com
	DOI: 10.5958/2395-1362.2016.00038.4

### Introduction

Nonunion of long bones especially tibia when associated with infection has always been a challenge to orthopaedic surgeons. Bony union is not usually obtained until the infection has been eradicated and there are usually coexisting problems of deformity, loss of bone, leg length discrepancy and soft tissue damage<sup>[1]</sup>. The limb length discrepancy may be treated with extensive operative exposure and technically demanding procedures that do not allow early mobilization and weight bearing.

Thus it may be associated with osteoporosis, soft tissue atrophy and persistent infection in the presence of implants. Open cancellous bone grafts have been successfully used to fill tibial defects some of the best results have been achieved with vascularized free tissue transfers. Most patients managed with these methods have multiple operations and a long period of immobilization before consolidation of the grafts<sup>[2]</sup>.

Non-invasive methods are not recommended when osteomyelitis or a bone defect is present. Despite the excellent results that are often obtained, some patients undergo an arduous, unproductive course of treatment in which the level of disability related to long bone fracture nonunion can counterbalance the benefits of limb salvage procedure.

In the 1950s Professor G.A. Ilizarov developed his osteosynthesis techniques and treatment combining mechanical and biological factors. Ilizarov technique is based on tension- stress effect and distraction histogenesis when a living tissue is distracted in controlled way it produces new tissue of same kind known as regenerate. Ilizarov technique uses external fixation principles providing multiplanar stability<sup>[3]</sup>.

Patients with complex non unions of long bones are commonly operated upon several times for stabilization or to reduce the infection, which in turn produces scarring of the soft tissues and devitalization of any surviving bone. They present with infection, which is mostly associated with deformity, limb length discrepancy and joint stiffness. External fixation is able to address these problems simultaneously.

When applied to nonunion, the Ilizarov principles consist of removal of nonviable or infected tissue, removal of all foreign bodies or hardware, application of a constructed small-wire fixation frame and union through distraction osteogenesis, deangulation and compression.

The most important principle and distinct advantage of ilizarov method is the active use of limb to restore physiologic function<sup>[3]</sup>. Reconstruction of complex nonunions may take as long as 6 months and during this time the fixation supports the extremity and simultaneously allows the patient to work and be active.

Pin tract infection, joint stiffness especially ankle, osteomyelitis, neurovascular injury are a few complications associated with ilizarov technique. As experience grows, these complications can be reduced to minimum. Good patient compliance is a must as duration of fixator is for a long period and multiple procedures are undertaken<sup>[4]</sup>.

This study is conducted to report the results of the use of this technique for treatment of infected nonunion of long bones and the study of complications encountered during treatment at our institution.

### Material & Methods

An observational study was done on case records of 20 patients admitted and treated in Katuri Medical College with Ilizarov fixator for infected nonunion of long bones between August 2012 to September 2014 were taken for demographic information, details of treatment, radiological features and number of complications.

**Inclusion criteria:** All patients admitted to department of Orthopaedics, Katuri Medical College and hospital, with infected non-union of long bones treated with Ilizarov fixator were included in this study.

**Exclusion criteria:** All pathological fractures and patients treated with other uniplanar external fixators were excluded from the study.

Non unions of this study were classified as per Dror Paley classification. Complications were classified according to Dror Paley criteria as problems, obstacles and true complications. Bony and functional outcome were assessed using the Association for the Study and Application of Methods of Ilizarov (ASAMI) criteria.

### Methods

The patient admitted with fracture of long bone with infected non-union were thoroughly examined and questioned. When it was decided for treating the patient with Ilizarov apparatus, he was shown the fixator and informed in detail as to what procedures that are going to be performed on him.

He/she was explained how the pins were passed through his limbs and the various surgical procedures like excising the infected non-union, performing a corticotomy, osteotomising the fibula, etc. The requirements of other subsequent minor/ major procedures were explained to them such as change of pins, etc. Finally the most important aspect of this method of treating non-union of long bones i.e. the approximate period of treatment was explained to him/ her. This period of treatment was informed to all patients as one centimetre of bone gap requires minimum 1 month of Ilizarov fixator on him/ her. All the history and clinical findings were documented in the proforma made for this purpose.

Pre-operative X-rays, investigations, etc., were done and documented. Pre-operative planning according to the site of infected non-union and pre-planning the site of corticotomy if needed were done as per standard procedure.

### Procedure

After explaining thoroughly about the procedure and the approximate period of treatment, consent for the procedure is taken from patient and the attendants.

All the history and preoperative radiographs and investigations are documented.

**Surgical procedure:** under suitable anaesthesia (spinal, epidural anaesthesia). We operated on traction table limb is held in ideal position. The pre-assembled ring construct is placed over the limb in such a way that the limb is exactly in the middle of ring in its whole length.

The construct is assembled with 2 rings above and 2 rings below the non-union site sometimes 3 rings were used. The proximal most and distal most rings are fixed to the limb by means of Ilizarov wire placed parallel to the joint known as "Reference" wires.

For femur proximal assembly is by means of antero-laterally placed shanz pin fixed to an Italian arch. Rest of wires were inserted through safe corridors taking care of neurovascular structures and transfixing as little soft tissue as possible the muscles were stretched to full extent before transfixing them. Wire was pushed through soft tissue without spinning motion to avoid neurovascular injury. Heating was prevented by continuously cooling the wire with betadine and saline.

Alignment of non-union site was confirmed with image intensifiers minor adjustments of angulation were corrected by compression on one side with distraction on other side. Corticotomy when required is performed with a 5 cm longitudinal incision. Periosteum was elevated, small holes drilled and Corticotomy done with a thin osteotome in a gentle manner preserving both endosteal and Periosteal blood supply.

Latency period of 4 to 15 days was used rate of distraction was fixed at 1mm/day or sometimes altered depending on follow up x-rays. Follow up were done at monthly intervals. Frame removal done when the union was sound clinically and radiological lying confirmed. Fixator was dynamized before removal towards the end of the treatment. After removal patients were given functional brace for 6 weeks.

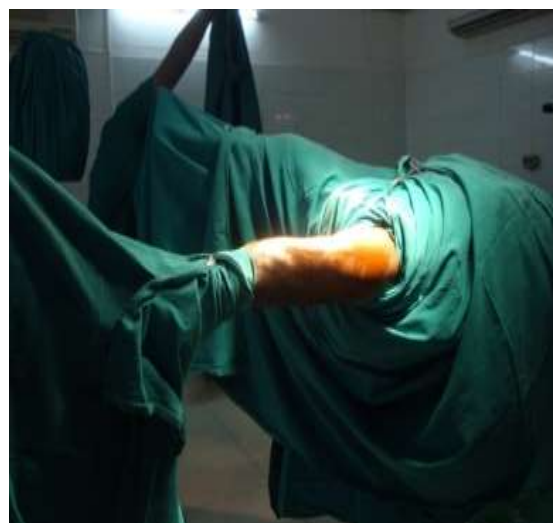
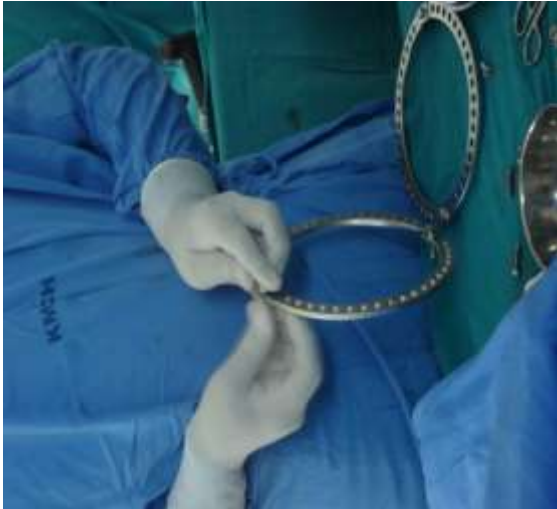
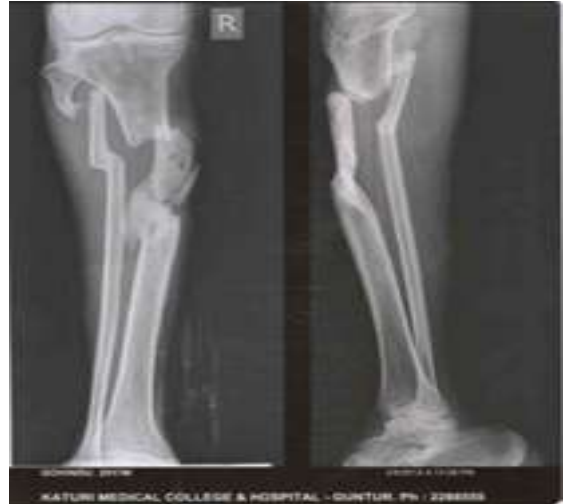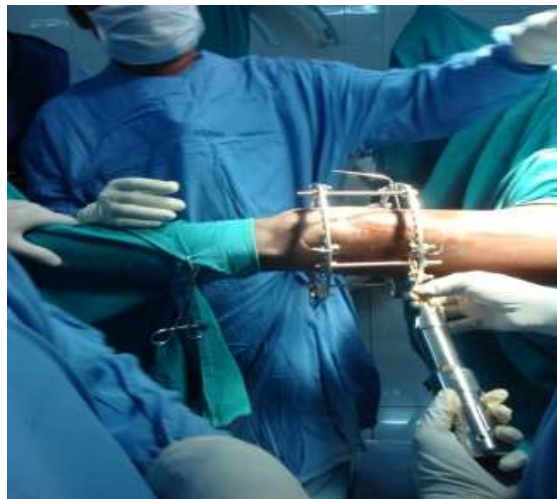Fig.: Positioned in traction table



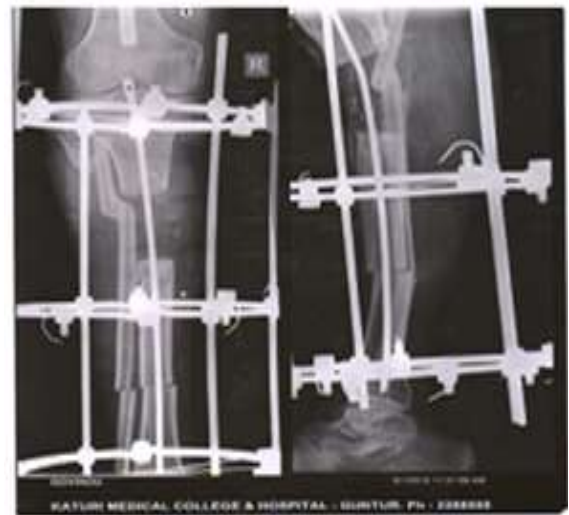**Fig.:** Assemblage of the ring and draped



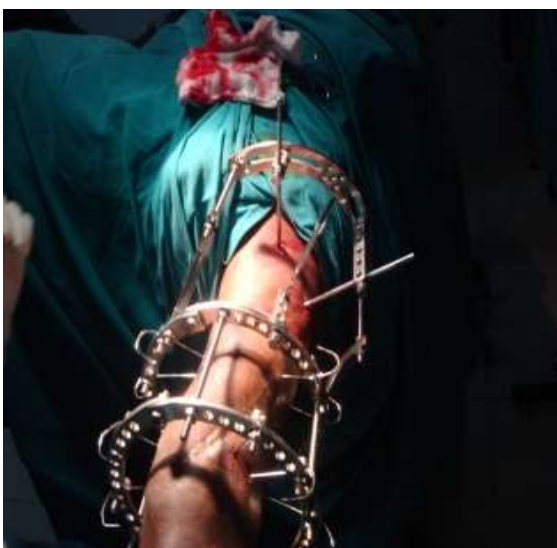
**Fig. 1:** Infected non-union tibia with 6 cm sequestrum



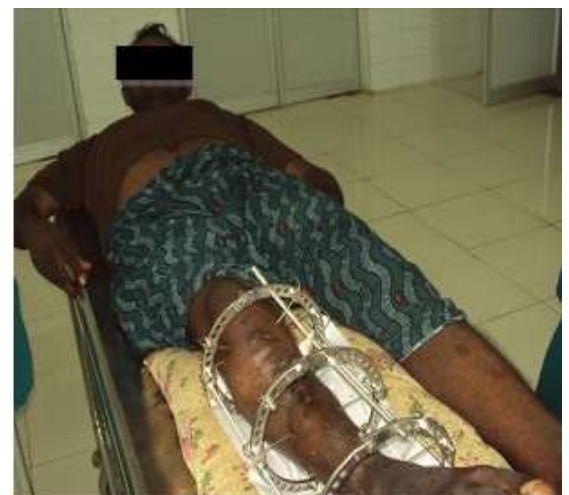**Fig.:** Tensioning the wire



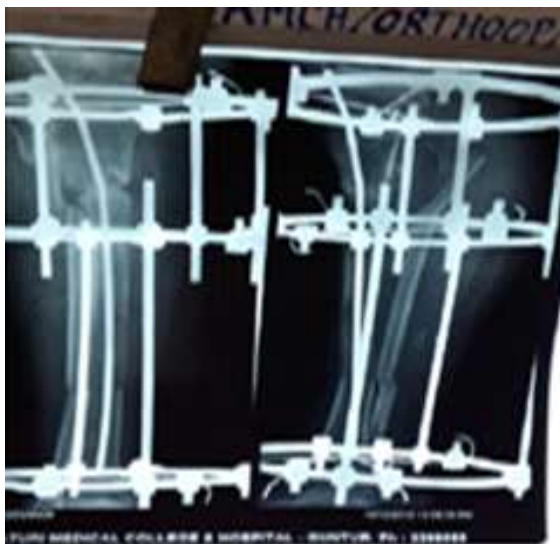
**Fig. 2:** Post-operative radiograph after sequestrectomy and distal corticotomy with ilizarov fixator



**Fig.:** Fixator applied to femur



**Fig. 3:** Postoperative clinical photograph



**Fig. 4: Two months post-operative radiograph with internal bone transport**



**Fig. 5: Functional outcome at 10 months post OP**

## Results

The mean age of the patients was 39.3 years with majority (65%) in the age group of 30-50 years. Out of the 20 patients, 17 were males and 3 were females.

In 16 patients tibia is involved and in 4 patients femur is involved with infected non union. Majority of patients had grade 3B compound fracture<sup>(12)</sup>, closed fracture in 5, grade 1 fracture in 1, grade 2 fracture in 1, grade 3A in 1 as per Gustillo-Andersen classification<sup>[5]</sup>.

Duration of nonunion ranged from 4 months to 10 years (with a mean of 7.3 months). Most of the patients had previous attempts at union with a mean of 1.53 procedures per patient (1 to 3). 3 patients had 3 procedures, 11 patients had 2 procedures and the remaining patients had one procedure. Previous attempts ranged from external fixator application (60%)

flap coverage, bone grafting, plates & screws (15%, intramedullary devices (25%).

Monofocal osteosynthesis was done in 16 cases. Bi focal osteosynthesis was done in the 3 cases and trifocal osteosynthesis was done in one case with corticotomy at two sites. One case required sequestrectomy at later follow up. Out of the 20 cases, 4 cases were of femur and 16 cases were of tibia. Acute docking of non union was done in 3 cases.

Of the 20 cases 6 cases required bone grafting. Fixator readjustment had to be done 5 times and wire tensioning in 2 cases. 20 cases were treated using the Ilizarov ring fixator and all cases had followed up to minimum of three months. Average months in the fixator were 8 months. Additional protection ranging from protected weight bearing with crutches to cast application with POP was used. Average time to union was 7 months. Total duration of treatment ranged from 6 to 22 months (average of 10 months). All the cases were followed up for a minimum of 12 weeks after the removal of the brace or cast. Follow up ranged from 12 weeks to 18 months with an average of 42 months.

Few patients required surgical intervention while in the fixator ranging from fixator readjustment, wire tensioning and removal of the wire. A total of 26 surgeries were done at an average of 1.03 surgeries per patient.

## Union

Out of the 20 cases treated with the Ilizarov fixator 19 cases sound union occurred without the need for any other intervention. 3 cases required additional protection with an alkaathene brace for more than 6 weeks. One tibial nonunion, which did not show union, due to extensive soft tissue damage finally went on to below knee amputation.

Out of the three cases which needed additional protection for more than six weeks one had a refracture which was treated conservatively by cast bracing for 2½ months. In 6 cases bone grafting was done to augment the union as an additional procedure.

## Infection

Out of the 20 patients with radiological and clinical signs of infection, complete resolution of infection was seen in 19 patients. Two patients required treatment in the form of sequestrectomy out of which one patient had a broken wire within the medullary cavity. Infection was controlled after removal of the broken wire. One patient had cellulitis for which he was treated with antibiotics.

## Limb length discrepancy

Out of the 20 cases, 5 patients had a limb length discrepancy of more than 2.5 cm. The shortening with bone loss ranged from 1.2cm to 6.5 cm. At the end of the procedure two patients still had a limb length

discrepancy of more than 2.5 cm, which was treated by heel rise. Two were on the femur.

### Angulation

Angulation correction was done in 2 cases, with differential distraction. One on the femur and the other on tibia and the correction was achieved in both the cases with axial deformity less than 7 degrees.

Bony and functional results were graded according to ASAMI criteria.

### Bony results in present study

Excellent bony results were observed in 70% of the patients. Good bony results in 20%, 5% had fair and only 5% had poor bony results. (Table 1)

**Table 1: Bone Results of Present Study**

Results	No. of patients	Percentage
Excellent	14	70%
Good	4	20%
Fair	1	5%
Poor	1	5%

### Functional results in present study

In the present study, excellent functional results were seen in 50%, good functional results in 40% and only 1 case had poor functional result. (Table 2)

Difficulties encountered during the course of treatment were divided into problems, obstacles and complications. There were 25 problems, 10 obstacles and 11 complications.

**Table 2: Functional Results in present study**

Results	No. of patients	Percentage
Excellent	10	50%
Good	8	40%
Fair	1	5%
Poor	1	5%

### Problems

Out of the 25 problems pin track infections (Grade I & GRADE II) were seen in 10 patients that responded to a course of antibiotics. Two cases needed angulation correction with the adjustment of the frame. Joint stiffness which was resolved by physiotherapy and regular stretching was seen in 11 cases. Delayed consolidations is seen in 2 patients and were treated by resorting to accordion maneuver.

### Obstacles

4 cases needed wire tensioning which had to be done in the theatre. The fixator realignment had to be done in 3 cases in the form of addition of a new ring (1 case), and addition of a new wire (2 cases). (Table 3) Pin tract infection warranted removal of the offending wire in 3 cases and reapplication of new wires at a different site.

**Table 3: Problems Obstacles and Complications**

Problems	Obstacles	Complications
Pin tract infection -10	Wire tensioning -4	Joint stiffness-6
Angulation - 2	Fixator realignment - 3	Limb length discrepancy >2.5cm -2
Joint stiffness- 11	Pin tract infection-3	Persistent infection -1
Delayed consolidation-2		Neurological deficits -1
		Refracture -1

### Complications

Out of 20 patients 11 showed loss of ankle dorsiflexion of more than 15 degree after the frame removal. After physiotherapy, 5 gained useful range of movement. One patient had fixed equinus deformity, one patient complained of the knee stiffness and none of the patients had loss of extension more than 15 degrees. (Table 3)

Persistent infection after the removal of the fixator was seen in 1 case. Infection could be controlled with sequestrectomy.

Limb length discrepancy of more than 2.5cm persisted in two cases. One case developed common peroneal nerve palsy

### Refracture

Only one case developed a refracture at the docking site 8 weeks after the frame removal. The patient was conservatively treated with a cast brace and the fracture united in a period of two and half months. (Table 3)

### Discussion

In developing country like India, majority of the working population is served by public transport. The long distances travelled to work place compounded by critical transport demands, increases the risk of road traffic accidents. These patients are often young, active, and bread earners of their families.

In the present study most patients had multiple other definitive procedures before they referred for ring fixation. Present study demonstrated that good function can be achieved by ilizarov method in terms of activity, control of infection, pain relief.

In present study 20 cases treated by this technique were reviewed. Majority of the patients are in 30-50 age group (13). Average at presentation was 39.5 years which is similar to the studies of Yin P et al<sup>[6]</sup>, and Madhusudan et al<sup>[7]</sup>. Present study comprises of 16 males and 4 females. All patients had clinical and radiological features of infection. The mixed organism growth from bacterial cultures of nosocomial origin

requires repeated hospitalizations and expensive antibiotics for infection control.

None of the patients had Ilizarov as primary modality of treatment. With 2-3 previous surgical interventions with average of 1.53 interventions compared to study by Patel et al<sup>[8]</sup> showing 2 interventions.

Four cases had bone gap which varied from 2.5 cm to 11 cm average of 4.2 cm compared to study of cattaneo et al<sup>[13]</sup> which reported 6cm, green et al which reported 5.14 cm.

Corticotomy was done in 4 cases. In one case internal bone transport was done and for three cases external bone transport was done. Distraction in our study was done at a rate of 1mm/day at a rhythm of 0.25 mm every 6th hourly as done in the study by Dr Mukesh N Shah & Dr Josal S Patel<sup>[9]</sup> and the corticotomy was performed at the junction of metaphysis and diaphysis, all the corticotomies were performed in tibia, one patient with 11 cm bone defect corticotomy is done at two levels.

Latency period is the time period between corticotomy and beginning of distraction in our study Latency period is 1 week to 10 days which is similar to study by Banikanta Sharma & Sanjib Waikhom<sup>[10]</sup>. In two cases the regenerate was not visible; an accordion manoeuvre was resorted to and distraction rate was reduced until satisfactory regenerate was visible

Present study confirms Ilizarov's assertion<sup>[3]</sup> that distraction alone is a potent stimulus, for Type A2-1, A2-2 (hypertrophic) type of nonunions as 6 cases were treated by pure distraction. Serial radiographs are analysed at each follow up to look for consolidating regenerate. The fracture was considered united when it appeared radiologically or when there is no motion at the fracture site after loosening of connecting rods and when patient was able to walk without pain at the fracture site

Grade 1 inflammation was treated with wire tensioning, grade 2 pintract infections were treated with regular dressings and local injection of antibiotic as advised by Dror paley et al<sup>[11]</sup>. The pintract infection was low in this study compared to other studies due to meticulous pin tract care, and adequate tensioning, and adherence to principles like tapping through soft tissue and drilling through the bone.

In the present study none of the cases developed joint subluxation. Due to lack of preexisting instability, and prevention of severe muscle contractures by adequate physiotherapy, many of the studies also did not report significant rates of joint subluxation.

There were no vascular injuries and one patient developed common peroneal nerve palsy. The rate of neurovascular complications is comparable to study by Wani NB & Syed B<sup>[12]</sup>.

Two patients developed limb length discrepancy >2.5 cm (10%) and achieved good functional result by

shoe rise. None of the patients developed regional sympathetic dystrophy, 6 patients had joint stiffness predominantly involving ankle which is similar to the studies of sanders et al<sup>[13]</sup>.

Previous papers looking at the use of ilizarov technique have shown results using ASAMI criteria are comparable to present study. Many of the other papers have incorporated non-unions without any evidence of infection. These are expected to have better outcome as the patient would not require such radical debridement and treatment of osteomyelitis.

However the results of present study are comparable to those studies. The reasons could be due to meticulous sampling of tissues and thorough debridement of infected tissues. One patient with ipsilateral femur fracture which was also infected along with tibia required prolonged period (8 months) to return to work after removal of fixator in the tibia, one with persistence of pain and infection could not return to work, one patient with refracture after fixator removal required 6 months after fixator removal for return to work.

Average duration in our study was 8 months with 6 months for tibial nonunion and 10 months for femoral nonunion and 11 months for cases with bone defects, which is comparable to other studies. In Dror paley et al<sup>[11]</sup> study, time to union was 8 months and duration of treatment was 10 months and in Madhusudhan et al<sup>[7]</sup> study, time to union was 8.5 months and duration of treatment was 11 months.

The bony and functional results were assessed by ASAMI criteria. 70% of patients showed excellent bony results, 20% of patients had limb length discrepancy of more than 2.5 cm, 5% of patients union is not achieved, and 5% of patients had persistent infection. Similar findings were seen in Dror Paley et al<sup>[11]</sup> where excellent bony results were seen in 60.87%.

6(30%) patients had joint stiffness 2(10%) involving knee joint, 4(20%) had stiffness involving the ankle, 2(10%) had limp 1(5%) patient had persistent pain and inactivity is present in one(5%) functional results of the present study are comparable to those of many other studies due to meticulous attention to surgical details and motivating the patient regarding physiotherapy and pintract care.

Observations in present study indicate that Ilizarov is an excellent treatment method, in situations with no good alternatives, such as osteomyelitis, osteopenia, complex deformities and significant limb-length inequalities. This Ilizarov external fixator system is ideal for limb salvaging in the infected non-union of long bones.

## Conclusions

Management of infected non-union of long bones with Ilizarov fixation aims at limb salvage. It requires meticulous attention to surgery and post-operative care along with good patient counseling on the part of

surgeon. It also requires great deal of cooperation for long duration of time on the part of patient.

### Limitations of study

Lack of a control group or a comparison treatment group that does not allow the development of true evidence based guidelines for the optimal treatment of this group of patients.

### References

1. Cleveland KB. Campbell's operative orthopaedics (11th ed). Philadelphia: Mosby-Elsevier; 2008.
2. Seenappa HK, Shukla MK, Narasimhaiah M. Management of complex long bone nonunions using limb reconstruction system. *Indian J Orthop*. 2013 Nov;47(6):602-7.
3. Ilizarov GA. The tension stress effect on the genesis and growth of tissue: part I & II. The influence of stability of fixation and soft tissue preservation. *Clin orthop*. 1989;239:263-285.
4. Ilizarov GA. Transosseous osteosynthesis. Heidelberg: Springer verlag; 1992.
5. Kim PH, Leopold SS. Gustilo-Anderson Classification. *Clinical Orthopaedics and Related Research*. 2012;470(11):3270-3274. doi:10.1007/s11999-012-2376-6.
6. Yin P, Zhang L, Li T, Zhang L, Wang G, Li J, et al. Infected nonunion of tibia and femur treated by bone transport. *J Orthop Surg Res*. 2015;10:49.
7. Madhusudhan TR, Ramesh B, Manjunath K, Shah HM, Sundaresh DC, Krishnappa N. Outcomes of Ilizarov ring fixation in recalcitrant infected tibial non-unions—a prospective study. *Journal of trauma management & outcomes*. 2008;2(1):6.
8. VR Patel, DK Menon, RD Pool, RB Simonis. Nonunion of the humerus after failure of surgical treatment. Management using the ilizarov circular fixator. *Journal of Bone & Joint Surgery, British*; Volume 82(7),977-983.
9. Dr Mukesh N Shah & Dr Josal S Patel. Treatment of Infected Non Union of Lower Limb Long Bones with Limb Reconstruction System (Lrs). *Indian J of Applied Research* 2016;6(2):699-702.
10. Banikanta Sharma & Sanjib Waikhom. "Ilizarov treatment of non union tibia with bone loss". *Journal of Evolution of Medical and Dental Sciences* 2013;2(38):7261-7271.
11. Paley D, Chaludray M, Pirone M et al. Treatment of malunion and mal-non-unions of the femur and tibia by detailed pre-operative planning and Ilizarov techniques. *Clin. North Am* 1990;21:667-691.
12. Wani NB & Syed B. Ilizarov ring fixator in the management of infected non-unions of tibia. *SICOT J*,2015;1(22):1-6.
13. Sanders DW, Galpin RD, Hosseini M, MacLeod MD. Morbidity resulting from the treatment of tibial nonunion with the Ilizarov frame. *Canadian Journal of Surgery*. 2002;45(3):196-200.