



## Case Report

# Giant cell tumour of proximal radius – A rare case report of treatment, with resection & custom- made radial head prosthesis

Subhash M Mohite<sup>1</sup>, Shreyas Kanakpur<sup>1\*</sup>, Harish Kanakpur<sup>1</sup>

<sup>1</sup>Kshema Orthopaedic and Trauma Centre, Hubli, Karnataka, India



### ARTICLE INFO

#### Article history:

Received 07-01-2023

Accepted 17-03-2023

Available online 07-12-2023

#### Keywords:

GCT

Proximal radius

Resection

Reconstruction with prosthetic radial

head

### ABSTRACT

**Background:** Giant cell tumour is locally aggressive benign lesion arising from epiphysis of long bones, common in 2<sup>nd</sup> and 3<sup>rd</sup> decade of life. The most commonest sites being, lower end radius, upper end tibia, and lower end femur. Treatment depends upon stage of disease

**Case History:** Presenting here with a case of 36-yr old male presented with pain and swelling at rt elbow. Patient having GCT arising from upper end radius, was treated with excision of lesion and reconstruction of 4-cm defect with custom-made radial head prosthesis.

**Discussion:** A literature review of GCT upper end radius is very scanty, hardly any reports available, however for a lesion involving head and around 3-cm of neck with pathological #, treatment remains excision of tumour and reconstruction with prosthetic radial head.

This is an Open Access (OA) journal, and articles are distributed under the terms of the [Creative Commons Attribution-NonCommercial-ShareAlike 4.0 License](https://creativecommons.org/licenses/by-nc-sa/4.0/), which allows others to remix, tweak, and build upon the work non-commercially, as long as appropriate credit is given and the new creations are licensed under the identical terms.

For reprints contact: [reprint@ipinnovative.com](mailto:reprint@ipinnovative.com)

## 1. Introduction

Giant cell tumour is rare, benign but locally aggressive with incidence of 3 to 5 percent of all the primary bone tumours (McDonald et al. Sung et al. 1982). GCT arising from proximal end of radius is a very rare primary tumour site, incidence reported in literature is around 0.5% of all Giant cell tumours as reported in article<sup>1-3</sup> rare and there is hardly any literature available. Wide resection and reconstruction of proximal radius with prosthetic head is the treatment of choice, when tumour is extensively eroded cortices with pathological fracture to restore normal elbow function. Mere excision of 3-4 cms of proximal radius could result in long term proximal migration of radius and compromised function at elbow and wrist. Presenting here with case of GCT arising from upper end radius treated with wide excision and reconstructed with prosthetic head.

## 2. Case History

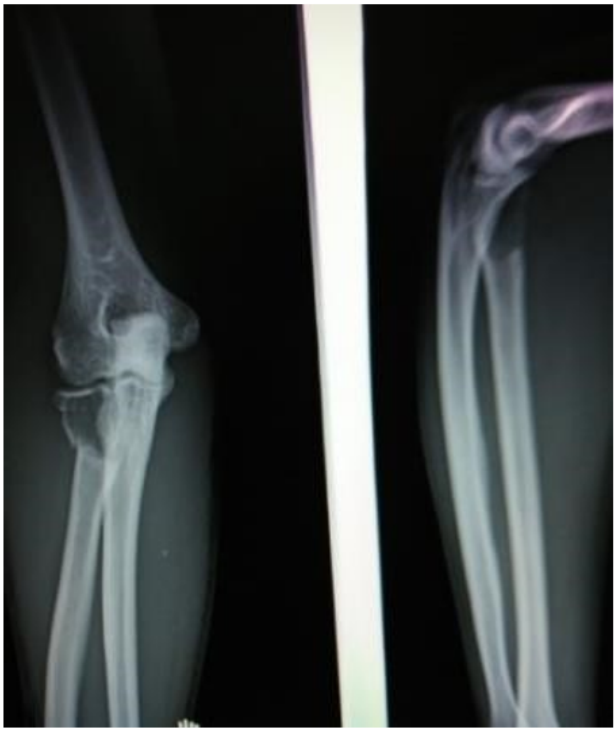36 year old male presented with H/o gradually increasing pain and swelling over Rt elbow for period of 5-months. There was no injury, fever. On examination there was ill-defined swelling over upper end radius with normal skin over swelling. On palpation there was vague tenderness over swelling with ill defined margins. Swelling was soft to firm in consistence and skin over swelling was not fixed to under laying swelling. Movements at elbow joint- Pt had FFD of 15 degrees with terminal painful restriction of terminal flexion and with restricted and painful pronation /supination.

X-ray of elbow with wrist showed osteolytic expansile lesion in proximal radius involving radial head and part of neck with ballooning of cortices and ? pathological fracture.

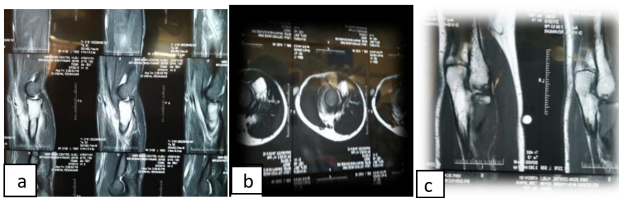
FNAC was done to establish the diagnosis of giant cell tumour and after locating size, extent on mri films, Figure 2 with Enneking gradeing patient was subjected for en block excision of tumour and reconstruction of leftover defect with radial head prosthesis.

\* Corresponding author.

E-mail address: [drkanakpur13@gmail.com](mailto:drkanakpur13@gmail.com) (S. Kanakpur).



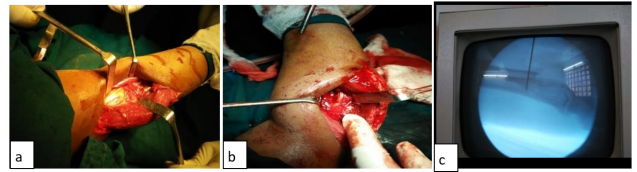**Figure 1:** Radiograph Ap and Lat rt elbow showing GCT of upper end radius with pathological fracture



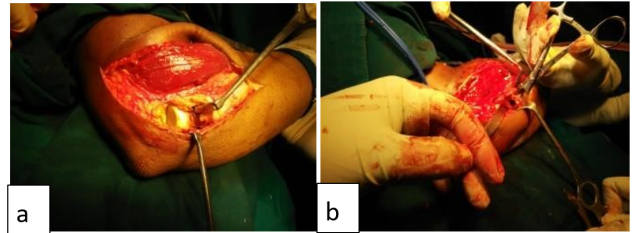
**Figure 2:** a,b,c): MRI different sections showing medullary extension of tumour with minimal soft tissue extension

Patient was operated under GA with tourniquet, tumour site was exposed with dorso lat incision over rt elbow incision curving dorsally around upper end radius, Attempt was made to dissect radial nerve above in elbow by dissecting in supra condylar region and between brachialis and FCR to identify post introsseous nerve, which is most vulnerable to injury during radial neck dissection and superficial radial nerve. Post introsseous nerve was traced down as it passes in substance of supinator muscle.(Figure 3 a, b) Once the course of nerve was located the proposed osteotomy site on neck was marked with k-wire under image intensifier. (Figure 3 c)

Neck was osteotomised at marked level and tumour site excised through posterior capsulotomy mobilising head and neck of radius proximally. Excision of tumour left with a gap of 4cms.(Figure 4 a, b)

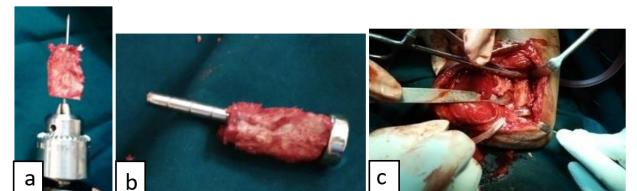


**Figure 3:**



**Figure 4:**

Custom made radial head was used to reconstruct defect with 8-cm stem. With a plan of securing 4-cm in the medullary canal with bone cement. Remaining 3-cm of stem adjacent to head, to cover this with a graft tri cortical iliac graft was used. Graft was harvested from iliac crest, and was reshaped to the size of radial diaphysis. Graft was prepared with a drilled hole in centre with 4-5 cannulated drill bit enough to pass prosthesis stem snugly through it. (Figure 5 a,b,c)



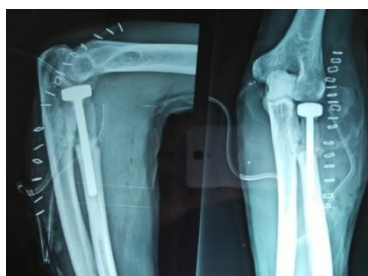**Figure 5:**

Thus prepared graft was placed in position Figure 5 c remaining 4-cm of stem was fixed with bone cement, graft alignment and mobility of the elbow was checked as the cement was setting. Remnants of annular lig sutured and capsular sutured. Intra op patient had full range of flex –ext with normal range of pronosupination. Pt was given pop post slab for 3-wks bending exercises started after 10-days.

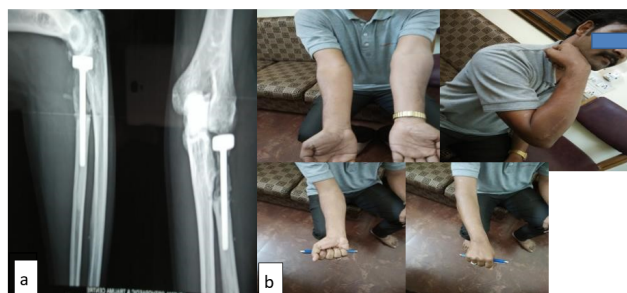Post op check x-ray showed well aligned radial head prosthesis good cement mental, with graft around stem.

At 14- months follow up x-ray of patient showing graft consolidation at diaphysis with no evidence of recurrence.(Figure 7 a) Patient was performing all sorts of daily activities like riding.

Motocycle, lifting weights ect without any problem and had no Pain whatsoever with full flexion/extension and pronosupination.(Figure 7 b)



**Figure 6:**



**Figure 7:**

Mayo elbow score was used to assess function of elbow depending on

1. Pain-non-45 mild-30 moderate-15 severe-0,
2. Motion Arc->100 degree -20pts 50-100 degrees 15pts < 50-degrees 5pts
3. Stability- stable 10pts moderately stable -5-pts
4. Stability function of elbow during day to day activities like combing hair, Feed self, Hygiene, can do shirt, can do shoe (each 5-pts).

Mayo functional evaluation score was 94 in this patient at 14-months post surgery.<sup>4</sup>

### 3. Results and Discussion

Proximal radius GCT is a rare site for GCT, it is locally aggressive tumour with high incidence of recurrence with conventional treatment like curettage and bone grafting for contained lesion specially in larger bone like upper end tibia lower end femur or lower end radius which are common sites for GCT. Incidence reported in literature is around 30%.<sup>5</sup> Use of adjuvant therapy like curettage with cryosurgery, phenol, burring, use of PMMA has brought recurrence marginally down to about 25%.<sup>5</sup>

Smaller bones with extensile lesions like upper end radius with uncontained defect and pathological fracture however not amiable to these treatment modalities wide excision of the tumour with reconstruction of left over defect (proximal 4-cms) of defect with metallic head if the right choice of treatment to prevent recurrence and to restore

normal anatomy and to restore normal biomechanics at elbow.

Significant fractures of radial head with severe degree of comminution may be treated with resection of radial head can result in instability of elbow and shortening of the radius. This causes alteration in the biomechanics of the wrist and elbow and impaired function (Hotchkiss RN, J Hand Surg 1989). Multiple techniques has been used to reconstruct the proximal radius to improve functional outcome including free vascular fibular graft,<sup>5</sup> iliac crest grafts fixed with intramedullary nail.<sup>1</sup> Reconstruction of the radial head using an endoprosthesis has been performed in cases involving complex unstable fractures of radial head. Long term results of radial head prosthesis done for severely comminuted fractures has been performed by various authors has given good results<sup>2,6</sup> Implants manufactured from acrylic, silicon, titanium and cobalt chrome providing varying level of success in restoration of function and stability reported in literature by various authors.<sup>2,6,7</sup>

However very scanty literature is available for reconstruction of proximal part of radius i.e head and significant length of neck for neoplastic conditions involving proximal radius which is extremely rare in 2002 Ward described use of custom-made prosthesis in 43-yr old male to reconstruct proximal radius following resection of metastasis from renal cell carcinoma.

In 2010, K Gokarju, J. Miles from Royal national orthopaedic hospital, Stanmore, UK, reported endoprosthetic reconstruction of proximal radius in 5-adult patients following non traumatic lesions involving various age groups at the time of surgery with average follow up of 7.6 yrs. In there follow-ups had all elbows were clinically stable and with 100% survivorship of the prosthesis. With function clinically evaluation by Mayo Elbow performance score of 86%.

In this particular case lesion was involving around radial head with 3-cms of the neck, so the total resection was around 4-cms. Due to technical constrains, proper custom-made prosthesis was not available.

Conventional radial head prosthesis used for traumatic conditions had shorter stem and were not suitable in this particular case and hence opted for custom-made long stem, stem of 8-cms to have anchor of about 4cm in radial medullary canal with bone cement. The bare part of stem between the radial head proximal diaphysis i thought of encircling tri cortical iliac crest graft from patient which would incorporate with diaphysis in due course of time. Graft was reshaped like a diaphysis by drilling central part with 4.5 mm drill to pass stem across.

### 4. Conclusions

Review of literature suggest two, reference<sup>1,7,8</sup> on management of GCT of proximal radius may be due to its rarity. However, extensile lesion of this magnitude in

small bone with pathological fracture wide excision with reconstruction of defect with modified prosthetic head seems to be logical management, restoring normal function and to prevent recurrence.

## 5. Source of Funding

None.


## 6. Conflict of Interest


None.


## References

- Zhu B, Yang J, Chang D, Yin X, Yang Q. Reconstruct the proximal radius with iliac graft and elastic intramedullary nail fixation after tumor resection. *World J Surg Oncol*. 2014;14(1):210.
- Harrington IJ, Tountas AA. Replacement of the radial head in the treatment of unstable elbow fractures. *Injury*. 1981;12(5):405–12.
- Lewis MM, Kaplan H, Klein MJ, Ferriter PJ, Lequouri RA. Giant cell tumour of the proximal radius. *Clin Orthop Relat Res*. 1985;201:186–9.
- Mayo Elbow Performance Score. *J OrthopTrauma*. 2006;20(8):127.
- Malawer MM, Henshaw RM, Shmookler BM. Of orthopaedic oncology in Principles of orthopaedic practice. 2nd ed. De R, Hurst LC, Gruber MA, editors. New- York: McGraw-Hill; 1997. p. 225–316.
- Ashwood N, Bain GI, Unni R. Management of Mason type-III radial head fractures with a titanium prosthesis, ligament repair, and early mobilization. *J Bone Joint Surg Am*. 2004;86(2):274–80.
- Singh AP, Mahajan S. Giant cell tumour of the proximal radius. *Singapore Med J*. 2009;50(11):e388–90.
- Khan KM, Minhas MS, Khan MA, Bhatti A. Giant cell tumour of the proximal radius in a 48- yrs old lady. *J Coll Physicians Surg Pak*. 2014;24(Suppl 1):48–9.

## Author biography

**Subhash M Mohite**, Consultant  <https://orcid.org/0000-0002-8932-5471>

**Shreyas Kanakpur**, Consultant  <https://orcid.org/0000-0003-3848-9019>

**Harish Kanakpur**, Consultant  <https://orcid.org/0000-0002-5316-9614>

**Cite this article:** Mohite SM, Kanakpur S, Kanakpur H. Giant cell tumour of proximal radius – A rare case report of treatment, with resection & custom- made radial head prosthesis. *Indian J Orthop Surg* 2023;9(4):262-265.