

Content available at: <https://www.ipinnovative.com/open-access-journals>

Indian Journal of Orthopaedics Surgery

Journal homepage: <https://www.ijos.co.in/>

Case Report

Management of a Giant Cell tumors with megaprosthesis in a resource-limited setting

Megan Augustus^{1*}, Allan Ali¹, Allan Beharry¹, David Armorer¹,
Derrick Lousaing¹

¹Dept. of Surgery, Port of Spain General Hospital, Trinidad and Tobago



ARTICLE INFO

Article history:

Received 01-02-2024

Accepted 06-02-2024

Available online 08-06-2024

Keywords:

Giant cell tumours

Prosthesis

Orthopaedics

Arthroplasty

Endoprosthesis

ABSTRACT

Giant Cell Tumors (GCTs) of bone are primary bone tumors that are benign. They are biologically aggressive and have metastatic potential after malignant transformation. There have been several cases of GCTs described in the medical literature. The management of juxta-articular GCTs in the young population is one of the greatest challenges in orthopaedic oncology. Amputations were once the standard treatment for malignant bone tumours. Advances in orthopaedic surgical techniques and bioengineering have made limb-sparing surgery a viable treatment option. Limb-salvage surgery is considered safe and is routinely undertaken for 90% of cases of bone tumors. The advances in orthopaedic surgical techniques and bioengineering of prosthesis have made this a viable option for these complex cases.

Staging is performed using the Campanacci Radiographic Classification System and this is based on the radiological findings of the GCT. This staging system is used to guide the planning of the initial surgical management. Campanacci Stage III GCTs are aggressive lesions thus En bloc resection and reconstruction have been proposed as the choice of treatment. This is done with the goal of joint preservation as well as reducing the risk of recurrence.

This case report highlights the challenges in the management of a Campanacci Grade III GCT of the distal femur. A mega prosthesis or endoprosthesis is a viable first-line treatment for oncological patients with significant bone and soft tissue loss. Oncological clearance was achieved then by the customized megaprosthesis was assembled and set in place. Procurement of this custom-made megaprosthesis during the COVID-19 pandemic was particularly challenging.

This is an Open Access (OA) journal, and articles are distributed under the terms of the [Creative Commons Attribution-NonCommercial-ShareAlike 4.0 License](https://creativecommons.org/licenses/by-nc-sa/4.0/), which allows others to remix, tweak, and build upon the work non-commercially, as long as appropriate credit is given and the new creations are licensed under the identical terms.

For reprints contact: reprint@ipinnovative.com

1. Introduction

GCT of Bone was first described in 1818 by Cooper and Travers.¹ Its local aggression was highlighted by Nelaton and its malignant potential by Virchow.² It is characterized histologically by large multi-nucleated osteoclast-like giant cells, with a background of mononuclear spindle-like stromal cells that exhibit osteoclastic activity.^{1,3} GCTs account for 5% of primary bone neoplasms and 20% of all primary bone tumours.⁴ Despite being described as benign

GCTs are locally aggressive, with breach of the cortex or soft tissue expansion; and have a high recurrence rate after surgical resection.¹

They predominantly occur for young adults aged 20-40 years. GCT rarely present in immature skeletons.^{3,5} These tumours commonly occur in long bones,¹ they have a predilection for the meta-epiphyseal regions of long bones such as in our case; 50-60% occur around the knee.¹ Juxta-articular tumour management is focused on clearance and reconstruction.

The typical clinical presentation is the complaint of pain due to bone resorption; localized swelling of the

* Corresponding author.

E-mail address: meganaugustus01@gmail.com (M. Augustus).

bone due to lysis and progression; limited range of motion secondary to their juxta-articular position; their expansile progression can lead to pathological fractures and soft tissue involvement.³ Although they are rarely lethal, they can lead to substantial disturbance of local bony architecture that can be particularly troublesome in peri-articular locations.⁶ Eighty percent of these cases have a benign course, 10-50% may recur and 10% may undergo *malignant transformation*; 1-4% may have pulmonary metastases despite their benign histology.^{7,8}

Delays during these patients' management can lead to detrimental outcomes. The high recurrence rate and metastatic potential warrants these cases to be closely followed up after the index procedure.

The surgical treatment is guided by the Campanacci Classification System. Other factors that are taken into consideration is the patient's age, their previous functional status, the anatomical location of the GCT. Surgical options to be considered are intralesional curettage with bone graft +/- adjuvant therapy, wide resection +/- bone graft/ polymethyl methacrylate (PMMA)/ internal fixation/ endoprosthesis, resection arthrodesis.^{6,9} Wide excision is recommended once the cortex has been breached with or without soft tissue involvement.⁹ Early stages can be managed by intralesional curettage +/- bone grafting. Adjuvant measures such as the use of phenol, liquid nitrogen, alcohol, and peroxide can be used to decrease the likelihood of recurrence to 6-25%.¹⁰ Denosumab, a monoclonal antibody targeting RANK ligand, can be used as neoadjuvant therapy.^{1,11} The challenge in choosing the treatment is complicated by the inability of the radiological and histological appearance to indicate the biological behaviour of these tumours.⁶

Endoprosthetic arthroplasty for Campanacci stage III achieves excellent functional and oncological outcomes. Megaprosthesis have a limited longevity due to mechanical failure. This limitation needs to be taken into consideration especially when being utilized in the younger population. Megaprosthesis facilitates improves functional outcomes as assessed by the Musculoskeletal Tumor Society Score (MSTS). The improvements made in surgical technique along with the advances in biomedical engineering over the last three decades have improved the longevity of these endoprostheses by 20-80%.⁶

2. Case Presentation

A 32-year-old male presented to the Orthopaedics Outpatient Clinic with a one-year history of atraumatic knee pain and swelling. A radiographic examination showed a lytic lesion of the right distal femur. The Magnetic Resonance Imaging (MRI) showed a well-defined, eccentric, expansile, lobulated lesion at the right lateral epi-metaphyseal region of the distal femur (63mm AP x 85 mm CC x 50 mm TR). The cortex was noted to be

thinning and breached, perilesional edema was also noted.

An incisional biopsy was done, which showed a GCT of the bone. The lesion was classified as Grade III according to the Campanacci classification. He subsequently had an intra-lesional curettage and reconstructed with an autologous cancellous graft.

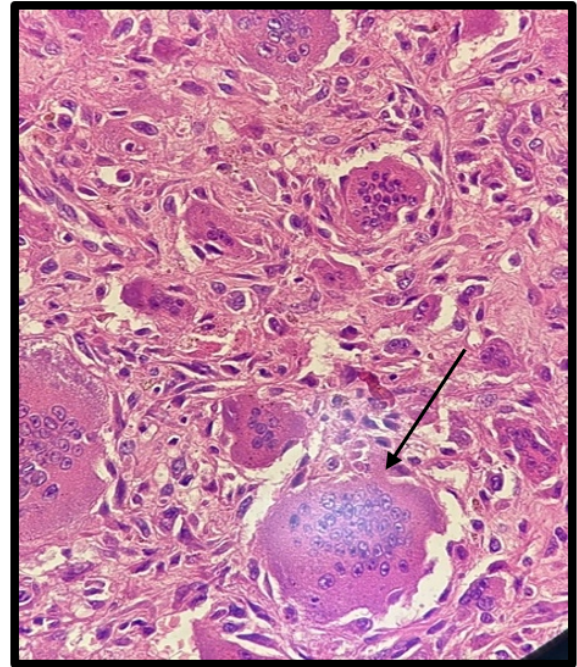


Figure 1: Photomicrograph (Hematoxylin-Eosin Stain) shows a background of mononuclear stromal cells and multinucleated giant cells (arrows).

Thirty days after his index surgery the patient was noted to have a draining sinus and subsequently had a débridement and curettage, the bone defect was filled with antibiotic-embedded cement. A clinical and radiographic follow-up was done at one, three, six, and twelve months post-operatively to confirm bone consolidation and to assess for tumour recurrence.

At the twelve-month review, the patient reported a 3-month history of right thigh pain and chills. A repeat MRI was done, which noted a recurrence of the GCT with aggressive features. This recurrent lesion was noted to extend into subarticular bone, with no evidence of extension into the joint space; there was an associated soft tissue component extending into the adjacent vastus lateralis muscle.

The patient underwent a wide resection and reconstruction with a customized mega prosthesis. An extended anterior incision followed by a mid-vastus approach provided exposure to the knee. The dissection was done superficially to the tumour through the biopsy site. The dissection continued to the joint line and the knee was disarticulated by incising the anterior capsule, both

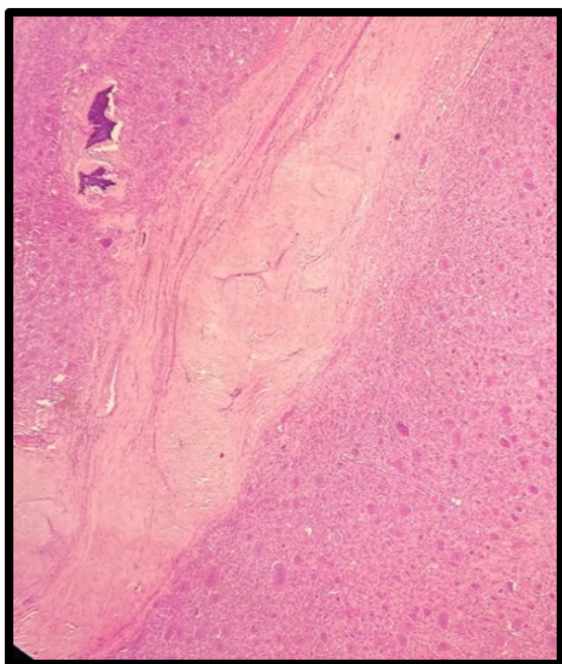


Figure 2: Photomicrograph shows a giant cell tumor with focal necrosis

cruciate ligaments, the meniscocapsular attachments as well as the collaterals around the posterior capsule. The proximal dissection was done to achieve 5 cm clearance, and the femur was osteotomized. The dissection continued distally maintaining proximity to the tumour posteriorly and meeting at the inferior dissection at the joint line posteriorly. The tumour was excised En bloc with the sinus tract as illustrated in Figure 6c. The popliteal fossa was assessed by the vascular surgeon. No tourniquet was utilized during this procedure. The Zimmer Biomet Orthopaedic Salvage System was inserted, this custom-made endoprosthesis was based on preoperative planning and measurements. The proximal tibia was prepared then the proximal femoral cavity was prepared. The trial components were assembled and offered to best fit. The knee was cycled, the area prepared, and the mega prosthesis cemented in situ. The incision was then closed in layers over a redivac drain.

R₀ resection was achieved, and the patient reports a Musculoskeletal Tumor Society score (MSTS) of 19.¹²

3. Discussion

The management of GCTs is challenging as their histological and radiological findings fail to reflect their biological behaviour.⁶ Aggressive features such as a wide zone of transition, thinning of the cortex, expansile remodelling, associated pathological fractures, and soft tissue masses may be noted on radiological investigation.

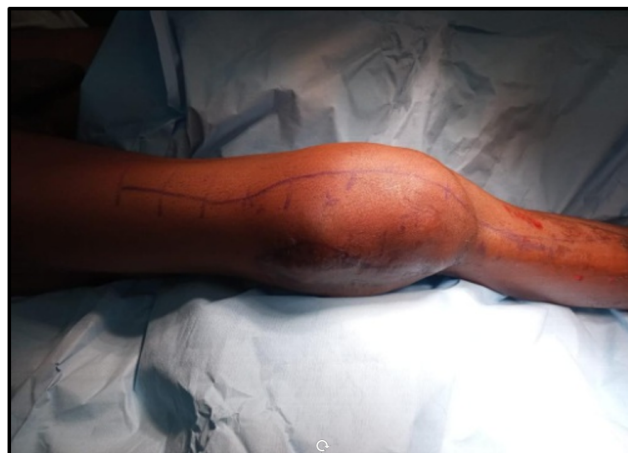

Figure 3: Preoperative photograph of right knee illustrating mass and diffuse swelling

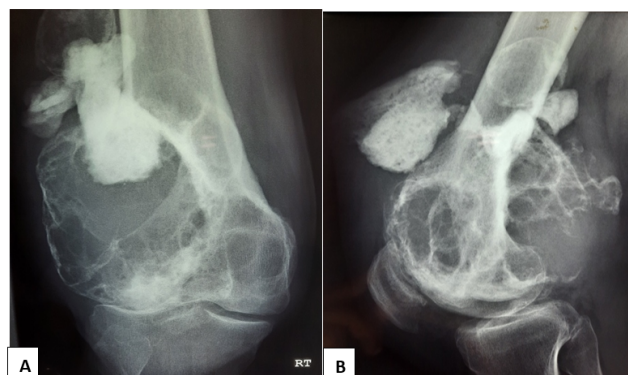

Figure 4: Recurrent GCT; (A): Anteroposterior Radiograph of the right knee shows an expansile lytic lesion of the lateral femoral condyle that extends into subchondral bone, destruction of the lateral cortex and an associated soft tissue mass; (B): Lateral Radiograph of the right knee shows the extension of lesion into the soft tissues

The gold standard treatment is surgical resection, aiming to attain oncological clearance while maintaining structural integrity.^{3,6,13} Depending on the extent of the osseous defect, limb-salvage surgery can be modality of choice and amputations can be avoided. En bloc resection and reconstruction almost completely eliminates the possibility of recurrence.¹⁴

Resection of juxta-articular malignant bone tumors can present challenges with reconstruction and preservation of functional ability. Reconstruction can be done with the use of biological and non-biological techniques. The modular mega prosthesis is the most frequently non-biologic reconstructive surgery for tumour resections that result in a large bone defect. Adjuvant therapies can aid in treatment in the control of local recurrence. Denosumab has recently been used as neoadjuvant chemotherapy in the

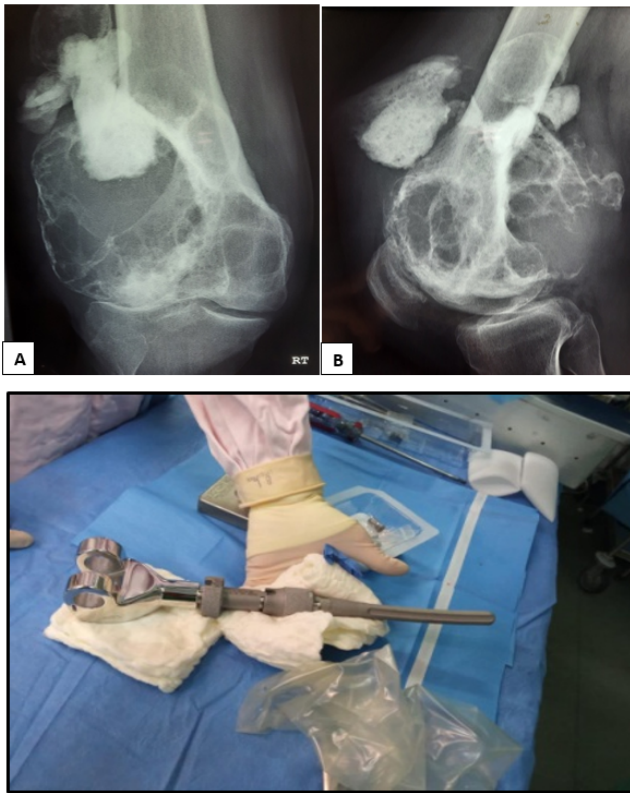

Figure 5: Photograph shows customized modular endoprosthesis

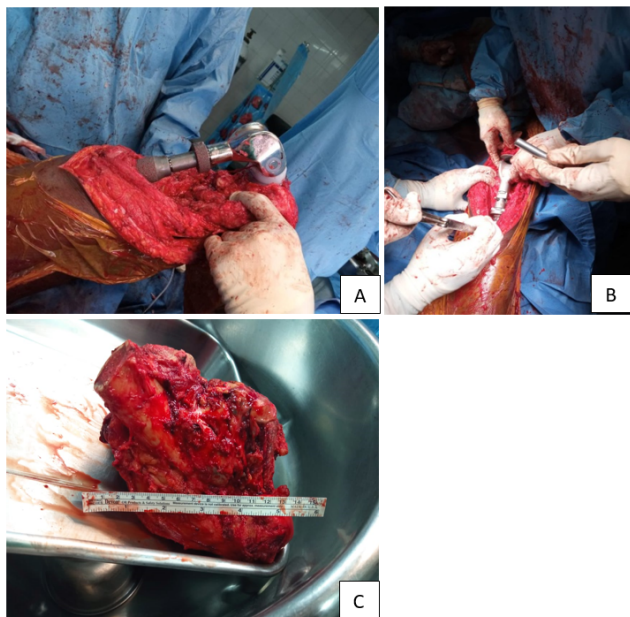


Figure 6: Intraoperative images: **A):** Megaprosthesis placement; **B):** Megaprosthesis placement; **C):** Resected tumour and sinus tract

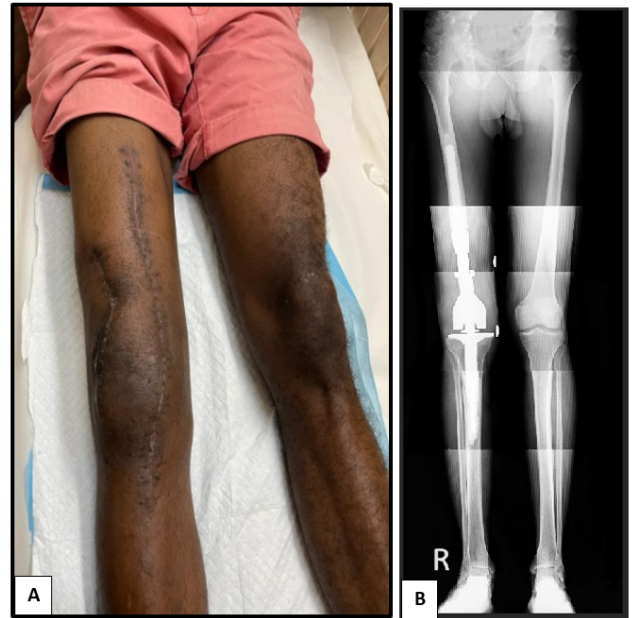

Figure 7: **A):** Post-operative photograph illustrating alignment; **B):** Post-operative long limb length radiographs with mega prosthesis in situ

treatment of GCT of bone.¹

Megaprosthesis reconstruction is a viable option for Campanacci Stage III GCT. As this has comparable oncological results to amputations. This prosthesis affords the patients an improved quality of life as they are able to weight bear early and have a shorter rehabilitation course post-operatively.¹³ In this case report, the joint was preserved by the placement of a customized mega prosthesis. The custom-made mega-prosthesis arthroplasty was effective and accomplished the desired functional results in this case. This reconstructive procedure was chosen based on durability, oncological prognosis, anatomy, and the ability to restore the function of the limb, as well as the needs of the patient.

The advantages of immediate restoration of weight bearing, maintenance of joint stability, early return to activities of daily living, early mobility, cost-effectiveness, and comparatively low rate of recurrence make this treatment option the most viable.⁶

However, it is not without its complications which can be classified as mechanical and non-mechanical. Fewer mechanical complications have occurred as technique and implant design have improved; prosthetic failure occurs when more than 40% of bone has been resected. Non-mechanical such as aseptic loosening, implant failure, and periprosthetic fracture. There is a concern with using this option in young patients because of the longevity of the prosthesis. The 5 and 10-year survivals are 76% and 66% respectively. This is considered to be a favourable outcome

for such complex surgical procedures.¹⁵ Prosthetic failure most commonly occurs at 48-72 months postoperatively.¹⁶ Long-term follow-up is required for these patients.

The high cost of these megaprosthesis is quite exorbitant. This can lead to delays in management, as it did in this case. Mega prostheses are not locally manufactured and needed to be imported. This custom mega prosthesis was manufactured using the dimensions that were assessed on radiographic investigations. The most common complications affecting the survival of these prostheses were aseptic loosening and infection, thus tailoring of the prosthesis must be done meticulously.

The funds for this case were provided by the Government of Trinidad and Tobago during the pandemic novel Covid-19 virus. The health care system of Trinidad and Tobago follows the Beveridge Model. This provides free health care to all citizens as most medical facilities are financed by the government.

The Covid 19 pandemic adversely affected healthcare across all medical sub-specialities- Trauma and Orthopaedics was no exception to this.¹⁷ This singular case was delayed due to resource prioritization during the pandemic. These issues included but were not limited to: the loss of elective operation time, reduction of funds for implants and prosthesis, the re-distribution of staff. These factors contributed to the delays in the management of urgent elective orthopaedic cases.^{18,19}

Despite these challenges, the patient had a successful oncological and functional outcome, with no recurrence after his 12-month review. These patients risk prosthetic complications as well as bone or soft tissue recurrence and face the risk of revision or amputation. They must be counselled extensively on these complications and have close follow-ups with clinical and radiological examinations. Follow-up radiographs are assessed for bone resorption, and bone or soft tissue mass with expansile destruction.²⁰

4. Conclusion

GCT management is complex and requires a multi-faceted approach. This case report highlights the surgical management of a juxta-articular GCT with a custom mega-prosthesis. The custom mega-prosthesis has become the first-line choice of treatment for aggressive GCTs. It is a technically superior reconstructive modality with notable advantages that outweigh the limitations. The COVID-19 pandemic adversely affected.

Despite the logistic challenges associated with the COVID-19 pandemic a favourable outcome was achieved for this case, paving the way for future management of these cases in a resource-limited setting.

5. Source of Funding

None.


6. Conflict of Interest


None.


References


1. Chakarun CJ, Forrester DM, Gottsegen CJ, Patel DB, White EA, Matcuk GR. Giant cell tumor of bone: review, mimics, and new developments in treatment. *Radiographics*. 2013;33(1):197–211.
2. Vanni D, Pantalone A, Andreoli E, Caldora P, Salini V. Giant cell tumor of the distal ulna: a case report. *J Med Case Rep*. 2012;6:143.
3. Cowan RW, Singh G. Giant cell tumor of bone: a basic science perspective. *Bone*. 2013;52(1):238–46.
4. Macwan AA, Nanda SN, Mishra D, Tuteja S, Sandeep B. A giant cell tumor of the distal femur managed by excision and knee arthrodesis using a custom made long intramedullary interlocking nail: a case report and review of the literature. *Cureus*. 2021;13(5):e14810.
5. Sobti A, Agrawal P, Agarwala S, Agarwal M. Giant Cell Tumor of Bone - An Overview. *Arch Bone Jt Surg*. 2016;4(1):2–9.
6. Natarajan MV, Prabhakar R, Mohamed SM, Shashidhar RA. Management of juxta-articular giant cell tumors around the knee by custom mega prosthetic arthroplasty. *Indian J Orthop*. 2007;41(2):134–8.
7. Szendrői M. Giant-cell tumour of bone. *J Bone Joint Surg*. 2004;86(1):5–12.
8. McGrath PJ. Giant-cell tumour of bone: an analysis of fifty-two cases. *J Bone Joint Surg*. 1972;54(2):216–29.
9. Kamal AF, Simbolon EL, Prabowo Y, Hutagalung EU. Wide resection versus curettage with adjuvant therapy for giant cell tumour of bone. *J Orthop Surg (Hong Kong)*. 2016;24(2):228–31.
10. Kamal AF, Muhamad A. Outcomes of En bloc resection followed by reconstruction of giant cell tumor around knee and distal radius. A case series. *Ann Med Surg (Lond)*. 2020;49:61–6.
11. Li H, Gao J, Gao Y, Lin N, Zheng M, Ye Z. Denosumab in Giant Cell Tumor of Bone: Current Status and Pitfalls. *Front Oncol*. 2020;10:580605.
12. Xu L, Li X, Wang Z, Xiong J, Wang S. Functional evaluation for patients with lower extremity sarcoma: application of the Chinese version of Musculoskeletal Tumor Society scoring system. *Health Qual Life Outcomes*. 2017;15:1–6.
13. Khan SA, Kumar A, Inna P, Bakhshi S, Rastogi S. Endoprosthetic replacement for giant cell tumour of the proximal femur. *J Orthop Surg (Hong Kong)*. 2009;17(3):280–3.
14. Pollock R. Management of benign bone tumours. *Orthop Trauma*. 2009;23:248–57.
15. Capanna R, Scoccianti G, Frenos F, Vilardi A, Beltrami G, Campanacci DA. What was the survival of megaprotheses in lower limb reconstructions after tumor resections? *Clin Orthop Relat Res*. 2015;473(3):820–30.
16. Prabowo Y, Ramang DS, Farqani S, Karda IW. A modified technique of mega prosthesis revision on non-neoplastic patient: Case report. *Ann Med Surg (Lond)*. 2020;58:68–72.
17. Selby L, Tripathi V, Hariharan S. Knowledge, Attitudes and Practices (KAP) regarding the Novel Coronavirus Disease (COVID-19) Post-lockdown in Trinidad and Tobago. *Soc Work Public Health*. 2021;36(5):558–76.
18. Chackan S, Islam S, Seepaul T, Harnarayan P, Naraynsingh V. COVID 19 And Its Impact On Orthopaedic Fracture Surgery And Traumatology In An Eastern Caribbean Island-A Retrospective. *British Journal of Medical & Health Sciences (BJMHS)*. 2021;3(5).
19. Haleem A, Javaid M, Vaishya R, Vaish A. Effects of COVID-19 pandemic in the field of orthopaedics. *J Clin Orthop Trauma*. 2020;11(3):498–9.
20. Parmeggiani A, Miceli M, Errani C, Facchini G. State of the art and new concepts in giant cell tumor of bone: imaging features and tumor characteristics. *Cancers (Basel)*. 2021;13(24):6298.


Author biography

Megan Augustus, -  <https://orcid.org/0000-0003-3187-9380>

Allan Ali, -  <https://orcid.org/0009-0000-0135-7974>

Allan Beharry, -  <https://orcid.org/0000-0003-4198-036X>

David Armorer, -  <https://orcid.org/0009-0005-7521-6695>

Derrick Lousaing, -  <https://orcid.org/0009-0001-0096-1536>

Cite this article: Augustus M, Ali A, Beharry A, Armorer D, Lousaing D. Management of a Giant Cell tumors with megaprosthesis in a resource-limited setting. *Indian J Orthop Surg* 2024;10(2):189-194.