

## Dynamic HIP screw vs proximal trochanteric contoured plate in proximal end fractures of femur

Kanwarjit Singh Sandhu<sup>1</sup>, Girish Sahni<sup>2,\*</sup>, Avinash Chander Gupta<sup>3</sup>, Vikas V Patel<sup>4</sup>, Tajinder Bhalla<sup>5</sup>

<sup>1</sup>Associate Professor, <sup>2</sup>Assistant Professor, <sup>3</sup>Ex-Professor, <sup>4,5</sup>Junior Resident, Dept. of Orthopaedics, Govt. Medical College, Patiala, Punjab

**\*Corresponding Author:**

Email: sawhneygirish@gmail.com

### Abstract

**Purpose:** To compare the outcome in patients who underwent surgery for proximal end femur fracture, intertrochanteric and Subtrochanteric, using dynamic hip screw vs proximal femoral locking plate.

**Methods:** 11 men and 19 women aged 19 to 82 (mean, 42) years were randomised to the proximal femoral locking plate group, whereas 16 men and 14 women aged 20 to 90 (mean, 47) years were randomised to the conventional 135° DHS group. Duration of surgery, total amount of blood loss, duration of hospital stay, mobilisation and weight bearing, radiological assessment, complications and Harris hip score were assessed at the end of 6 months.

**Results:** Respectively in the locking plate and DHS groups, the mean duration of surgery were 72.18 mins and 54.25 mins, (p=<0.001), mean blood loss was 283.75ml and 158.67 ml (p=<0.001), mean hospital stay was 13.75 days and 11.25 days, mean time for radiological union was 16.8 and 16.5 weeks, average harris hip score was 84.6 and 86.2. varus collapse and screw cut-out occurred in 1 case each in DHS, abductor lurch occurred in 4 cases of PFLP.

**Conclusion:** DHS is the best implant for stable IT fractures but PFLP can also be a good alternative for unstable IT fracture, though it has longer operative time and more blood loss.

**Keywords:** Proximal femoral locking plate, Dynamic hip screws, Proximal femur fractures

**MESH words:** Internal fixation, Proximal femur fracture, Extramedullary devices

### Access this article online

**Website:**

www.innovativepublication.com

**DOI:**

10.5958/2395-1362.2016.00041.4

fixation and angular stable fixation compared with conventional treatment, even in the case of unstable fracture in osteoporotic bone.<sup>[24]</sup>

The PFLP fixation offers better functional results and fewer complications than the DHS for the treatment of unstable intertrochanteric fractures.<sup>[25]</sup>

We therefore compared outcomes of the 2 modalities for proximal end femur fractures in terms of duration of surgery, total amount of blood loss, duration of hospital stay, mobilisation and weight bearing, radiological assessment, complications and harris hip score was assessed at the end of 6 months.

### Materials and Methods

This study Informed consent of each patient was obtained. 60 patients underwent surgery for proximal femoral fractures and were analysed. 11 men and 19 women aged 19 to 82 (mean, 42) years were randomised to the proximal femoral locking plate group, whereas 16 men and 14 women aged 20 to 90 (mean, 47) years were randomised to the conventional 135° DHS group. Randomisation was based on the odd and even serial numbers at presentation. 4 cases of comminuted fractures were treated with DHS while 5 cases of comminuted fractures were treated with PFLP. The modes of injury in the respective groups were: road traffic accident (n=12 and 3) and fall (n=18 and 27). Children and patients with compound fractures and associated head, chest or abdominal injuries were excluded.

### Introduction

DHS – implant system is a technically simple and widely used operative treatment modality for pertrochanteric fractures of the femur. There is considerable variation in reported failure rates for operative treatment of intertrochanteric fractures. Failure seems related to two factors, the type of internal fixation used and the stability of the fracture.<sup>[14]</sup>

Simpson et al in 1989 stated that the complications like primary or secondary varus collapse, hardware failure by cut-out of the femoral head screw of dynamic hip screw and higher incidence of secondary implant failure with the use of cephalomedullary nails are reduced with proximal femur locking compression plate.<sup>[3]</sup>

Proximal femoral locking compression plate (PFLCP) has been developed recently, which merges locking screw technology with conventional plating techniques. Theoretically, this technique could offer optimum fixation of comminuted and highly unstable fractures that are associated with more shearing and pull-out forces. Proximal Femoral Locking Compression Plate (PFLCP) provides three dimensional

The mean intervals from injury to surgery were 5 and 6 days for the locking plate and DHS groups, respectively. Preoperative skeletal or skin traction was provided. Radiographs were taken; fractures were classified according to the Evans for intertrochanteric fractures and Seinsheimers for subtrochanteric fractures. The neck shaft angle of the affected and the opposite normal hips was measured, and involvement of the greater (lateral wall) and lesser (posteromedial buttress) trochanters was noted. The fractures were stabilised during upper tibial skeletal traction until surgery, and reduced by closed means on a fracture table under image intensification. DHS fixation was performed using conventional techniques.

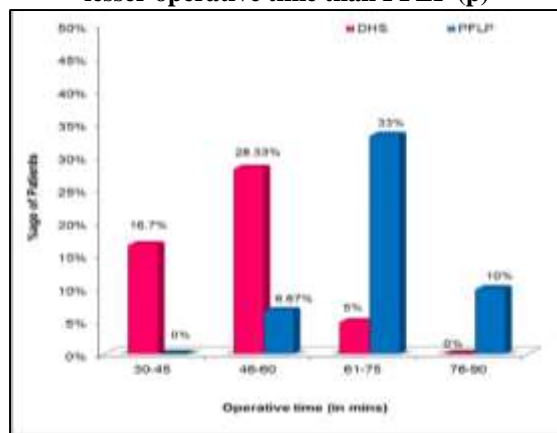
For fixation with a proximal femoral locking plate (PFLP), a longitudinal incision along the great trochanter was taken and iliotibial band was incised. The plate was slid distally in the submuscular plane using a distal counter incision (about 4.0 cm) at the level of the tip of the plate. Three locking neck screws were inserted at 95°, 120° and 135° following a guide wire. Guide wire were inserted into the femoral neck at 135° and then at 95° under image intensification. The neck was drilled over the 95° guide wire first and a 6.5 mm locking neck screw was inserted to counter the collapse. A 6.5-mm locking neck screws was then inserted at 135°. The remaining locking screws were inserted into the shaft. The wound was closed in layers under negative suction drainage. Antibiotics and analgesics were given as per the hospital protocol. Patients were allowed to perform quadriceps-strengthening exercises the next day. Mobilisation with no weight bearing was allowed, followed by partial weight bearing on crutches or with walking frame after 6 to 8 weeks. Sutures were removed on day 14. Patients were followed up at every 2 weeks for 2 months and thereafter monthly for 18 months to assess hip and knee function, limb shortening, callus growth, and growth, and fixation defects. Radiological evidence of callus with no tenderness was regarded as bone union. The duration of surgery, total amount of blood loss, duration of hospital stay, mobilisation and weight bearing, radiological assessment, complications and harris hip score were assessed at the end of 6 months. The 2 groups were compared using the chi square test and Student's t test.

## Results

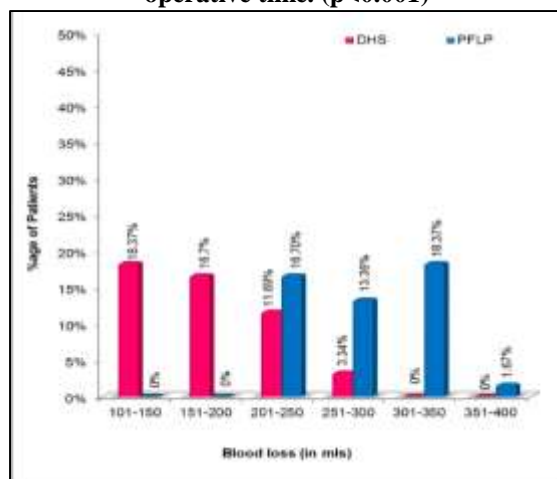
Respectively in the locking plate and DHS groups, the mean operative time was 72.19 min and 54.25 min ( $p < 0.001$ ) the mean blood loss volumes were 283.75 ml and 158.67 ml ( $p < 0.001$ ) the mean length of hospital stays were 13.75 day and 11.25 day, the mean times to union were 16.8 weeks and 16.5 weeks, partial weight bearing was at 4.73 weeks and 2.93 weeks ( $p < 0.001$ ), full weight bearing was at 14 weeks and 13 weeks, the harris hip score was excellent in 10 and 15 patients, good in 17 and 9 patients, fair in

7 and 6 patients. There were no poor results seen. Superficial wound infection occurred in 3 and 2 patients. Abductor lurch occurred in 4 and 1 patient. Varus collapse and screw cut-out were seen in one case in DHS group. Average Harris hip score respectively for PFLP and DHS, overall it was 84.6 and 86.2 ( $p = 0.463$ ), in IT fractures it was 80.78 and 86.22 ( $p = 0.062$ ), in ST fractures it was 90.5 and 86.17 ( $p = 0.060$ ). In stable IT fractures it was 94.44 and 77.4. P value was  $< 0.001$  which is highly significant. In Unstable IT fracture the score was 78 in DHS and 85 in PFLP. The P value was 0.020 which was significant.

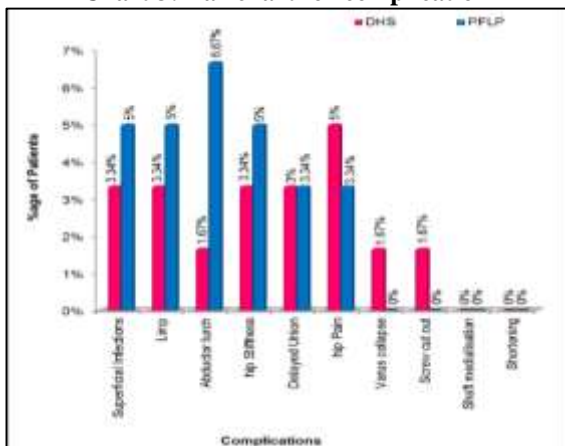
**Chart 1: Bar Chart of operative time. DHS had lesser operative time than PFLP (p)**



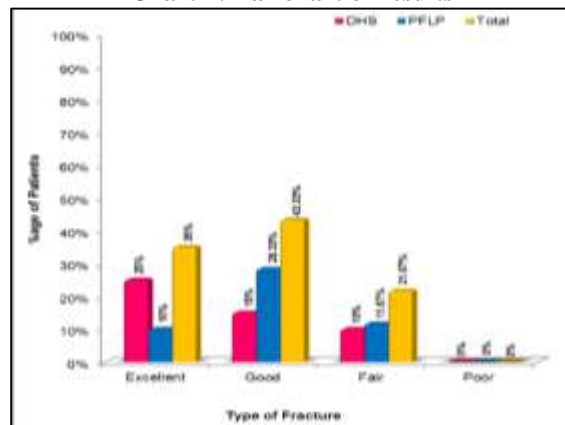
**Chart 2: Bar chart of blood loss. DHS had lesser blood loss due to lesser dissection and lesser operative time. ( $p < 0.001$ )**



**Chart 3: Bar chart for complication**



**Chart 4: Bar chart of results**

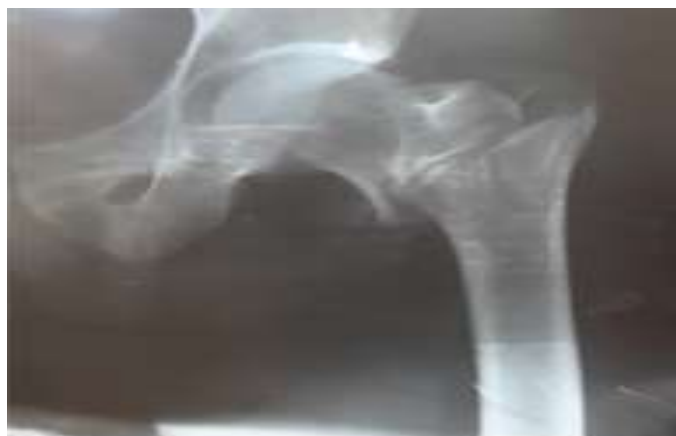

**Table 1: Average harris hip scores for IT and ST fractures operated by DHS and PFLP**

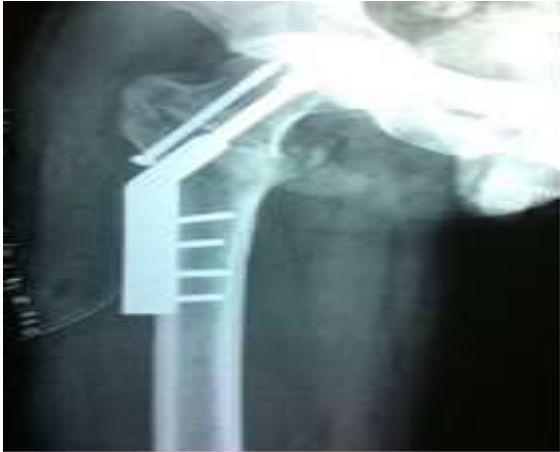Type of Fracture	DHS		PFLP		Total	Total
	Average score	No. of cases	Average score	No. of cases	Average score	No. of cases
Overall	86.2	30	84.6	30	88.24	60
IT	86.22	18	80.78	18	83.5	36
Stable IT	94.44	9	77.4	10	85.47	19
Unstable IT	78	9	85	8	81.29	17
ST	86.17	12	90.5	12	88.33	24
Total	-	30	-	30	-	60

**Table 2: Statistical analysis of harris hip scores obtained in IT and ST fractures treated with DHS and PFLP. DHS in stable fractures shows highly significant results while PFLP in unstable fractures shows significant results**

Fracture	T value	P value	Significance
Overall	0.785	0.463	NS
IT	1.933	0.062	NS
Stable IT	94.44	<0.001	HS
Unstable IT	78	0.020	S
ST	86.17	0.060	NS



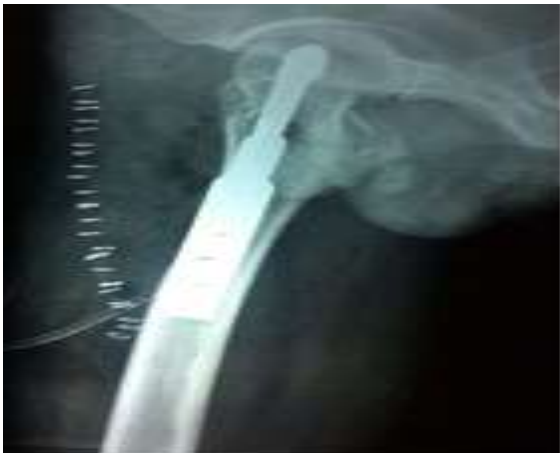**Fig. 1: Pre-op AP X-ray**



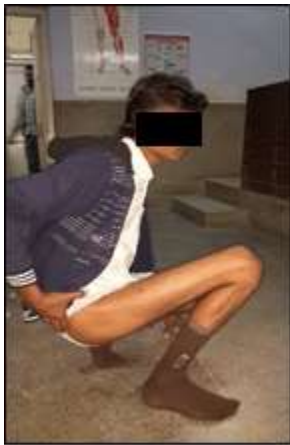**Fig. 2: Post-op AP X-ray**



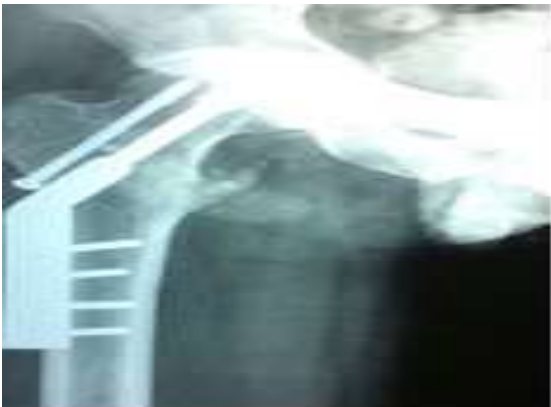**Fig. 5: Standing**



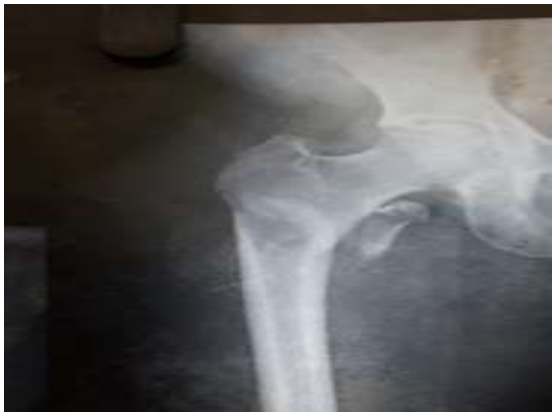**Fig. 3: Post-Op Lateral X-ray**



**Fig. 6: Squatting**



**Fig. 4: 6 month follow up**



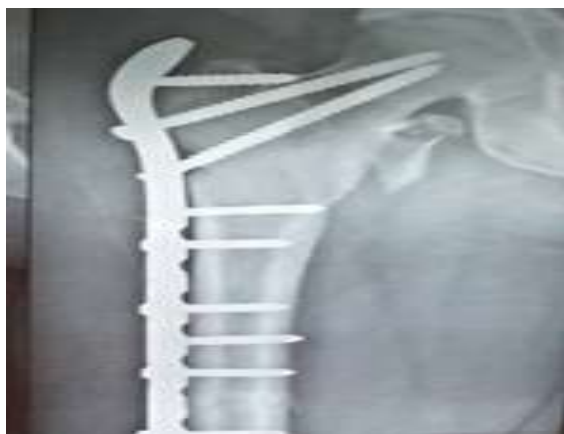
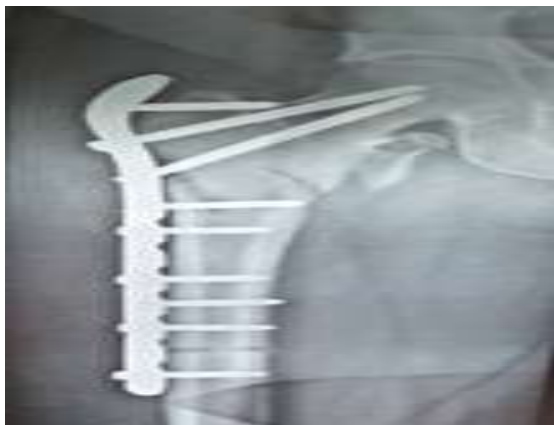
Fig. 7: Pre-op, Post-op & 6month follow up

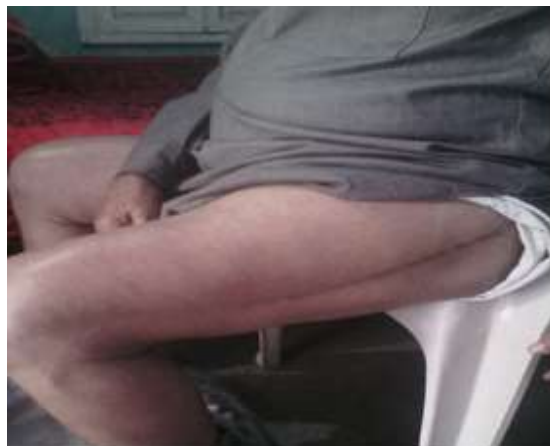
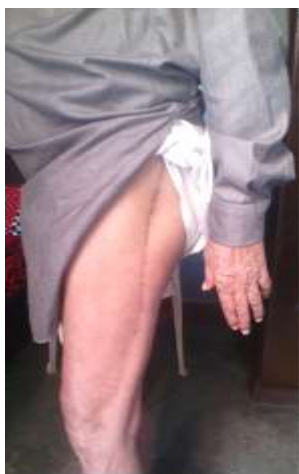
Fig. 8: 6month follow up standing & sitting on chair

### Discussion

Proximal femur fractures are seen with increasing frequency and severity as the life expectancy of our population increases. The primary goal in the treatment of an elderly patient with proximal femur fracture is to return the patient to his / her pre - fracture activity as early as possible. Rapid mobilization of these elderly patients reduces the morbidity and mortality rate in geriatric patients.

Before the introduction of suitable fixation devices, treatment of proximal femur fractures was non-operative, consisting of prolonged bed rest in traction until fracture healing occurred (usually 10 – 12 weeks), followed by a lengthy programme of ambulation training. In elderly patients, this approach was associated with high complication rates; typical problems included Decubitus ulcers, pressure sores Urinary tract infection, Joint contractures, Pneumonia and Thromboembolic complications, resulting in a high mortality rate. In addition, fracture healing was generally accompanied by varus deformity and shortening because of the inability of traction to effectively counteract the deforming muscular forces.

For these reasons, the treatment of proximal femur fracture by reduction and internal fixation has become the standard method of treatment.

The Sliding Nail-Plate devices gave rise to Sliding Hip Screw devices. The nail portion was replaced by a blunt-ended screw with a large outside thread diameter. The first author to describe a sliding hip screw device was Schumpulick W.

One early modification to the Sliding Hip Screw maximized fracture impaction by allowing the proximal lag screw to telescope within the plate barrel and the plate to slide axially along the femoral shaft. To accomplish this bi-directional sliding, the plate was modified by replacing the round screw holes with slotted screw holes (Egger's plate). More recently, a two-component plate device was introduced (Medoff plate, Medpac, Culver City, CA) in which a central vertical channel constrains an internal sliding

component. Both devices have been used successfully for the treatment of stable and unstable intertrochanteric fractures.

Hence, for these various complications associated with other fixation devices in the treatment of unstable intertrochanteric fractures, Dynamic Hip Screw Fixation has become the Gold standard treatment.

Fixation using a DHS may lead to implant failure secondary to unimpeded co-axial collapse of the proximal fragment with medialisation of the shaft. The screw may back out of the DHS side plate, owing to increased stresses at the screw plate junction. This problem can be tackled using a non-collapsing implant with a locking neck and shaft screws. Proximal femoral locking plate is such an implant which provides lateral buttress, is non-collapsing and helps to maintain reduction until union with less risk of limb shortening or varus collapse.

So, DHS and PFLP both are effective implants for extramedullary fixation of pertrochanteric and subtrochanteric fractures of femur. The present study was conducted to compare the results of DHS and PFLP in pertrochanteric and subtrochanteric fractures of femur.

The patients in our study ranged in age from 19 to 90 years (mean 45.07 years) Maximum number of cases were from 5<sup>th</sup> and 6<sup>th</sup> decade. Mean age of DHS were 47.7 and that of PFLP was 42.45 years Average age in the study of Bolhofner et al(1999)<sup>(42)</sup> was 79 years while it was 51 year in the study of Gupta et al(1974).<sup>(69)</sup>

Females were found to be little higher than males. 45% were males and 55% were females. This was similar to the studies of Ecker et al(1975) which had 74% female and 26%, Dhamangaonkar et al(2013) which had 29 female and 11 male<sup>(60)</sup>, Parker et al<sup>(73)</sup> (1992) which had 112 females and 82 males suggesting that the incidence of proximal femoral fractures among females is higher than the incidence of such fractures among males.

During the course of the present study it was observed that the commonest cause of proximal end femur fracture was fall. 75% of patient's sustained fracture due to fall and 25% sustained fracture due to road side accidents. Trivial fall was found to be commonest mode of injury in studies of Hornby et al<sup>(83)</sup>(2015) 55%, Gupta et al<sup>(69)</sup> (1974) 79.4%.

In this study, 60% of the fractures were intertrochanteric fractures, of which 31.67% were stable and 28.33% were unstable. 40% were subtrochanteric fractures. According to Mervyn Evans the Intertrochanteric fractures are considered as stable or unstable depending upon integrity of posteromedial cortex. Fractures with intact posteromedial cortex are considered as stable fractures while fractures with loss of posteromedial cortex are considered as unstable fractures. Posteromedial cortex constitutes mainly the lesser trochanter.<sup>[86,87,88,89,90]</sup>

In present study 9 patients (15%) had associated injuries. 2 patients had pubic diastasis. 2 patients had fracture both bone forearm (ipsilateral). 1 patient each were having ipsilateral fracture shaft of tibia, fracture proximal end tibia, fracture distal end radius, fracture pott's and fracture distal femur.

The operative time was comparatively lesser in DHS group(p value- 0.001)with 27 (45%) cases completed within 60 minutes in DHS group compared with 4 (6.67%) in PFLP. 3 (5%) cases of DHS and 26 (43.33%)of PFLP took between 60 to 90 minutes operative time. Operative time for DHS was 31 minutes in the study of Bolhofner et al<sup>(42)</sup>(1999), while it was 50 minutes in the study of Pajarinen et al<sup>(92)</sup>(2005). The operative time for PFLP was 80 minutes in the study of Kumar et al<sup>(63)</sup>(2014) and it was 62.46 minutes in Han et al<sup>(57)</sup>(2012).

Intraoperative blood loss was significantly lesser in DHS group (p value <0.001) with 70 % patients having less than 200 ml blood loss. While in PFLP group blood loss was greater with 63.46% patients having 251 to 350 ml blood loss. Blood loss for DHS in the study of Bolhofner et al<sup>(42)</sup>(1999) was 77 ml, while it was 279 ml in the study of Dhamangaonkar et al<sup>(60)</sup> (2013). For PFLP blood loss was 200 ml in the study of Kumar et al<sup>(63)</sup>(2014) and 286 ml in Dhamangaonkar et al<sup>(60)</sup> (2013).

Drain output was comparatively higher in PFLP group then DHS group. (P value<0.001).

In the present study 90% patients were discharged within 15 days of surgery. 96% cases of DHS and 83% cases of PFLP were discharged within 15 days of surgery. DHS group patients were discharged earlier then PFLP group. The average hospital stay In DHS in the study of Dhamangaonkar et al<sup>(60)</sup> was 18 days while in Gotfried et al<sup>(43)</sup> (2000) it was 8.7 days. The average stay for PFLP was 22 days in the study of Dhamangaonkar et al.

In our study superficial infection, limp and hip stiffness were observed in 2 cases of DHS and 3 cases of PFLP. Abductor lurch was in 4 cases of PFLP and in 1 case of DHS. Delayed union was seen in 2 cases of DHS and PFLP each. Hip pain was seen in 3 cases of DHS and 2 cases of PFLP. DHS had complication of varus collapse and screw cutout in 1 case each. Shaft medialization was observed in one case of DHS. No shortening was seen in any case. In the study of Dhamangaonkar et al<sup>(60)</sup>(2013) respectively in DHS and PFLP deep wound infection occurred in 2 and 3 patients, medialization of the shaft occurred in 15 and 0 patients, varus collapse occurred in 5 and 2 patients, Implant cut out occurred in one patient in each group, mean lengths of limb shortening were 0.3 and 1.4 cm.Sun-Jun et al<sup>(58)</sup> (2012) found in their study of PFLP one case of severe infection, three cases of superficial infection, two patients had implant failure(loosening) due to early weight bearing and underwent surgery again, two patients had femoral neck screw breakage at

3 months postoperatively but fracture healed after delaying the weight bearing time and there were no cases of screw cutting through the femoral head. In the study of Azboy et al<sup>[94]</sup> (2014) Implant failure/loosening and/or nonunion was observed in two patients (10%), malunion was seen in 1 case, superficial infection was seen in 1 case, screw cut out and plate fracture in 1 case each in the PFLP group. Loosening of locking screws occurred mainly in patients with multiple fragmentary pertrochanteric fractures and was possibly due to the medial calcar fracture and inadequate reduction. In a series of 35 patients with Seinsheimer type 3-5 comminuted subtrochanteric fractures, Saini et al<sup>[61]</sup> (2013) used PFLP. All patients achieved union, which occurred in an average of 15.6 weeks. There were two cases of delayed union, one case of malunion, and two cases of shortening of 1 cm.

In DHS group partial weight bearing was started earlier with 26.67% of patients weight bearing by 2 weeks and 21.67% by 4 weeks (p value <0.001) whereas none of the case fixed by PFLP was bearing weight by 2 weeks. In PFLP group partial weight bearing was started if features of instability were not there at 4 weeks, 96.68% started partial weight bearing by 6 weeks. So earlier mobilization can be achieved in DHS than in PFLP.

Full weight bearing in DHS group was allowed after clinical unions. 83.34% were bearing weight by 14 weeks. Full weight bearing could be started later in PFLP group. 70.14% were bearing full weight by 14 weeks. Full weight bearing was possible earlier than PFLP group in DHS group. Mean time of full weight bearing was 14.3 weeks for DHS in the study of Penugonda et al (2015).<sup>[93]</sup>

The time of union ranged from 14-20 weeks in both the groups. 83.4% of DHS group showed union within 16 weeks and 49.8% of PFLP group showed union in 16 weeks. Union was achieved in all the patients with average of 16.5 weeks in DHS (P value <0.045) group and 16.8 weeks in PFLP group. The time of radiological union in the study of Penugonda et al<sup>(93)</sup> (2015) was 15.5 weeks, while in Dhamangaonkar et al<sup>(60)</sup> it was 16.5 weeks. For PFLP union was achieved in 14.6 weeks in the study of Dhamangaonkar et al and in 13.5 weeks in the study of Kumar et al<sup>(63)</sup>.

66.67% of patients were walking with the help of stick at 3 months of post-operative period of which 36.67% were of DHS group and 30% were of PFLP group. 3 month mobility was better in DHS group than in PFLP group.

There was no significant difference between mobility after 3 month and 6 month in both DHS and PFLP groups. 75% patient were able to walk without aid after 6 months from both groups.

Overall DHS group had little higher average Harris hip score than PFLP group. In Intertrochanteric fractures DHS group had average score of 86.22, which is better than average score of 80.78 in PFLP group In

IT fractures, stable IT fractures treated by DHS had also better score(94.44) (p value <0.001) than score of PFLP group(77.4).

In contrast unstable fractures treated by PFLP group had better Harris hip score of 85 than score of DHS group of 78 (p value – 0.020). Similarly in subtrochanteric fractures of femur treated by PFLP group Harris hip score was better (90.5) than in DHS group(86.17). Apparently PFLP was better in unstable IT and Subtrochanteric fractures while DHS was better in stable IT fractures. In the study of Dhamangaonkar et al excellent harris hip score was achieved in 18 patients of DHS and 11 patients of PFLP.

## Conclusion

Harris hip score comparison of study suggests that functional results are better in DHS than PFLP. Less Blood loss, less operative time, early weight bearing are other favouring factors in DHS. When this comparison was done for stable and unstable fractures in the group it was found that score was significantly better in PFLP group for unstable fractures. Though blood loss and operative time was more, rigidity of fixation was better specially in unstable fractures in PFLP group. We conclude that DHS is the best implant for stable proximal femoral fractures with lesser operative time and lesser blood loss. While PFLP can be a good alternative for unstable proximal femoral fractures with better results with slightly longer operative time and more blood loss.

## Bibliography

1. Flores LA, Harrington IJ, Heller M. The stability of intertrochanteric fractures treated with a sliding screw plate. *J Bone Joint Surg Br* 1990;72-B:37-40.
2. Evans E M. The treatment of intertrochanteric fractures of the femur. *J BJS* 1949;31-B:190-203.
3. Simpson AH, Varty K, Dodd CA. Sliding hip screws: modes of failure. *Injury*. 1989;20:227-231.
4. Lenich A, Mayr E, Ruter A, Mockl C, Fuchtmeyer B. First results with the Trochanter Fixation Nail (TFN): a report on 120 cases. *Arch Orthop Trauma Surg*. 2006;126:706-712.
5. Utrilla AL, Reig JS, Munoz FM, Tufanisco CB. Trochanteric gamma nail and compression hip screw for trochanteric fractures: a randomized, prospective, comparative study in 210 elderly patients with a new design of the gamma nail. *J Orthop Trauma*. 2005;19:229-233.
6. Bolhofner BR, Russo PR, Carmen B. Results of intertrochanteric femur fractures treated with a 135-degree sliding screw with a two hole side plate. *J Orthop Trauma*. 1999;13(1):5-8.
7. Gupta RC. Conservative treatment of intertrochanteric fracture of femur. *Indian Journal of Orthopaedics* 1974;36(6):229.
8. Dhamangaonkar AC, Joshi D, Goregaonkar AB, Tawari AA. Proximal femoral locking plate versus dynamic hip screw for unstable intertrochanteric femoral fractures. *J Orthop Surg (Hong Kong)*. 2013;21(3):317-22.
9. Parker MJ. Trochanteric hip fracture. *Acta Ortho Scand* 1996;67(4):329-332.

10. Hornby R, Evans JG, Vardon V. Operative or conservative treatment for trochanteric fractures of the femur. A randomised epidemiological trial in elderly patients. *J Bone Joint Surg Br.* 1989;71(4):619-623.
11. Sadowski CAL, Saudan M, Riand N, Stern R, Hoffmeyer P. Treatment of reverse oblique and transverse intertrochanteric fractures with use of an intramedullary nail or a 95° Screw-Plate: A Prospective, Randomized Study. *J Bone Joint Surg Amr* 2002;84:372-81.
12. Gadegone WM and Salphale YS. Short proximal femoral nail fixation for trochanteric fractures. *Journal of Orthopaedic Surgery* 2010;18(1):39-44.
13. Simmermacher RK, Bosch AM, Van der Werken C. The AO/ASIF- proximal femoral nail (PFN): A new device for the treatment of unstable proximal femoral fractures. *Injury* 1999;30:327-32.
14. Tencer AF, Johnson KD, Johnson DWC, Gill K. A biomechanical comparison of various methods of stabilisation of subtrochanteric fractures of the femur. *J Orthop Res.* 1984;2:297:181.
15. Windoff J, Hollander DA, Hakmi M, Linhart W. Pitfalls & complications in the use of proximal femoral nail. *Lagenbecks Arch Surg.* 2005;3901.
16. Pajarinen J, Lindahl J, Michelsson O, Savolainen V, Hirvensalo E. Ptertrochanteric femoral fractures treated with a dynamic hip screw or a proximal femoral nail. A randomised study comparing post-operative rehabilitation. *J Bone Joint Surg Br.* 2005;87(1):76-81.
17. Kumar N, Kataria H, Yadav C, Gadagoli BS, Raj R. Evaluation of proximal femoral locking plate in unstable extracapsular proximal femoral fractures: Surgical technique & midterm follow up results. *J Clin Orthop Trauma.* 2014;5(3):137-145.
18. Han GH, Wei W, Gu J. Comparison of proximal femoral locking plate and Gamma nail in the treatment of the femoral intertrochanteric fractures in the elder. *Zhongguo Gu Shang.* 2012;25(10):796-9.
19. Gotfried Y. Percutaneous compression plating of intertrochanteric hip fractures. *J Orthop Trauma* 2000;14(7):490-495.
20. Sun-Jun Hu, Zhang S, Guangrong YU. The treatment of femoral subtrochanteric fractures with the proximal lateral femur locking plates. *Acta Ortop Bras.* 2012;20(6):329- 33.
21. Azboy I, Demirtaş A, Gem M, Cakır IA, Tutak Y. A comparison of proximal femoral locking plate versus 95-degree angled blade plate in the treatment of reverse intertrochanteric fractures. *Eklem Hastalik Cerrahisi.* 2014;25(1):15-20.
22. Saini P, Kumar R, Shekhawat V, Joshi N, Bansal M, Kumar S. Biological fixation of comminuted subtrochanteric fractures with proximal femur locking compression plate. *Injury* 2013;44:226-31.
23. Penugonda RS, Vanga A, Babu GRS, Sagar SRV. Comparative study between proximal femoral nailing and dynamic Hip screw in the Management of Intertrochanteric fractures of Femur. *Journal of Evidence based Medicine and Healthcare* 2015;(2)5:541-548.
24. Vanamali B. et al. A comparative study of clinico-radiological outcome: DHS verses PFLCP in intertrochantric fractures of femur. *Journal of evidence based medicine and healthcare.* 2015 Month: November Volume: 2 Issue: 50 Page: 8565-8570.
25. Zhong B et al. A comparison of proximal femoral locking compression plates with dynamic hip screws in extra capsular femoral fractures. *Orthop Traumatol Surg Res.* 2014 Oct;100(6):663-8. doi: 10.1016/j.otsr.2014.06.012. Epub 2014 Aug 22.