

## Complex proximal tibia fracture dislocations managed by Ilizaorov fixator- A case series with review of literature

Arunodhaya Siddartha<sup>1</sup>, Supreeth Nekkanti<sup>2\*</sup>, Purushotham Sastry<sup>3</sup>, Seshagiri<sup>4</sup>, Abhilash G<sup>5</sup>

<sup>1,4</sup>Assistant Professor, <sup>2</sup>Senior Resident, <sup>3</sup>Professor, <sup>5</sup>Junior Resident, Dept. of Orthopaedics, JSS Hospital, Mysore

**\*Corresponding Author:**

Email: drsupreethn@gmail.com

### Abstract

**Background:** Bicondylartibial fractures are serious injuries and are difficult to manage even for the most experienced trauma surgeons. The soft tissue around proximal tibia demonstrates poor healing response following dissection or manipulation. Hence surgical fixation of these injuries by osteosynthesis has shown mixed results over the years.

**Case Series:** We conducted a prospective study of five consecutive patients of compound proximal tibia bicondylar fractures from January 2013 to June 2016. All of them were compound type 3A or 3B injuries classified according to Gustilo-Anderson grading system of open injuries. ILIZAROV fixator was used for treatment in all the cases. The fixator was kept for an average of twelve to twenty weeks. The patients range of motion and knee society score was recorded at the end of 32 weeks.

**Results:** The average range of movements achieved in the knee joint was 105 degrees at the end of eight months. Complications included knee stiffness and pin site infections. Knee stiffness was managed by subjecting the patient to aggressive physiotherapy by continuous passive movements. In one patient manipulation under general anesthesia had to be done. Two patients had pin site infections which were superficial and subsided by antibiotics and daily pin site dressings. The knee society score was excellent in four patients and good in one patient.

**Conclusion:** This case series emphasizes the clinical success and low morbidity to the patient when treated with ILIZAROV fixator. The technique is suited well to manage complex proximal tibia injuries as it provides a stable construct in all the planes. Anatomical reduction of fragments can be achieved by closed reduction using olive wires during ILIZAROV application. This would avoid excessive dissection of soft tissue required during plating.

**Keywords:** Proximal tibia fracture; Knee dislocation; ILIZAROV fixator; Knee joint

### Access this article online

**Website:**

www.innovativepublication.com

**DOI:**

10.5958/2395-1362.2016.00046.3

### Introduction

Bicondylar tibial fractures are serious injuries and are difficult to manage even for the most experienced trauma surgeons.<sup>[1,2-5]</sup> Bicondylar tibial plateau fractures are caused due to high velocity accidents. The viscoelastic nature of the bone results in tibia absorbing a large amount of energy which dissipates into the soft tissue envelope around the proximal tibia. The consequent injury to the soft tissue envelope around the proximal tibia often poses a threat and is the cause of poor wound healing post-operatively. The soft tissue around proximal tibia demonstrates poor healing response following dissection or manipulation.<sup>[1,3,4,6]</sup> Hence surgical fixation of these injuries by osteosynthesis has shown mixed results over the years.

### Materials and Methods

We conducted a prospective study of compound bicondylar proximal tibia fractures from January 2013 to June 2016. Five consecutive patients were included in this study. All of them were compound type 3A or

3B injuries classified according to Gustilo-Anderson grading system of open injuries.<sup>[1,7]</sup> The fractures were classified as per Schatzker classification as type 5 or type 6 injuries.<sup>[1]</sup> All the patients were clinically examined for varus or valgus instability of the knee joint at the time of presentation in the emergency room. Plain radiographs of the knee joint were taken in the antero-posterior and lateral views. Once the complexity of the injury was observed in the radiographs, we proceeded to take a computed topography scan (CT) of the affected joint. After a diagnosis was reached, complete clinical work up was done and the patient was prepared for surgery.

All the patients were operated under spinal block or epidural block. Prophylactic intravenous antibiotics were administered which included cephalosporins, aminoglycoside and metronidazole combination. All surgeries were done without use of pneumatic tourniquet. The limb was kept in traction using a traction table with the foot fixed in a shoe. A thorough wound wash was given initially after which a comprehensive wound debridement was done.

Under fluoroscopy (C-arm guidance) fracture reduction was achieved in antero-posterior and lateral views using traction table. The articular surface of tibia was anatomically reduced using a reduction forceps and if needed an additional olive wire was inserted across the fracture fragments to hold it in place.

Three olive wires sized 1.8mm were used in the proximal tibia. The first olive wire was inserted from the lateral aspect of tibial condyles at a point just above the head of fibula directed medially. A second olive wire was passed from antero-lateral aspect of the tibia directed posteromedially. The third olive wire was passed from antero-medial aspect of tibia directed posterolaterally. Two half-pins (Schanz pins) were inserted in the tibial shaft distal to the fracture site.

Similarly two half-pins were inserted in the distal femur at the level of femoral condyles and two half pins in the femoral shaft. Thus two femoral rings and two tibial rings were constructed and all the rings were connected by connecting rods.

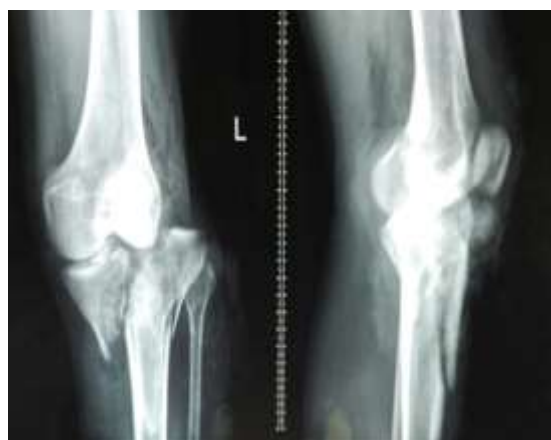The patient was made to walk immediately on the next day after surgery. The femoral rings were removed four to six weeks after surgery to enable knee joint mobilization. The ILIZAROV fixator was retained for an average duration of twelve to twenty weeks. The patients were followed up for at least eight months. The patient's range of movement of the knee joint was noted at 8, 12, 16 and 32 weeks after surgery. The final range of motion achieved at the knee joint was noted. The knee was scored using the knee society score at 32 weeks. Knee stiffness was managed by physiotherapy in the form of continuous passive movement and manipulation under general anesthesia if necessary. Pin site infections were managed by antibiotics and daily pin site dressing.

## Results

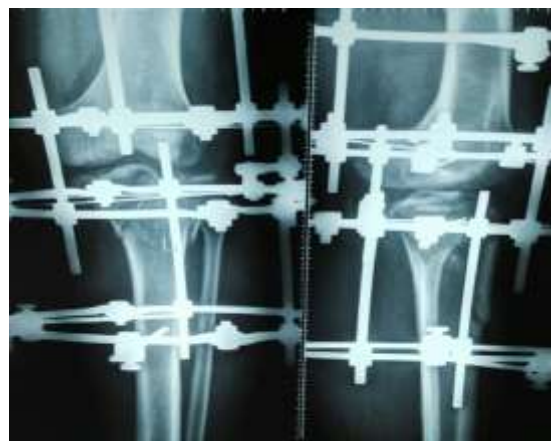
From January 2013 to June 2016, we treated five patients with compound 3A bicondylar proximal tibia fractures. All the patients were operated with an ILIZAROV fixator with two rings stabilizing the femur and two rings stabilizing the proximal tibia. The patients were followed up for a minimum period of eight months. The average age of the patients in this study was 47 years. All the five patients were males. Three patients had injured their left knee and the remaining two their right knee. The mechanism of injury was road traffic accidents in all the patients, three of them suffered type 3A injuries, while two patients suffered type 3B injuries.

All the patients were operated within six hours of presentation to the authors in the emergency department. The fracture fragments were reduced and aligned in all the cases by closed reduction by using traction table or by using olive wires. Two patients had knee subluxation in addition to the fracture of proximal tibia. The patients were encouraged full weight bearing the next day after surgery. The femoral rings were removed after an average duration of five weeks. The patient was encouraged knee range of movement exercises after removal of femoral rings. The ILIZAROV fixator was removed after an average duration of sixteen weeks.

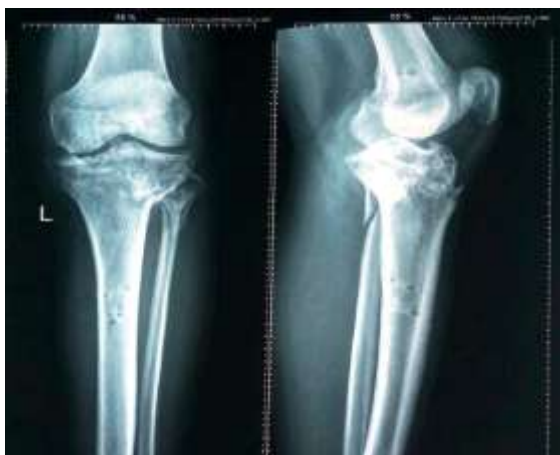The patients were followed up for a minimum period of eight months. The average range of movements achieved in the knee joint was 105 degrees at the end of eight months. Complications included knee stiffness and pin site infections. Knee stiffness was managed by subjecting the patient to aggressive physiotherapy by continuous passive movements. In one patient manipulation under general anesthesia had to be done. Two patients had pin site infections which were superficial and subsided by antibiotics and daily pin site dressings. The knee society score was excellent in four patients and good in one patient.



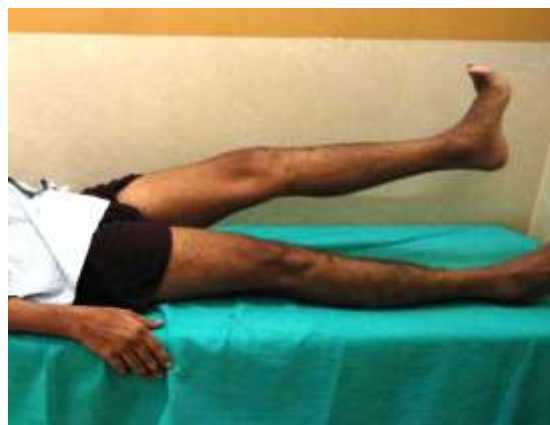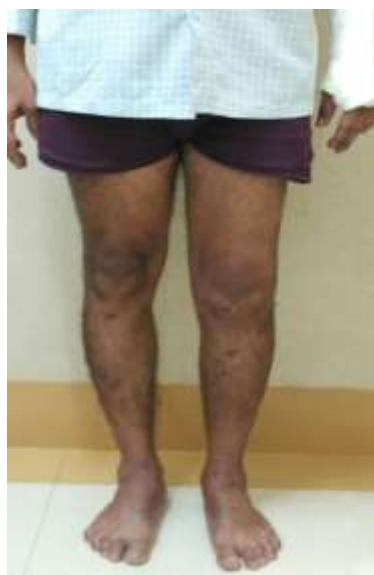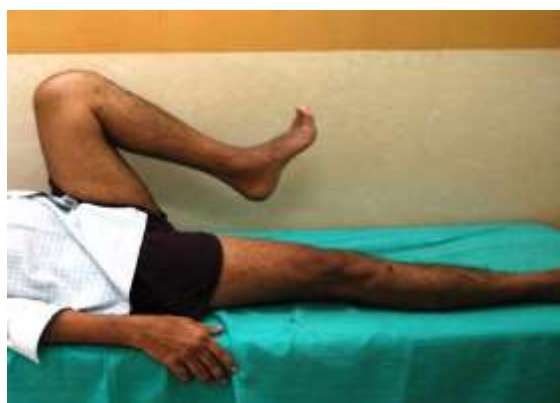**Fig. 1: Pre-operative X-ray of the knee joint**



**Fig. 2: Post-operative X-ray**



**Fig. 3: Post-operative X-ray after five months**



**Fig. 5: Range of movements of the knee joint**

### Discussion

Various strategies have been reported and debated over the ideal surgical technique to be adopted to manage these injuries. Open reduction and internal fixation with dual plating was considered to be the gold standard to treat bicondylar tibial plateau fractures. The advantages of plating lies in the fact, that the surgeon can inspect the articular surface when in doubt regarding articular congruity. It also allows the surgeon to achieve anatomical reduction of the fracture. Although the option of dual plating is well received by patients, it has been associated with a lot of complications such as poor wound healing, wound infections, osteomyelitis and eventually septic arthritis.<sup>[1,6,9-13]</sup> In a study done by Jiang et al the complication rates following dual plating was 7.3%. Similar studies by Yang and Moore showed complication rates to be as high as 13.6% and 19%. Boreier al and Yang et al reported in their studies that the average number of surgeries the patient would have to undergo after plating was 3.3 and 5 respectively to manage the complications.

Some surgeons have attempted monoplanar external fixators to manage these injuries. Although post-operatively reduction could be achieved, maintaining the reduction till union of the fracture was the biggest challenge faced by surgeons.<sup>[1,14,15]</sup> The main concern with monofixator was inability of the construct to provide adequate instability.<sup>[15]</sup> The reason for this is due to the cantilever forces acting on the external fixator. This places the external fixator at a mechanical disadvantage as it has to provide stability to the bone which is at a distance from the body of the external fixator.<sup>[1]</sup> The complication rate following monofixator were however low compared to that of plating.<sup>[1,14,15, 20]</sup>

Circular external fixator offers a reasonable solution as it reduces soft tissue complications and also provides a stable fixation till union of the fracture. The reason for stability is due to the fact that the ILIZAROV fixator provides a stable construct in all

three planes.<sup>[21]</sup> Understanding this fact, we conducted a study in our small series of patients.

ILIZAROV fixator essentially works on the principle of ligamentotaxis. Hence using traction, closed reduction could be achieved in all our patients. However this may not be possible in all the cases as suggested by Marsh et al in his study, where he was able to reduce 16 fractures out of 21 by closed reduction.<sup>[1,15]</sup> Barbary et al effectively could achieve closed reduction in 24 out of 30 patients<sup>[1]</sup> The authors recommend operating the patient at the earliest possible time would allow easy reduction of the fracture without needing to use an incision to open the fracture site. We operated all the patients within six hours of presentation to the emergency department.

The average duration of using the fixator was 16 weeks in our series. Barbary et al<sup>[1]</sup> also reported in his study the average duration of application of fixator was 16 weeks. Kumar and Whittle [1.12] published their results, in which the duration of fixator use was 24.7 weeks.

Using Rasmussen criteria for radiographic assessment, excellent/ good reduction was achieved in all our patients.

The mean range of movement of the knee joint achieved by Guadinez et al was 85 degrees<sup>[1,6]</sup>. Moriandi and Pearse achieved 113 degrees<sup>[1,16]</sup> and Zecher 90 degrees.<sup>[1]</sup> The average knee range of motion achieved in our case series was 105 which is reasonably more than the above studies. The average knee score as per the knee society score in our case series was 86.4. Barbary et al<sup>[1]</sup> was able to demonstrate a comparable average knee society score of 87.7 and Mikulak et al demonstrated a score of 78.5<sup>[1]</sup>.

There is little information that focuses on the results of treatment of high energy fractures. In our study most of the patients suffered from high velocity accidents which led to such serious injuries. Barbary et al<sup>[1,20]</sup> studied that two variables had a direct correlation with the final range of movement of the knee which were knee distraction and associated femoral fractures. In our study none of the patients had distal femoral fractures. Also all the patients were subjected to knee distraction using the femoral rings. The good results in our study could possibly be attributed to these two factors.

Barbary et al<sup>[1]</sup> also attributed 45% of the unsatisfactory results in his study, was due to open injuries. He explained that a healthy soft tissue cover played a vital role in achieving a good functional outcome. In our study all patients had open injuries of Gustilo-Anderson type 3A or 3B.

In our study we observed pin tract infection in two patients. They were however superficial and subsided on antibiotics and daily pin site dressing. Young and Barrack<sup>[1,18]</sup> observed deep infections in eight patients in his study who were treated with plates while Mallik et al<sup>[1,14]</sup> found deep infections in five patients treated

with plates. In the current study, pin site infection did not affect the functional outcome of the limb.<sup>[1,12,14,19,21]</sup>

## Conclusion

This case series emphasizes the clinical success and low morbidity to the patient when treated with ILIZAROV fixator. The technique is suited well to manage complex proximal tibia injuries as it provides a stable construct in all the planes. Anatomical reduction of fragments can be achieved by closed reduction using olive wires during ILIZAROV application. This would avoid excessive dissection of soft tissue required during plating. The high incidence of surgical site infection associated with plating can be easily avoided with ILIZAROV fixator. ILIZAROV fixator allows immediate weight bearing which cannot be done with plating. A good functional outcome can thus be achieved in complex bicondylar proximal tibia injuries using an ILIZAROV fixator. It reduces morbidity to the patient, duration of stay in hospital and the economic burden to the patient. Thus the authors recommend ILIZAROV fixator to be a definitive management for complex proximal tibia fractures.

## References

1. H. El Barbary. H. Abdel Ghani. H. Misbah. K. Salem, Complex tibial plateau fractures treated with ILIZAROV external fixator with or without minimal internal fixation. *International Orthopaedics (SICOT)* (2005) 29:182-185.
2. Ballmer FT, Hertel R, Notzli HP (2000) Treatment of tibial plateau fractures with small fragment internal fixation: a preliminary report. *J Orthop Trauma* 14:467-474.
3. Buckle R, Blake R, Watson JT et al (1993) Treatment of complex tibial plateau fractures with the ILIZAROV external fixator. *J Orthop Trauma* 7:167.
4. Collinge C, Sanders R, DiPasquale T (2000) Treatment of complex tibial periarticular fractures using percutaneous techniques. *Clin Orthop* 375:69-77.
5. Dendrinis GK, Kontos S, Katsenis D, Dalas A (1996) Treatment of high-energy tibial plateau fractures by the ILIZAROV circular fixator. *J Bone Joint Surg Br* 78:710-717.
6. Guadinez RF, Mallik AR, Sporn M (1996) Hybrid external fixation of comminuted tibial plateau fractures. *Clin Orthop* 328:203-210.
7. Gustilo RB, Anderson JT (1976) Prevention of infection in the treatment of one thousand and twenty-five open fractures of long bones. *J Bone Joint Surg Am* 58:453-461.
8. Schatzker J, McBroom R, Bruce D (1979). The tibial plateau fracture. The Toronto experience 1968-1975. *Clin Orthop* 138:94.
9. Insall JN, Dorr LD, Scott RD, Scott WN (1989) Rationale of the Knee Society clinical rating system. *Clin Orthop* 248:13-14.
10. Jensen DB, Rude C, Duus B, Bjerg-Nielsen A (1990) Tibial plateau fractures. A comparison of conservative and surgical treatment. *J Bone Joint Surg Br* 72:49-52.
11. Koval KJ, Helfet DL (1995) Tibial plateau fractures evaluation and treatment. *J Am Acad Orthop Surg* 3:86-94.
12. Kumar A, Whittle AP (2000) Treatment of complex (Schatzker type VI) fractures of the tibial plateau with

- circular wire external fixation: retrospective case review. *J Orthop Trauma* 14:339–344.
13. Lobenhoffer P, Tschern H, Schulz M et al (1999) Closed reduction/percutaneous fixation of tibial plateau fractures. *J Orthop Trauma* 13:426–431.
  14. Mallik AR, Covall DJ, Whitelaw GP (1992) Internal versus external fixation of bicondylar tibial plateau fractures. *Orthop Rev* 21:1433–1436.
  15. Marsh JL, Smith ST, Do TT (1995) External fixation and limited internal fixation for complex fractures of the tibial plateau. *J Bone Joint Surg Am* 77:661–673.
  16. Morandi M, Pearse MF (1996) Management of complex tibial plateau fractures with the ILIZAROV external fixator. *Tech Orthop* 11:125.
  17. Mikulak S, Gold S, Zinar D (1998). Small wire external fixation of high-energy tibial plateau fractures. *Clin Orthop* 356:230–238.
  18. Young MJ, Barrack RL (1994). Complications of internal fixation of tibial plateau fractures. *Orthop Rev* 23:149–154.
  19. Weiner LS, Kelley M, Yang E et al (1995). The use of combination internal fixation and hybrid external fixation in severe proximal tibia fractures. *J Orthop Trauma* 9:244–250.
  20. Mohamed OA. Treatment of high-energy tibial plateau fractures using the ILIZAROV circular fixator. *Egypt Orthop J* 2013;48:173-9.
  21. Telmo Ramos, Carl Ekholm, Bengt I Eriksson et al.(2013) The ILIZAROV external fixator - a useful alternative for the treatment of proximal tibial fractures A prospective observational study of 30 consecutive patients. *BMC Musculoskeletal disorders* 14:11.