

Idiopathic Adhesive Capsulitis, results of single corticosteroid injection and exercises

Santosh Lakshmanrao Munde^{1,*}, Hemlata Thakurdas Kamra², Anil Dharampaul Gulia³, Sanjay Middha⁴

^{1,3,4}Associate Professor, Dept. of Orthopaedics, ²Associate Professor, Dept. of Pathology, BPS Govt. Medical College, Khanpur, Haryana

***Corresponding Author:**

Email: slmunde93@gmail.com

Abstract

Introduction: Adhesive capsulitis of shoulder is associated with painful loss of range of motion (ROM). Many authors consider it as a self-limited condition, however it can persist for years & may not fully resolve. Pathologically, specimens show capsular hyperplasia along with fibrosis. The condition is more common in females and in diabetic patients. The optimal treatment of this condition is controversial, with varying degrees of success with different modalities of treatment.

Material and Methods: Fifty patients with idiopathic adhesive capsulitis were included in the study carried out at BPSGMC, Khanpur. Single intraarticular corticosteroid injection was given in each patient using posterior approach & the patients were put on a home based exercise program. The pre injection status of the patient was recorded and the patients were followed up till 6 months. The results were evaluated using VAS score, improvement in range of motion & a functional shoulder rating score. (L' Insalata et al.)

Results: Out of the 50 patients, 8 patients were lost to follow up & 12 patients did not recover as per the criteria. The average pre injection status of the patients in terms of VAS score, ROM & shoulder rating score were improved. The average recovery time was 14.2 weeks. Out of 12 patients who did not recover 7 opted for hydro dilatation, 3 opted for arthroscopic capsular release & 2 patients refused any intervention.

Discussion: The incidence of adhesive capsulitis is 3% in general population. Number of treatment options is available. Combination of intraarticular corticosteroid and an exercise programme provides a safe & effective method for treating this condition. There are many studies in literature which have compared the results of intraarticular steroid injection with physiotherapy and combination of both. The method is safe, cost effective and does not have major risks. The results of our study show that combination of a single dose of intraarticular steroid and physical exercises can form a first line of treatment in treatment of idiopathic adhesive capsulitis.

Conclusion: This simple method is effective and most of the patients will recover. With refinement of the technique like use of ultrasonography results can be further improved. However a long term follow up is required before concluding the real efficacy of this method

Keywords: Adhesive capsulitis, Intraarticular steroids, Physical exercises, Frozen shoulder, Shoulder pain.

Introduction

Adhesive capsulitis of shoulder (frozen shoulder) is a common condition with controversial treatment. It is associated with painful loss of range of motion (ROM). Contraction of the joint capsule and its adherence to the head of humerus causes this condition.^(1,2) Some authors consider this condition as a self-limiting disorder and have recommended supervised neglect for treatment of this disorder^(3,4) while others with long term follow up have observed incomplete recovery in these patients.⁽⁵⁾ Most commonly used treatment modalities include physical therapy,^(4,6,7) NSAIDs,⁽⁸⁾ oral corticosteroids,^(9,10) intraarticular corticosteroid injections,⁽¹¹⁻¹⁵⁾ manipulation under anesthesia^(16,17) and surgical capsular release.^(18,19) Since it is found to be associated with inflammatory synovitis and adherence of the capsule, intraarticular corticosteroid injection with physical exercises is considered to be effective in the treatment of this condition.

Material and Methods

The study was carried out at BPSGMC & Hospital from Jan. 2015 to Dec. 2015. Fifty patients presenting to

the Orthopaedics OPD were included in the study. The diagnosis of adhesive capsulitis was made on the basis of history and physical examination. Patients with other causes of painful loss of motion were excluded from the study. Disorders of A-C joint & biceps tendon were excluded when patients had palpable tenderness. Arthritis and neoplasms of glenohumeral joint were ruled out on X-rays. Rotator cuff affections were ruled out by excluding the impingement signs and having normal strength. Adhesive capsulitis was defined as pain and loss of motion of shoulder of more than or equal to 25° in at least two directions (abduction, flexion, external rotation & internal rotation) when compared to contralateral shoulder. Our protocol was a two staged approach. First stage was aimed at improving the range of motion. Patients were treated with use of a specific four-direction shoulder-stretching exercise program like the pendulum stretch, towel stretch, finger walk, cross body stretch and armpit stretch. When the patient improved in range of motion, the second stage was initiated this included strengthening exercises like internal rotation and external rotation against resistance of rubber bands.

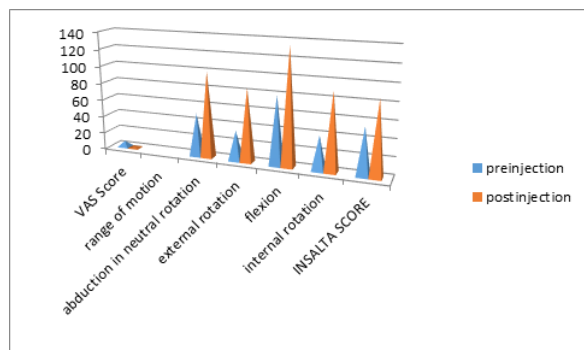


Fig. 1: Pre injection and post injection status with reference to VAS, ROM, L- Insalata shoulder function score

Before the injections, patients were assessed for pain score on VAS, ROM both active and passive was noted & shoulder rating score using L` Insalata et al.⁽²⁰⁾ was also noted. There are many scoring stems available for assessment of shoulder function but none of these is considered as a gold standard.⁽²¹⁾ We preferred L`Insalata score. The procedure was carried out in OPD under strict aseptic precautions. Random blood sugar level test was done in all patients. The blind technique by using palpatory method and posterior approach was used. A 20 FG spinal needle was used to inject 2ml of methyl prednisolone (20mg/ml) and 5ml of 2% xylocaine. Pain relief and improvement in ROM, about an hour after injection confirmed the intraarticular placement of the needle. After injection, all the patients were referred to physiotherapy department, where they were taught simple exercises which patients continued at home.

Inclusion criteria: 1) Patients more than 18 years of age. 2) Duration of symptoms of one or more than one month. 3) Patients with diabetes were also included. Exclusion criteria: 1) when adhesive capsulitis was due to known causes (Degenerative, metabolic, CVA, fracture). 2) patients with pain in both shoulders.

The patients were followed up at intervals of 3 wks, 6wks, 9 wks, 12 wks & 24 weeks. Recovery was defined when the patient achieved a range of motion within 15* of contralateral side. The recovery time was noted in each patient. On final follow up, pain rating on VAS, ROM & score on L`Insalata shoulder rating questionnaire was noted.

Results

We had included 50 patients in this study. Eight (16%) patients were lost to follow up. There were 21 (42%) males & 29 (58 %) females. The dominant side was affected in 34 (68%) patients. There were 11 (22%) diabetic patients. Four patients (8%) required second injection which was given after one week. The average pre injection VAS pain score was 7, which improved to 2 at the time of final follow up. The average range of motion also improved (Fig. 1). Abduction in neutral

rotation improved from 50 * to 100*, external rotation improved from 35* to 85*, flexion improved from 80* to 135* & internal rotation improved from 40* to 90*. The average score at final follow up using L` Insalata shoulder rating questionnaire improved from 55 to 86 (range 45 -100). The average time to recovery was 14.2 weeks, in 12 (24%) patients there was failure to recovery (Fig. 2). These 12 patients were given the option of arthroscopic capsular release and hydrodilatation. Seven (14%) patients opted for hydrodilatation, three (6%) opted for arthroscopic capsular release while two (4%) patients refused any further intervention. The patients who opted for arthroscopic capsular release were referred to shoulder surgeons. We did hydrodilatation in 7 patients under ultrasonographic control.

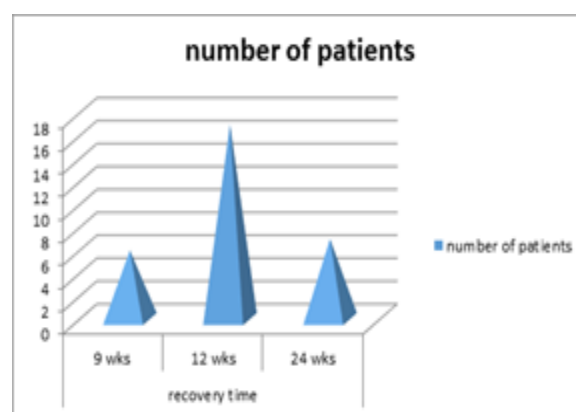


Fig. 2: Number of patients and recovery time

Discussion

The incidence of adhesive capsulitis is 3% in general population.⁽²²⁾ An inflammatory synovitis coupled with contraction of joint capsule & its adherence to the head of the humerus causes this condition.^(1,2,11,13,23) Some authors have noted that pain & decreased range of motion can last for 1 to 2 years^(9,11,12,13) while others have noted persistence beyond 3 years in their long term follow ups.⁽⁵⁻²³⁾

Jacobs et al.⁽²⁴⁾ compared the results of intraarticular corticosteroids for adhesive capsulitis with manipulation alone and they recommended the use of intraarticular steroids for the treatment of adhesive capsulitis.

Simon et al.⁽²⁵⁾ compared results of intraarticular steroids, supervised physiotherapy & a combination of the intraarticular steroids & supervised physiotherapy. They found that single intraarticular injection combined with simple home exercise programme was effective in treating the condition. They further concluded that supervised physiotherapy when used alone is less effective in the management of adhesive capsulitis.

Griggs SM et al.⁽²⁶⁾ presented the results of specific four direction shoulder stretching programme & concluded that majority of the patients can be successfully treated with the stretching exercises, however their patients had measurable limitations and

deficiencies. The pre-stretching condition of the patient in pain & ROM loss had an effect on the final outcome of the patient. Interventions like manipulation under anaesthesia and a surgical capsular release were rarely required.

S Arsalan & Reyhan Celiker.⁽²⁷⁾ compared the results of local corticosteroid injection and physical therapy for the treatment of adhesive capsulitis and found both modalities to be equally effective. However they had a very small sample size comprising of 10 patients in each group. Lee HJ et al.⁽²⁸⁾ reported that use of ultrasound as a guide to place the needle in the joint improves the results of corticosteroid therapy

Over the years it is assumed by the orthopaedic surgeons that non-operative treatment for this condition is successful if the patients are followed for long durations. Shaffer et al.⁽⁵⁾ in their long term follow up study found that 50% patients did not recover and complained of pain or stiffness or both. The time to recovery in their study was relatively long (mean –1 year). A review of literature indicates that there are multiple ways of treating the condition & combination of intraarticular steroid with home exercise programme can give better results. The approach is simple, cost effective & does not have major associated risks. Further this can be carried out as an OPD procedure, without the need of any special equipment.

The mean recovery time was 14.2 weeks with a median of 12 weeks (range 6-24 weeks). These values appear to be affected by the time interval at which we followed the patients. Some patients might have recovered before 12 weeks. The recovery time also appears to be affected by the duration of the symptoms prior to initiation of the treatment. The patients with lesser duration of symptoms recovered early as compared to patients with longer duration of symptoms.

Conclusion

The method is effective in treatment of adhesive capsulitis of shoulder. The method is safe, cost effective & does not have any major risks. Most of the patients will recover with this simple method. With refinement in technique like use of ultrasound the results can be improved. This method has a place as first line of treatment in adhesive capsulitis.

References

1. Neviaser JS. Adhesive capsulitis of shoulder: a study of the pathologic findings in peri-arthritis of the shoulder. *J Bone Joint Surg.* 1945;27:211-222.
2. McLaughlin HL. On the frozen shoulder. *Bull Hosp Joint Dis.* 1951;12(2):383-393.
3. Miller MD, Wirth MA, Rockwood CA Jr (1996) Thawing the frozen shoulder: the "patient" patient. *Orthopedics* 19(10):849– 853.
4. O'Kane JW, Jackins S, Sidles JA, Smith KL, Matsen FA III (1999) .Simple home program for frozen shoulder to improve patients assessment of shoulder function and health status. *J Am Board Fam Pract* 12(4):270–277.
5. Shaffer B, Tibone JE, Kerlan RK (1992) Frozen shoulder. A long-term follow-up. *J Bone Joint Surg Am* 74(5):738–746.
6. Placzek JD, Roubal PJ, Freeman DC, Kulig K, Nasser S, Pagett BT (1998) Long-term effectiveness of translational manipulation for adhesive capsulitis. *Clin Orthop* 356:181–191.
7. Owens-Burkhart H (1991) Management of frozen shoulder. In: Donatelli R (ed) *Physical therapy of the shoulder.* Churchill Livingstone, New York, pp 91–116.
8. Van der Windt DA, van der Heijden GJ, Scholten RJ, Koes BW, Bouter LM. The efficacy of non-steroidal anti-inflammatory drugs (NSAIDs) for shoulder complaints. A systemic review. *J ClinEpidemiol.* 1995;48(5):691-704.
9. Buchbinder R, Green S, Youd JM, Johnston RV, Oral steroids for adhesive capsulitis. *Cochrane Database Syst Rev.* 2006;(4):CD006189.
10. Binder AI, Bulgen DY, Hazleman BL, Roberts S (1984) Frozen shoulder: a long-term prospective study. *Ann Rheum Dis* 43(3):361–364.
11. Carette S, Moffet H, Tardif J, et al. Intraarticular corticosteroids, supervised physiotherapy, or a combination of the two in the treatment of adhesive capsulitis of the shoulder: a placebo controlled trial. *Arthritis Rheum.* 2003;48(3):829-838.
12. Aroll B, Goodyear-Smith F. Corticosteroid injections for painful shoulder: a meta-analysis. *Br J Gen Pract.* 2005;55(512):224-228.
13. Loblach O, Anagnostakos K, Scherf C, Seil R, Kohn D, Pape D. Non operative management of adhesive capsulitis of the shoulder: oral cortisone application versus intraarticular cortisone injections. *J Shoulder Elbow Surg.* 2010;19(2):172-179.
14. de Jong BA, Dahmen R, Hogeweg JA, Marti RK (1998) Intraarticular triamcinolone acetonide injection in patients with capsulitis of the shoulder: a comparative study of two dose regimens. *Clin Rehabil* 12(3):211–215.
15. Marx RG, Malizia RW, Kenter K, Wickiewicz TL, Hannafin JA. Intra-articular Corticosteroid Injection for the Treatment of Idiopathic Adhesive Capsulitis of the Shoulder. *HSS J* 2007;3:202-7.
16. Kivimaki J, Pohojolinen T, Malmivaara A, et al. Manipulation under anaesthesia with home exercises versus home exercises alone in the treatment frozen shoulder: a randomized controlled trial with 125 patients. *J Shoulder Elbow Surg.* 2007;16(6):722-726.
17. Helbig B, Wagner P, Dohler R (1983) Mobilization of frozen shoulder under general anaesthesia. *Acta Orthop Belg* 49(1– 2):267–274.
18. Chen J, Chen S, Li Y, Li H. Is the extended release of the inferior glenohumeral ligament necessary for frozen shoulder? *Arthroscopy* 2010;26(4)529-535.
19. Ogilvie-Harris DJ, Biggs DJ, Fitsialos DP, MacKay M (1995) The resistant frozen shoulder. Manipulation versus arthroscopic release. *Clin Orthop* 319:238–248.
20. L'Insalata JC, Warren RF, Cohen SB, Altchek DW, Peterson MG (1997) A self-administered questionnaire for assessment of symptoms and function of the shoulder. *J Bone Joint Surg Am* 79(5):738–748.
21. Felix Angst, Hans Karper Schwyzer, Andre Aeschlimann, Bear Rsimmen, Jorg Goldhahn. Measures of adult shoulder function: Disabilities of the Arm, Shoulder, and Hand Questionnaire (DASH) and Its Short Version (Quick DASH), Shoulder Pain and Disability Index (SPADI), American Shoulder and Elbow Surgeons (ASES) Society Standardized Shoulder Assessment Form, Constant (Murley) Score (CS), Simple Shoulder Test (SST), Oxford Shoulder Score (OSS), Shoulder Disability Questionnaire

- (SDQ), and Western Ontario Shoulder Instability Index (WOSI); Arthritis care and research; Volume 63, Issue Supplement S11; November 2011 ;S174-S1
22. Anthony Ewald. Adhesive capsulitis: A Review. *Am Fam Physician* .2011 Feb 15;83(4):417-422.
 23. Hand C, Clipsham K, Rees JL, Carr AJ. Long term outcome of frozen shoulder. *J Shoulder Elbow Surg*.2008;17(2)231-236.
 24. Jacobs LG, Smith MG, Khan SA, Smith K, Joshi M. Manipulation or intraarticular steroids in the management of adhesive capsulitis of the shoulder? A prospective randomized trial. *J Shoulder Elbow Surg*.2009;18(3):348-353.
 25. Simon Carette, Helene Moffet, Johanne Tardiff, Louis Bessette, Carter Thorne, Mary Bell, William Bensen, Katy Blanchette. Intraarticular corticosteroids, supervised physiotherapy or a combination of the two in the treatment of adhesive capsulitis of the shoulder. *Arthritis & Rheumatism: A placebo controlled trial*; 2003;48(3):829-838.
 26. Griggs SM, Anthony Ahn, Andrew Green. Idiopathic adhesive capsulitis, a prospective functional outcome study of non-operative treatment. *J Bone Joint Surg Am* 2000 Oct; 82(10):1398-1398.
 27. Arslan S, Reyhan Celiker. Comparison of the efficacy of the local corticosteroid injection and physical therapy for the treatment of adhesive capsulitis. *Rheumatol Int* (2001)21;20-23
 28. Lee HJ, Lim KB, Kim DY, Lee KT. Randomised controlled trial for efficacy of intraarticular injection for adhesive capsulitis: ultrasonography guided versus blind technique. *Arch Phys Med Rehab* 2009;1997-2002.