

## Lumbar pyogenic spondylodiscitis operated with posterior instrumentation, interbody debridement and fusion

Ravikumar TV<sup>1</sup>, Mahesh M<sup>2</sup>, Vinay Jain K<sup>3,\*</sup>, Sathish Kumar<sup>4</sup>

<sup>1,2</sup>Assistant Professor, <sup>3,4</sup>Junior Resident, Dept. of Orthopaedics, MS Ramaiah Medical College, Bangalore

**\*Corresponding Author:**

Email: drvinayjj@gmail.com

### Abstract

**Study design:** A prospective study in single-institution, single-surgeon review.

**Objective:** To analyze the outcome of posterior instrumentation and interbody debridement and fusion in managing lumbar pyogenic spondylodiscitis.

**Summary of Background Data:** Several management methods for pyogenic spondylitis have been reported, of which posterior surgical treatment with pedicle screws and debridement and decompression is one of the common methods of management with short and long segment stabilization. There are limited reports regarding the efficacy of posterior only approach with pedicle screw instrumentation involving the inflamed segments.

**Methods:** 32 patients with lumbar pyogenic spondylodiscitis who underwent posterior decompression and lumbar interbody fusion with bone graft and pedicle screw instrumentation including the affected segment and a level above and below were included. Postoperative recovery of neurology, ambulation and back ache score were examined for a period of 12 month. Serological infection control, radiological fusion and spinal alignment were investigated in the two monthly follow up.

**Results:** In all 32 patients successful treatment was achieved without any recurrence or spread of infection. Erythrocyte sedimentation rate and C-reactive protein levels were seen normalized with an average of 75 days and 30 days respectively. On an average ambulation with brace was started at 2.5 days following surgery. Radiological signs of interbody fusion were noted in all the cases at a mean of 5.2 months. Average of the spinal alignment of the fixed segments became 2 degree of preop lordosis was achieved to 10 degree of postop lordosis and was maintained in the 12 months follow up. None of the patients had any signs of implant loosening or failure.

**Conclusion:** Debridement and interbody fusion with bone graft and posterior instrumentation of the affected segment and a level above and below is an effective method and achieves good clinical outcome and maintenance of radiological spinal alignment in lumbar pyogenic spondylodiscitis.

**Keywords:** Early ambulation, Lumbar pyogenic spondylodiscitis, Maintenance, Spinal alignment, Instrumentation, Solid fusion.

### Introduction

Pyogenic spondylodiscitis is still a challenging medical problem, which not only involves difficulty in early diagnosis due to its non-specific presentation and the controversial decision in selection of the patients for surgical treatment. Though the mortality and morbidity rate in spondylodiscitis have decreased in last decade due to the advent of better imaging modality and its access, and the use of antibiotics. Most of the patients though can be managed conservatively with prolonged antibiotics, a small group of patients still experience progressive biomechanical instability, epidural abscess and neurological deficits for which mandates surgical intervention.

An anterior approach has an advantage by direct access to the lesion, better debridement and bone grafting, but usually requires prolonged bed rest and increased chances of kyphotic deformity. Although posterior instrumentation is regarded inappropriate in presence of infection, it provides good spinal stability, and recent studies have also shown that spinal stability is very important for suppression and eventual elimination of infection.<sup>(1)</sup>

There are limited reports regarding the efficacy of posterior only approach with pedicle screw

instrumentation involving the inflamed segments, hence the study conducted.

### Materials and Methods

32 patients with lumbar pyogenic spondylodiscitis who underwent posterior decompression and lumbar interbody fusion with bone graft and pedicle screw instrumentation including the affected segment and a level above and below were included. The study was conducted between Jan 2011 to Dec 2015, with all the patients operated in the same institute and by the same group of surgeons. All the patients were diagnosed based on clinical history, physiological and neurological examination, blood parameters and magnetic imaging resonance (MRI).

Indications for surgery included, patients presenting with sepsis, significant bone involvement with instability, impending or current deformities, intraspinal space-occupying processes (i.e. spinal abscess), failure to respond to conservative therapy and uncontrollable pain. Patients with prior history of spine surgery, pott's spine and history of any trauma were excluded from the study. Patients with malignancy, long-term steroid use, and immunosuppressive therapy

and HIV infection were considered immunocompromised.

Back pain and quality of life were evaluated using Visual Analog Scale (0 – no pain, 10 - worst pain imaginable), and the Oswestry Disability Index (ODI).

British Medical Research Council grading system was used for motor evaluation (0-no contraction, 1-flicker/trace contraction, 2-active movement with gravity eliminated, 3- active movement against gravity, 4- active movement against resistance, 5-normal/full power) and sensory evaluation was done based on the dermatomal distribution.

The mean age of the patients was 36 years (range, 22-68 years), Table 1. Minimum follow up of patients was for about 2 years; with mean follow up period was 35 months (range 24-46 months). Mean ESR was 54.84 and CRP was 6.61.

The level of vertebral body involvement, presence of an epidural abscess, or a psoas abscess was assessed on MRI, Fig. 1. With 12 patients had got 2 disc level involvement and 3 patients had got 3 disc level involvement.

Epidural abscess was observed in 27 among 32 patients. In most patients, it was seen within the infected segment (one disc and two adjacent bodies), Fig. 1 and 2. However, 7 patients had farther extension of epidural abscess over adjacent, intact disc.

Psoas abscess was identified in 12 patients, with unilateral in 8 patients and bilateral in 4 cases.

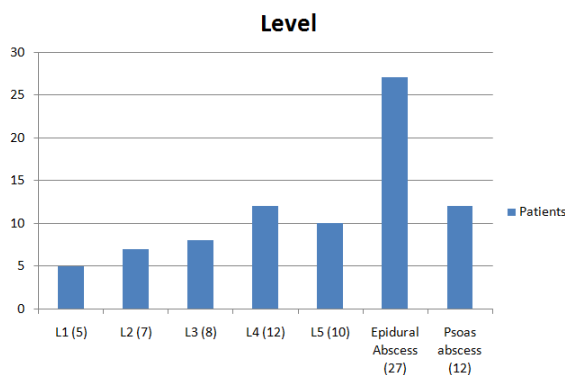


Fig. 1: Level of vertebral involvement

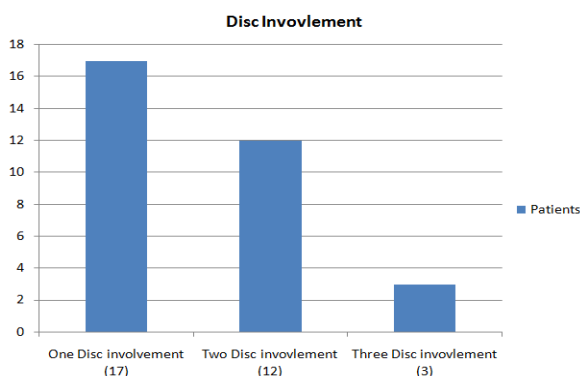


Fig. 2: Number of disc involvement

**Surgical Procedures**

All patients included in the study underwent adequate drainage/debridement of the infected level followed by a stable pedicle screw fixation and interbody bone grafting harvested from the iliac crestor laminectomy. All the procedures were performed by the same surgical team.

According to the antibiotic sensitivity of the bacteria, appropriate antibiotics were injected intravenously for the first two weeks followed by oral antibiotics for next 8 weeks. Based on the ESR and CRP, the duration of antibiotics was prolonged if required. In patients where no organism was cultured were given linezolid for 10 weeks. All patients from postoperative day two were mobilised as tolerated with lumbosacral orthosis (LSO), which was maintained for a period of minimum 3 months, followed by based on the improvement of the patients.

**Clinical and radiological assessment**

Infection Control was assessed periodically by using ESR and CRP values, which done on outpatient basis at first month and later two monthly intervals and compared to the preoperative value. Initiation date of ambulation after surgery and occurrence of any postoperative complications were reviewed.

Lateral plain radiographs were used to measure the changes in the sagittal alignment of the fixed segment before surgery, immediate postoperatively and after 12 months follow up. In 18 patients the fixed segments were same as the involved segments and in 14 patient’s additional fixation of the segments were required. The Cobb angle, the angle between two lines drawn to the superior endplate of the superior vertebral body and the inferior endplate of the inferior vertebral body, was used to assess the sagittal alignment.

Fusion was assessed based on the presence of bridging trabeculae between the bone graft and the adjacent vertebral bodies on the lateral views by two radiologists who were independent of surgeries.

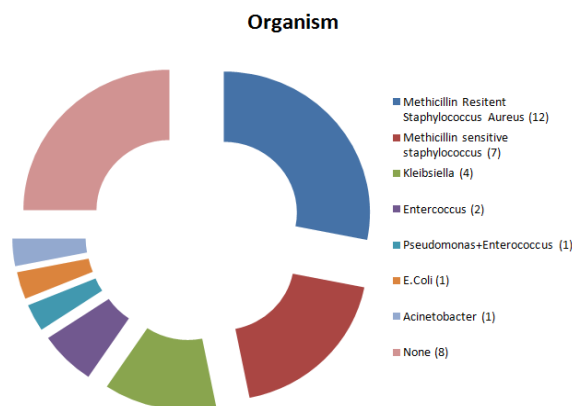
Table 1: Patient Characteristic

Characteristic	Statistics
Number	32
Males : Females	22 : 10
Age	50 (18-70yrs) – 47
-18-40yrs	6
-40-60yrs	18
->60yrs	8
Comorbidities	
-Hypertension	7
-Diabetes	11
-Chronic Kidney disease	2
-Immunocompromised	3
Presenting symptoms	
-Back pain alone	11

-Back pain with radiculopathy	21
Duration of symptoms, days	180 (10-450)
Lower Limb weakness	14
Lower Limb Numbness	23
Bowel and Bladder incontinence	0
Preoperative VAS	7.93 (6-9)
Laboratory data	
-WBC (cells/cu.mm)	9495 (5300-15320)
-ESR (mm/hr)	54.84 (39-140)
-CRP (mg/dL)	6.61 (4.8-10.5)

**Results**

Causative microorganism was identified in 23 (71.87%) patients, Fig. 3. Antibiotics were given for a mean duration of 14 weeks (range, 12-22 weeks).



**Fig. 3: Organism cultured**

Erythrocyte sedimentation rate and C-reactive protein levels were seen normalized with an average of 75 days (range, 60-120days) and 30 days (range, 24-55 days) respectively. CRP levels were back to normal levels earlier than ESR in almost all cases. With regard to the presence or absence of epidural abscess, psoas abscess, there was no significant difference in the mean times taken for the ESR and CRP to become normal.

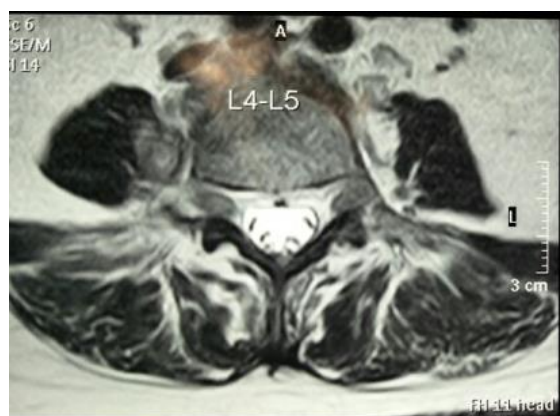
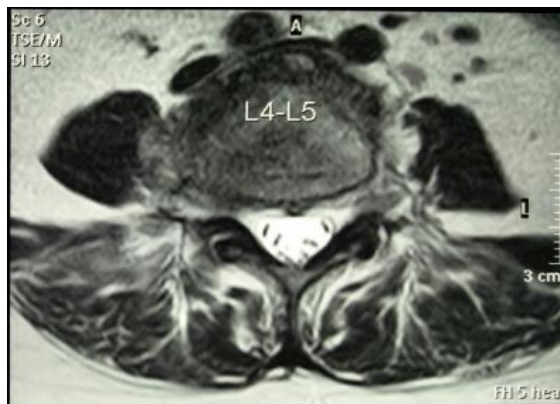
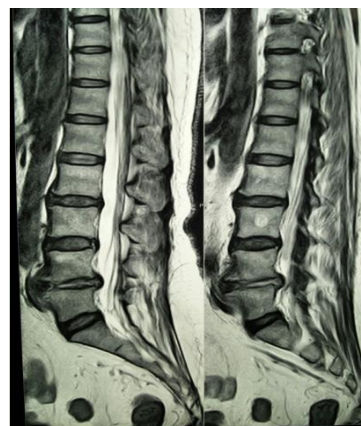Ambulation in an orthosis was started at a mean of 2.5 postoperative days (range, 2–11 days). No difference was observed in patients with or without abscess, in respect to the postoperative day of ambulation. No recurrence of infection or occurrence of complications such as instrument breakage was noted.

Out of the 14 (43.75%) patients presenting with neurological deficits 2 worsened and on follow up both patients improved neurologically which was attributed to neuropraxia at the time of decompression in the index surgery.

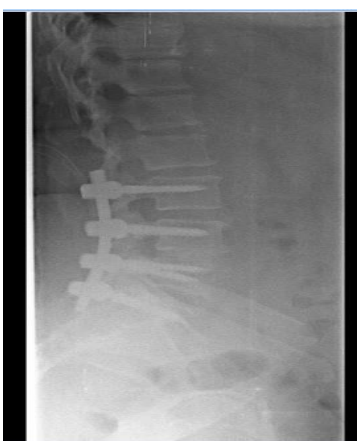
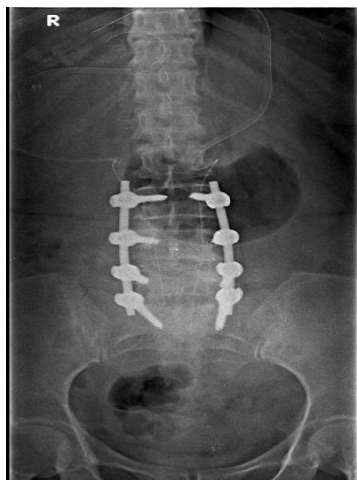
Radiological signs of interbody fusion were noted in all the cases at a mean of 5.2 months (range, 3-7

months). Radiological fusion occurred after 6 months in 50% of the patients, and after 12 months in 80% of the patients. After 18 months fusion was seen in 100% of the patients.

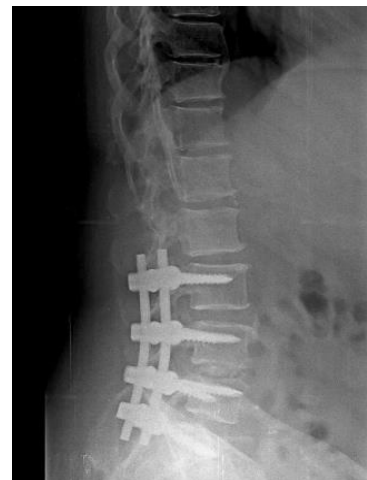
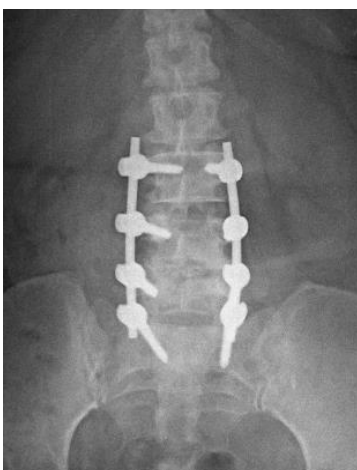The back pain was reduced in 87.5% within 7 days and 100% of the patients within 3 months of the index surgery. The mean VAS improved from 7.93 (range: 5-10) preoperatively to 2.20 (range: 0-4). The mean preoperative ODI improved from 79% (range: 55%-87%) to 32.7% (range: 16%-47%).



**Fig. 4: Case: Imaging studies obtained in a 54-year-old man with pyogenic spondylodiscitis of the L4–5 intervertebral disc space. Preoperative MR imaging shows destruction of the endplate with abscess**



**Fig. 5: Postoperative antero-posterior (left) and lateral radio-graph (right) following single-stage posterior debridement plus interbody grafting at L4-L5 level with autologous bone, and transpedicular screw-rod instrumentation**



**Fig. 6: Antero-posterior (left) and lateral (right) radiograph showing evidence of bone fusion L4-L5 level 6 months follow-up**

### Discussion

Most spine surgeons prefer anterior surgery with radical debridement, fusion with autogenous grafts and anterior or posterior instrumentation correcting any sagittal deformity,<sup>(2-4)</sup> as the approach allows direct access to the infected focus. It is generally accepted that all foreign materials may decrease the effectiveness of the antibiotics. They facilitate biofilm formation and bacterial adherence, a condition not readily recognizable for the immune system, and hampering the penetration of antibiotics.<sup>(5)</sup> But studies have suggested that instrumentation is safe and efficacious, after thorough and radical debridement. And the use of titanium implants also reduces the chances of biofilm formation, and decrease bacterial adherence. Surgeons usually do not prefer to debride and instrument in the single stage because residual bacteria might lead to persistence of infection. A single-stage procedure has several advantages such as avoidance of a second anaesthesia, shorter hospital stay, and lower complication rate and earlier mobilization. In the current study we have performed single stage posterior laminectomy and debridement of the infected segment, followed by posterior stabilization by pedicle screw-rod systems providing rigid segmental fixation along all the three columns of the spine along with bone grafting with titanium based implants which was used in all our patients. There is no clear consensus on whether the placement of screws in the infected vertebrae versus long instrumentation to the uncontaminated level, gives results in terms of infection control, chance of spreading the infection, loosening of implant, correction and maintenance of kyphotic correction.

Patients who presented with epidural abscess or psoas abscess, also showed good results in terms of clinical outcome and haematological values, with single stage procedure.

We saw no recurrence of infection after an average follow-up of 24 months. Implant failure was not seen in any patient. The fusion rate was 100% in our study. The findings of which were similar in other studies after single stage surgery, with fusion rate of 94% to 100%.<sup>(4,6,7)</sup> Reliable fusion promotes control of infection and early return to normal activities. Quality of life assessed with the VAS and ODI score showed significant improvement.

In view of the evaluation of the change of sagittal alignment with posterior instrumentation alone, our results were comparable with those studies which included combined anterior and posterior approach.<sup>(7,8,9,12)</sup>

Lee et al,<sup>(12)</sup> reported that maintenance of kyphosis correction with only 1.8 deg of kyphotic angle loss at the final follow up from the postoperative state could be obtained (through posterior lumbar interbody fusion and pedicle screw fixation in pyogenic discitis). Similar to this study, the average kyphotic angle loss was only 1.1deg at the 12 month follow up with successful fusion and complete recovery without recurrence of infection.

Continuous use of antibiotics before and after the surgery with thorough debridement of the involved segment with drainage of the abscess is essential for the management of pyogenic spondylodiscitis via posterior approaches.

## Conclusion

Debridement and interbody fusion with bone graft and posterior instrumentation of the affected segment and a level above and below is an effective method and achieves good clinical outcome and maintenance of radiological spinal alignment in lumbar pyogenic spondylodiscitis. The culprit for the recurrence of infection is not the implants itself, but is the compromised general health condition of the patients. There should not be hesitation to instrument in any spondylodiscitis necessitating the surgical procedure with due consideration of adequate debridement and stable spinal stabilization.

## References

1. Wei-Hua Chen, Lei-Sheng Jiang, Li-Yang Dai. Surgical treatment of pyogenic vertebral osteomyelitis with spinal instrumentation. *Eur Spine J* (2007) 16:1307–1316.

2. Hadjipavlou AG, Mader JT, Necessary JT, et al. Haematogenous pyogenic spinal infections and their surgical management. *Spine* 2000;25:1668-1679.
3. Ozalay M, Sahin O, Derincek A et al. Non-tuberculous thoracic and lumbar spondylodiscitis: single-stage anterior debridement and reconstruction, combined with posterior instrumentation and grafting. *Acta Orthop Belg* 2010;76:100-106.
4. Kuklo TR, Potter BK, Bell RS, et al. Single-stage treatment of pyogenic spinal infection with titanium mesh cages. *J Spinal Disord Tech* 2006;19:376-382.
5. Korovessis P, Repantis T, Iliopoulos P, et al. Beneficial influence of titanium mesh cage on infection healing and spinal reconstruction in hematogenous septic spondylitis: a retrospective analysis of surgical outcome of twenty-five consecutive cases and review of literature. *Spine* 2008;33:E759-767.
6. Gonzalvo A, Abdulla I, Riaz A, et al. Single-level/single-stage debridement and posterior instrumented fusion in the treatment of spontaneous pyogenic osteomyelitis/discitis: long-term functional outcome and health-related quality of life. *J Spinal Disord Tech* 2011;24:110-115.
7. Przybylski GJ, Sharan AD. Single-stage autogenous bone grafting and internal fixation in the surgical management of pyogenic discitis and vertebral osteomyelitis. *J Neurosurg* 2001;94:(1 suppl) 1-7.
8. Klo Ckner C, Valencia R. Sagittal alignment after anterior debridement and fusion with or without additional posterior instrumentation in the treatment of pyogenic and tuberculous spondylodiscitis. *Spine* 2003;28:1036-42.
9. Deininger MH, Unfried MI, Vougioukas VI, et al. Minimally invasive dorsal percutaneous spondylodesis for the treatment of adult pyogenic spondylodiscitis. *Acta Neurochir (Wien)* 2009;151:1451–7.
10. Ahmed S. Mohamed, Jung Yoo, Robert Har t, et al. Posterior fixation without debridement for vertebral body osteomyelitis and discitis. *Neurosurg Focus* 37(2):E6,2014.
11. Kuklo TR, Potter BK, Bell RS, et al. Single-stage treatment of pyogenic spinal infection with titanium mesh cages. *J Spinal Disord Tech* 2006;19:376–82.
12. Lee JS, Suh KT. Posterior lumbar interbody fusion with an autogenous iliac crest bone graft in the treatment of pyogenic spondylodiscitis. *J Bone Joint Surg Br* 2006;88:765–70.
13. Yong-Min Kim, Seung-Myung Choi. Posterior Only Approach for Lumbar Pyogenic Spondylitis with Short Instrumentation and Prolonged Suction Drainage. *SPINE* Volume 41, Number 17, pp E1022–E1029.
14. Leopold Arko, Eric Quach, Vincent Nguyen, et al. Medical and surgical management of spinal epidural abscess: a systematic review. *Neurosurg Focus* 37(2):E4,2014.