

## Radiological assessment of the outcome and complications of uncemented revision total hip arthroplasty in failed primary hemiarthroplasty

Chidanand R. Metri<sup>1,\*</sup>, Pavankumar H. Patil<sup>2</sup>

<sup>1</sup>Senior Orthopedic Consultant, Metri Hospital, Bijapur, Karnataka, <sup>2</sup>Assistant Professor, Dr. BR Ambedkar Medical College, Bengaluru, Karnataka

**\*Corresponding Author:**

Email: drmetrichidanad@gmail.com

### Abstract

**Introduction:** Uncemented revision total hip arthroplasty is the procedure of choice for the patients with failed hemiarthroplasty providing pain relief, preservation of mobility, range of motion and easy rehabilitation. In the present study, radiologically assessed the outcome and complications of uncemented Total Hip Arthroplasty in failed primary hemiarthroplasty.

**Methods:** Radiographs of the pelvis with both hips with proximal half of shaft of femora – AP View and lateral view of the involved side was taken for all patients. The radiograph was evaluated for Loosening of the prosthesis, Calcar resorption, Cortical hypertrophy, Periprosthetic fracture, Acetabular index, Bone stock of the acetabulum, Need for bone grafting and Size of the femoral canal.

**Statistical Analysis:** Student's paired t-test was used to find out the significance of difference between pre-operative and post-operative Harris Hip scores.

**Results:** The Acetabular Inclination Angle was found to be 40-60 degrees in 66.67% cases, one case with less than 35 degrees. In unilateral cases offset is compared with the opposite side. Centre of rotation almost restored in majority of cases (90%). Post operative radiological complications are very few. The incidence of fractures ranges from 0.1 to 1.0 percent for cemented components and 3 to 18 percent for uncemented components.

**Conclusion:** The modular series of uncemented total hip prosthesis is the implant of choice for uncemented revision total hip arthroplasty as it provides stability and ingrowth, as well as the ability to control leg length, offset and version.

**Keywords:** Radiological Assessment, Total Hip Arthroplasty, Failed Primary Hemiarthroplasty, Acetabular Inclination Angle.

### Introduction

Modern hip replacement has resulted in huge benefit for patients with arthritic hip disease, providing them with reduction of pain, return of function and consequently an improved quality of life. There is evidence of increased longevity, twenty years or more with some total joint replacements, but many of these mechanical joints fail after fifteen years when the hip joint loosens, because increasing numbers of hemiarthroplasties have been done over the past three decades, and the operation is being performed in elderly and active patients, the number of revision procedures has increased dramatically.<sup>(1)</sup>

Revision total hip arthroplasty usually is much more difficult and requires much more operative time, there is increased blood loss, and the incidences of infection, thromboembolism, dislocation, nerve palsy and fracture of the femur are higher. The complexities of revision surgery underscore the importance of technical precision. The discouraging results of cemented revisions, coupled with satisfactory early results of cementless primary surgery have led many surgeons to abandon cement in many revision surgeries.<sup>(1,2)</sup> The burden of revision total hip arthroplasty done in the United States has been approximately 17.5% based on an analysis of hospital discharge data from 1990 to 2003. Projections based on these data estimate that the volume of revision total hip

arthroplasty will increase to nearly 70,000 cases by 2020 and almost 100,000 by 2030.<sup>(3,4)</sup>

In complex revision total hip arthroplasties, extended slide trochanteric osteotomy may be necessary to achieve adequate exposure with preservation of the gluteus medius and minimus and vastus lateralis attachments on the osteotomized bone allowing excellent removal of cement and components, optimal implantation of the revision component and reliable healing. Healing after the revision hip arthroplasties with an extended slide trochanteric osteotomy is excellent. In contrast to a conventional trochanteric osteotomy, the extended slide trochanteric osteotomy preserves the blood supply from the anterior soft tissue and the vastus lateralis muscle while providing a large surface area for reattachment. The effect of these factors may contribute to the high union rate associated with the extended slide trochanteric osteotomy.<sup>(5-8)</sup>

### Materials and Methodology

The study was carried out on 12 patients of revision total hip arthroplasty operated in our institute. This is a prospective as well as retrospective study. Information on the patients was compiled from clinical details, case files and from operation theatre records. Patient follow up was for a minimum of 6 weeks to maximum of 24 months.

Patients with failed primary hemiarthroplasty with Unipolar or Bipolar prosthesis (cemented and

uncemented) due to Aseptic loosening, Protrusion causing groin pain, Dislocation, Breakage of implant leading to loss of function, Periprosthetic fracture and Acetabular osteolysis. Patients with total hip arthroplasty in patients with internal fixation of proximal femoral fractures and infected primary hemiarthroplasty (cemented or uncemented) were excluded.

**Radiological Assessment:** Radiographs of the pelvis with both hips with proximal half of shaft of femora – AP View and lateral view of the involved side was taken for all patients. The radiograph was evaluated for Loosening of the prosthesis, Calcar resorption, Cortical hypertrophy, Periprosthetic fracture, Acetabular index, Bone stock of the acetabulum, Need for bone grafting and Size of the femoral canal.

**Exposure and preparation of the Acetabulum:** Complete exposure of the acetabulum is essential in order to determine the deepest possible depth for socket placement. Steinmann pin was driven into the ilium just superior to the acetabular rim, to allow visibility of superior bony periphery. The goal is to create a cavity that will accommodate the cup in the region of the true acetabulum with maximal bony coverage. Bony margins of the rim of the acetabulum are exposed around its entire circumference to facilitate proper placement of the acetabular component. Curettage of the remnant soft tissue from the region of the pulvinar was done. The acetabulum is progressively reamed with reamers until healthy bleeding subchondral bone is reached. Using a trial cup impactor, a trial cup sizer is placed into the reamed acetabulum and assessed its position and cortical bone contact before the insertion of the acetabular component; ensure that the patient remains in true lateral position.

**Exposure and preparation of the femur:** The proximal femur was exposed markedly by internally rotating the femur so that the tibia is perpendicular to the floor, allowing the knee to drop towards the floor, pushing the femur proximally. Retract the posterior edge of the gluteus medius and minimus to expose the pyriform fossa, any remnant of the soft tissue was removed from the posterior and lateral aspect of the neck. A groove was made in the medial aspect of the greater trochanter to allow proper axial reaming of the canal.

If resistance is felt during insertion of the broach, then the area of impingement is most likely distally within the diaphysis. The distal canal was opened with a hand reamer or drill thus perforating the sclerotic bone at the tip of the loose prosthesis and utmost care was taken to avoid the tendency to go through the path of least resistance, which may have caused a cortical perforation. The canal was then prepared according to the hip system being used in a particular patient.

**Implant Insertion:** In patients where regular corail cementless stem is used, the corail pressfit femoral stem attached with neck segment of the appropriate size is

fixed into the femoral canal maintaining 15 degrees anteversion and femoral head is attached and fixed to the neck and the head of the prosthesis is reduced into the prepared acetabulum and range of motion is evaluated.

In patients where Modular multi component system is used, the stem segment, metaphyseal segment, calcar segment (if required) and neck segment of the required size was assembled, the fluted stem segment fixed to metaphyseal and neck segment using a screw maintaining required anteversion and the assembled implant was fixed into the femoral canal and femoral head of required size is attached and fixed to the neck and finally the head of the prosthesis is reduced into the prepared acetabulum.

**Post Operative Protocol:** Second post operative day, primary dressing was done and suction drain is removed and physiotherapy continued. Gradual weight bearing walk with walker was started from 3<sup>rd</sup> post op day after evaluation of post op check x-rays. In patients with trochanteric slide osteotomy of proximal femur, non weight bearing was advised for first 6 weeks, followed by partial weight bearing and gradually full weight bearing in 3-6 months depending on clinical and post operative radiological assessment of the operated hip.

In patients with split fracture of proximal femur and fracture greater trochanter occurred intraoperatively during the process of metaphyseal reaming or during reduction of the prosthesis where circumferential stainless steel wiring of proximal femur and tension band wiring of greater trochanter was done, in these cases, non weight bearing was advised for 3 weeks followed by gradual weight bearing in 6 – 12 weeks depending on the assessment of post op x-rays at regular intervals. Alternate sutures are removed on 10<sup>th</sup> post op day and complete suture removal done on 12<sup>th</sup> post op day and patients were discharged on the same day with review after 6 weeks.

The patients were followed up at 6 weeks, 3 months, 6 months, one year and at yearly intervals. Patient follow up was for a minimum of 3 months to maximum of 24 months (2 years). During each visit, medical history was taken and physical examination was done. Range of movements (ROM) was recorded. The clinical and functional outcomes were evaluated by Harris Hip Score evaluation.

**Statistical Analysis:** Student's paired t-test was used to find out the significance of difference between pre-operative and post-operative Harris Hip scores.

## Results

The Acetabular Inclination Angle in our study is between 40-60 degrees in 8 cases (66.67%), one case with less than 35 degrees. Acetabular inclination angles < 30 degrees and >60 degrees predisposes the chances of dislocation, but in our study no dislocation was noticed in any of these cases (Table 1). If the offset of

the operated side is less or more than the opposite side then the centre of rotation is altered. In unilateral cases offset is compared with the opposite side. Centre of rotation almost restored in majority of cases (90%) in our study (Table 2).

**Table 1: Number of cases at different range of acetabular angle**

Acetabular angle	No. of cases	Percentage
30-35	1	8.33
35-40	0	0
40-45	2	16.66
45-50	3	25
50-55	4	33.33
55-60	1	8.33
Total	33	100

**Table 2: Restoration of Normal Centre of Rotation of Femoral Head (Offset)**

Offset	No. of cases	Percentage
Normal	11	91.66
High	1	8.33
Low	-	-

In majority of the cases (66.67%) in our study the post operative acetabular cup angle lies between 40-60 degrees with normal femoral stem placement in 91.66% cases, and normal offset in 91% patients. Post operative radiological complications are very few. Calcar resorption was noticed in 2 cases postoperatively, and dislocation occurred in one case which was reduced by closed reduction with immobilisation for 6 weeks and later followed by gait training with no evidence of further dislocations. Heterotopic ossification in one case and none of the post operative cases got infected till the last follow-up indicating satisfactory radiological outcome in revision total hip arthroplasty. Peri acetabular osteolysis was found in 2 cases (16.66%) and peri femoral osteolysis was seen in 3 cases (25%) post-operatively represented as thin lucent zones of > 2mm at the bone-prosthesis interface (Table 3).

**Table 3: Number of patients and the Post-Operative Radiological Findings**

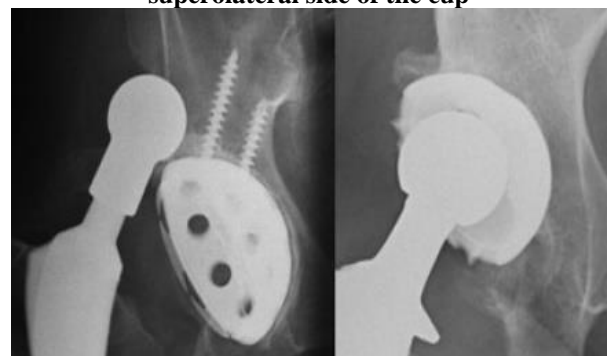
Post-op radiological findings	No. of patients	Percentage
Calcar resorption	2	16.66
Loosening	Nil	-
Dislocation	1	3.12
Infection	Nil	-
Cortical hypertrophy	Nil	-
Peri-prosthetic fracture	Nil	-
Sunken prosthesis	1	8.33
Polyethylene wear	Nil	-

Heterotopic ossification	1	3.12
Peri femoral osteolysis	3	25
Peri Acetabular osteolysis	2	16.66

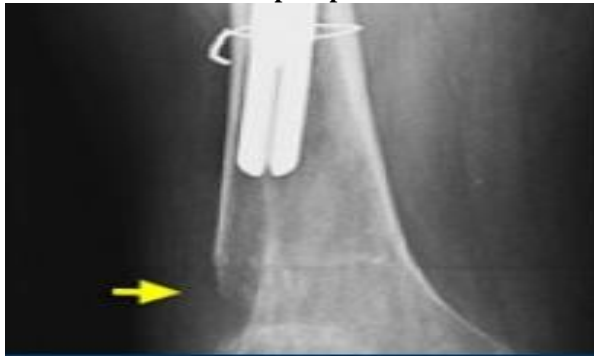Dislocation can occur as a late complication in prosthesis that is not well positioned, but it is most common in the immediate post-operative period. Due to increased forces on the superolateral margin of the cup, increased lateral inclination of the acetabular component also may increase the risk of polyethylene wear of the acetabular liner (plate-1). The incidence of fractures ranges from 0.1 to 1.0 percent for cemented components and 3 to 18 percent for uncemented components. Normal horizontal centre of rotation is shown in red line. The anteversion of the acetabular cup should be 5-25. Exact measurement of this angle on a cross-table or true lateral radiograph is not possible, since the apparent degree of angulation on a radiograph is affected by pelvic or thigh rotation (plate-4).

The most common radiographic manifestation of loosening is Lucent zone >2mm at interface (indicative) and component migration (diagnostic) (plate-5). In the same radiographs and we use the tear drop figure as a landmark, the migration becomes more evident. Migration of the cup (blue arrow) in cranial direction has resulted in a fracture in the acetabular wall (plate-6). Particle Disease is relentlessly progressive with loosening, fracture and destruction of bone. Sometimes revision of a stable total hip arthroplasty is needed because more bone loss would make revision surgery impossible (plate-7). The role of dedicated radionuclide techniques for infection such as gallium scanning or indium labeled WBC or immunoglobulin G is not clear, but they tend to be a bit more specific compared to normal Technetium bone scan (plate-8). Component fracture is probably secondary to severe polyethylene wear resulting in cup and cement fracture (plate-9).

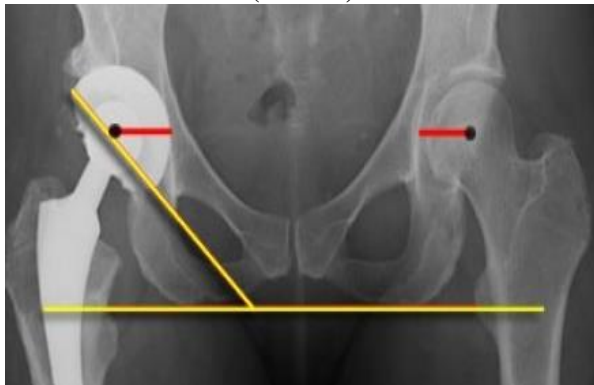
**Plate 1: Left – femoral head with large collar, dislocation due to increased lateral inclination of acetabular cup. Right – at risk for dislocation, high and lateral position of a steep acetabular cup. Notice polyethylene wear due to increased forces on the superolateral side of the cup**



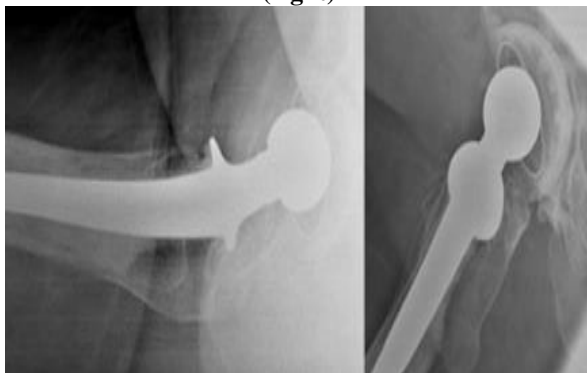**Plate 2: Revision total hip arthroplasty with a large femoral stem with peri-prosthetic fracture**



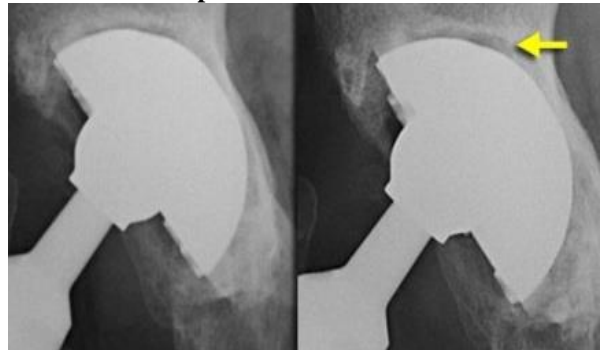
**Plate 3: Measurement of lateral acetabular inclination, right lesser trochanter is lower in position than the left indicating leg length discrepancy. Normal horizontal centre of rotation (red line)**



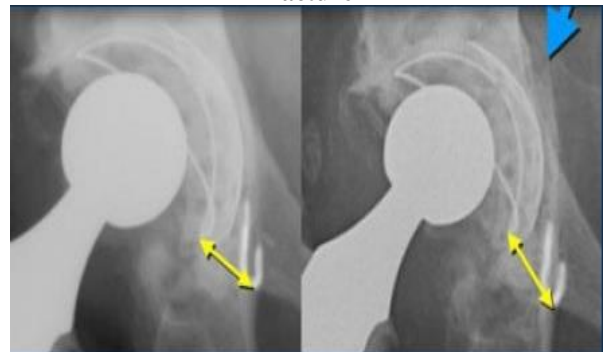**Plate 4: Different anteversion of the acetabular cup in the same patient due to different rotation on a cross table view (left) compared to a lateral view (right)**



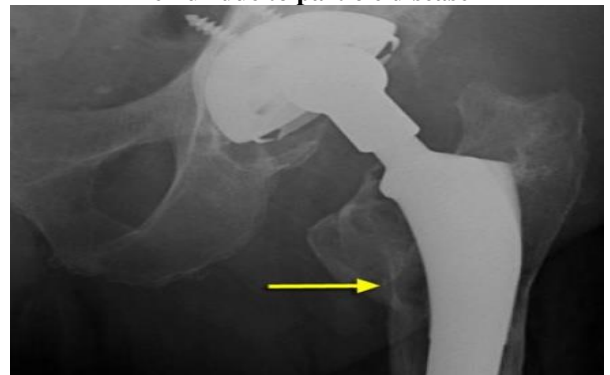**Plate 5: Progressive lucent zone around acetabular component in zone I and II**



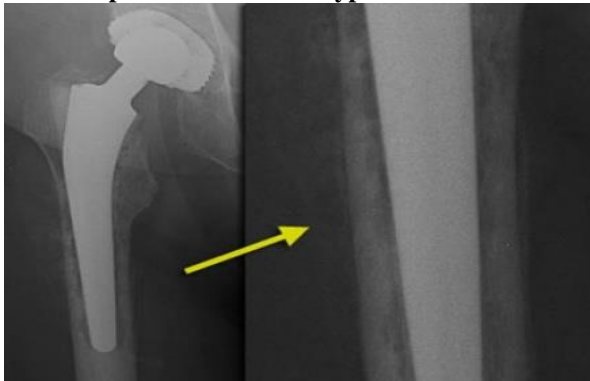
**Plate 6: Same case as above with white marks on the tear drop figure. Migration was shown by yellow arrows and blue arrow indicated acetabular fracture**



**Plate 7: Eccentric position of femoral head within cup consistent with polyethylene wear. Focal osteolysis with endosteal scalloping in proximal femur due to particle disease**



**Plate 8: Irregular periprosthetic bone resorption with periosteal reaction typical for infection**



**Plate 9: Shows severe wear and fracture of the polyethylene liner**



## Discussion

The purpose of the present study was to review the radiographic results of uncemented revision total hip arthroplasty in cases with failed hemiarthroplasty. The technique of revision was constant throughout the study period and involved the use of modular prosthesis in the majority of the patients (58.33%). It was hoped that the use of components without cement would partially eliminate the problems associated with revisions performed with cement.

Ours is a prospective and retrospective study comprising of 12 patients. The mean age of patients in the group is 59.53 years (range 50 to 80 years), which is comparable to the study done by D. J. Engelbert and his colleagues who reported the results in 134 patients mean age of 59.2 years (range 25 to 85 years).<sup>(9)</sup> The average pre operative Harris Hip score in our study is 45.25 which are similar to the pre operative average Harris Hip score in the studies done by B.D. Mulliken and his colleagues.<sup>(10)</sup> They studied 52 cementless total hip arthroplasties in 51 patients with average pre operative Harris Hip score of 46. Craig J. Della Valle<sup>(11)</sup> and his associates studied 131 patients of cementless acetabular reconstruction in revision total hip arthroplasty with average pre operative Harris Hip score of 49.

In the present study, the average pre operative Harris Hip score of 45.25 improved to 81.66 post

operatively at last follow-up. The increase in Harris Hip score is attributed to the surgical technique, type of the implant used, post operative care and physiotherapy advised to the patients. It is also comparable to the study conducted by Christopher L. Peters and his colleagues who reported improvement from 54 points preoperatively to 84 points at the time of the latest follow-up.<sup>(12)</sup>

In majority of patients in our study (58.33%), modular series of uncemented total hip replacement system was used. The modular design makes it possible to achieve independent sizing in the distal canal and proximal metaphysis. Chandler reported on the use of the S-ROM stem in 52 revisions in 48 patients followed for an average of 3 years.<sup>(13)</sup> The average Harris Hip score was 44 before revision and 84 at follow-up. 84% of patients were satisfied with the outcome which is comparable to our study.

In our study one patient (8.33%) presented with foot drop indicating neuropraxia of sciatic nerve probably caused by retraction during surgery and was not recovered till the last follow-up. The widely accepted incidence of postoperative neuropathies about the hip ranges from 0.6% to 2.9% for primary total hip arthroplasty and from 1.8% to 7.6% for revision total hip arthroplasty,<sup>(14,15)</sup> which is comparable to our study. The sciatic nerve, specifically the peroneal distribution of the sciatic nerve is involved in nearly 80% of the cases.

The reasons for different results in different patients are both patient and surgeon related. From patient's aspect pre-operative mobility with good range of movement and adequate bone stock resulted well to excellent outcome and from surgeon's aspect surgical technique, choice of implant selection with good post-op care and physiotherapy offers satisfactory outcome. The limitation in the present study is a relatively short follow-up and therefore we could not come to a conclusion about the late complications and long term results of uncemented revision total hip arthroplasty.

## Conclusions

Uncemented revision total hip arthroplasty is the procedure of choice for the patients with failed hemiarthroplasty providing pain relief, preservation of mobility, range of motion and easy rehabilitation. The complications like aseptic loosening and particle wear requiring re-revision have not been found in our study. Long term follow-up of the cases is required for the analysis of both clinical and radiological outcome.

## References

1. S.Terry Canale and James H. Arthroplasty of the hip. *Clinical Orthopaedics Related Research*. 2008;1:430-431.
2. Michael H. Huo: Disparity in revision total hip replacement: clinical outcome, cost, and surgeon work force; *Current Orthopaedic Practice* 2010;1:212-16.

3. Robert L. Buly: The S-ROM stem for revision total hip arthroplasty; techniques in orthopaedics 2001;16(3):268-278.
4. John T Dearborn and William H. Harris: Acetabular revision after failed total hip arthroplasty in patients with congenital hip dislocation and dysplasia; The Journal of Bone and Joint surgery 2000;2-A:8.
5. Pradeep Bhosle, Ashish Suryawanshi and Amber Mittal: Total hip arthroplasty for failed aseptic Austin Moore prosthesis; Indian Journal of Orthopaedics 2012;46:297-303.
6. Amite Pankaj, Rajesh Malhotra and Surya Bhan: Conversion of failed hemiarthroplasty to total hip arthroplasty: A short to mid-term follow-up study; Indian Journal of Orthopaedics, 2008;42(3):294-300.
7. Ilinas A, Sarmiento, William J: Total hip replacement after failed hemiarthroplasty or mould arthroplasty, Comparison of results with those of primary replacements; The Journal of Bone and Joint Surgery 1991;73(6):902-7.
8. Robert .K, Vladimir.T, Dubravko.O: History and factors of survival of total hip arthroplasty; Medicinski Glasnik 2012;9:0-1.
9. D.J.Engelbert, F.A.Weber, I. Jakim: Long term results of revision total hip arthroplasty; The Journal of Bone and Joint Surgery 1990;72-B: 41-5.
10. B.D Mulliken, C.H.Rorabeck and R.B.Bourne: Uncemented revision total hip arthroplasty, a 4 to 6 year review; Clinical Orthopaedics and Related Research; 1995;325:156-162.
11. Craig J. Della Valle, Richard A. Berger, Aaron G. Rosenberg, and Jorge O. Galante: Cementless acetabular reconstruction in revision total hip arthroplasty; Clin Orthop 2004;420:96-100.
12. Christopher L. Peters, Dennis P Rivero, Laura R Kull, Aaron G Rosenberg: Revision total hip arthroplasty without cement: Subsidence of proximally porous-coated femoral components; The Journal of Bone and Joint Surgery 1995;77-A: 8.
13. Chandler A, Anthony K. Hedley, Thomas A. Gruen, and David P.Ruoff: Revision of failed total hip arthroplasties with uncemented porous-coated anatomic components; Clinical Orthopaedics and Related Research 1988;2:235-40.
14. Jeffrey N. Katz, John Wright, Elizabeth A. Wright, Elena Losina: Failures of total hip replacement; A population based perspective 1998;88-A:8.
15. Wei-Ming Chen, James P.Mc Auley, Anderson Engh, Robert H Hopper and Charles A Engh: Extended slide trochanteric osteotomy for revision total hip arthroplasty; the Journal of Bone and Joint Surgery 2000;82-A:9.