

Use of bone allografts in the management of upper limb fractures and their complications – A prospective study

Darshan Kumar A. Jain¹, Harish Kodi^{2*}, Abhilash Palla³

¹Consultant, ^{2,3}Junior Resident, Dept. of Orthopedics, Ramaiah Medical College, Bengaluru, Karnataka

***Corresponding Author:**

Email: harrister@gmail.com

Abstract

Background: In comparison with the lower extremity, there is relative dearth of literature reporting clinical results of allograft in upper limb. Most studies have reported on use of allografts in upper limb reconstructions following tumour resection.

Aim: We conducted a prospective study to assess results of using bone allograft as an adjunct to internal fixation following trauma and its complications like Non-union, malunion etc. in Upper limb.

Material and Methods: We have analyzed use of allografts in upper limb in 11 patients from November 2014 to March 2016.

Results: A mean follow up of 12.3 months showed good functional results and radiological consolidation in 91% of cases. Radiological union was seen by 3 months in 8 patients and by 6 months in 2 patients. One case had non-union which required repeat bone grafting. There was no incidence of other complications or disease transmission.

Conclusion: Our study has shown promising results with allograft with radiologically good incorporation and good functional results.

Keywords: Allografts; Bone Transplantation; Prospective Study

Introduction

Allografts have been used in conjunction with bone morphogenetic protein (BMP) in nonunion with bone deficiency in the femur. Loss of a major articular component of a joint surface following trauma is fortunately rare, but in younger patients fresh allograft replacement of the joint surface may be considered as an alternative to arthroplasty.⁽¹⁾ Allografts are commonly used for tumor conditions like lytic lesions and in lower limb trauma. There are currently very few published results on use of allografts for upper limb trauma and fracture complications.

Function of the lower extremities primarily affects stance and ambulation. Function of upper extremities, however, requires coordinated function of the digits and is dependent on sensation.⁽²⁾ There are certain differences in the radiological union duration and integration into the normal architecture of the bone in upper limbs when compared to the lower limbs. We therefore wanted to study the results of allograft uptake in the upper limb.

Our study includes exclusive upper limb cases of wide spectrum including acute trauma, malunion, nonunion, deformities in which allografts were used and radiological union was assessed periodically.

Allografts offer certain advantages in comparison to autograft, which has drawbacks such as limited availability and donor site morbidity. The use of allografts in orthopaedics dates back to start of the twentieth century when Lexer transplanted allogenic hemi and whole knee joint in a living recipient.⁽³⁾ More recently Mankin have demonstrated favourable results with fresh frozen allograft.⁽⁴⁾

Its primary benefit is the reconstitution of near normal or normal osseous architecture.⁽⁵⁾ It has been shown in many instances that bulk allografts undergo slow revascularization and their structural integrity is maintained under physiological loading for a very long duration.⁽⁶⁾

It is easy to obtain and store femoral heads as bone grafts and they appear to function satisfactorily.⁽⁷⁾

A few of the problems seen using allograft bone are non-union and infection.⁽⁸⁾

A strict screening protocol for donor and for obtaining culture and biopsy during retrieval as well as during implantation of the donor bone to the recipient bed is followed which lowers the risk of infection from introducing a large segment of necrotic bone.⁽⁹⁾

Disease and resorption are some of the factors which can cause partial failure of the graft resulting in delayed consolidation as seen with bulk allografts.⁽¹⁰⁾

It is therefore of utmost importance to maintain a high standard of bone/tissue banking facility so as to facilitate a safe transplantation.

Materials & Methods

After clearance from the ethical committee, allografts have been used in 11 patients for upper limb from November 2014 to March 2016 in our institution. Of the 11 patients, 8 were males and 3 were females. Mean age was 38.18 years (13-65 years). Allografts were used in one clavicle fracture, 2 proximal humerus fractures, one humerus shaft fracture, one distal humerus, 2 radius shaft, 3 distal radius fractures and one case for correction of finger deformity. Allografts were used in 7 fresh fractures, 2 malunions, one non-union and in one case of deformity.

All the fresh fractures and non-unions were treated with plating and bone grafting. A malunited distal radius was treated with Corrective osteotomy, plating and bone grafting. One case had valgus deformity at the left middle finger PIP joint for which Osteotomy and open reduction and internal fixation with plating and allograft application was done.

Among the allografts used, 5 were TKR slices, 2 were femoral heads, one was patella and 3 were freeze dried bone allografts.

Radiological evidence of union across the fracture site or incorporation and its correlation with clinical functional index using modified Enneking grading system was assessed.⁽⁸⁾ Any complications associated with bone grafting were also assessed.

Radiological incorporation of allograft was assessed by serial follow-up of anterior-posterior and lateral x-rays at 3 months and 6 months after the operation.

Union was considered complete when either the clearly delineated trabeculae bridging the graft host junction were seen, or the incorporated cancellous graft has acquired the same radio-density as the supporting host bed, with continuous pattern throughout.⁽¹¹⁾

Clinical grading was divided into four groups (modified from Enneking system) as excellent, good, fair and poor taking into account parameters like motion, pain, stability, functional activity and emotional acceptance.⁽⁸⁾ Excellent- pain free, normal function of the part; Good- pain free but some degree of impairment of function that mainly limited recreational activities; Fair- if pain and disability were sufficient enough to require aids or support or unable to return to an appropriate work status; Poor- severe complications along with disability.

Results & Discussion

Mankin et al studied 61 patients in whom they used allografts for tumor resection cases.⁽⁴⁾ Wang et al reported on 15 patients of hip reconstruction procedures following failed total hip arthroplasties.⁽¹²⁾ Ghazavi et al in 1997 reported on use of allograft for post traumatic osteochondral defects in 126 knees.⁽¹³⁾ In exclusive upper limb series, Isacker et al used allografts for tumor resection in upper limbs in 10 patients.⁽¹⁴⁾ In our series we are presenting 11 different cases of trauma involving upper limbs.

The radiological union was achieved in 73.8% by Mankin et al, 70% by Isacker et al, 100% by Segur et al, 100% by Lasanianos et al and in 95.4% by Feng et al.^(4,14,15,16,17) In our study we achieved union in 91% of cases. Modified Enneking Functional score preoperatively was fair in 4 patients and poor in 7 patients.⁽⁸⁾ 3 months postoperatively, score was fair in 1 patient and good in 10 patients. Radiological union was seen by 3 months in 8 patients and by 6 months in 2 patients with the average time of 14.4 weeks taken for union. The mean follow-up was 12.3 months (8 – 19 months). Bhan et al in 2003 reported complete radiological consolidation in 26 out of 32 cases with the average time taken for union of 30 weeks (range 12-72 weeks).⁽¹⁸⁾ Since majority of the studies reported on use of allografts following tumour resection their priority was the survival of the graft. But as we studied the use of allografts for bone defects following trauma the time taken for fracture union was critical in our study.

Wang et al in 2004 reported on use of bone allografts in hip reconstruction procedures following failed total hip arthroplasties in 15 patients.⁽¹³⁾ Junction non-union (13%), allograft fracture (6.7%), loosening of acetabular component (6.7%), trochanteric escape (26.7%), allograft infection (20%), and allograft resorption (20%) were some of the complications encountered in their study. We had complication in one case where there was non-union of the proximal humerus after plating with allograft application (femoral head) which we managed with re-plating and repeat bone grafting, in which case union was achieved in 9 months.

Among the other cases there were no complications such as infections, non-union or malunion and no patient required repeat surgery.

The drawbacks if any in our study would be the small sample size and the short follow-up period.

As there were very few studies reporting on the use of allografts for the specific indication of trauma we have also compared the results of our study with other studies where reconstruction following tumour resection was the indication for bone grafting.(Table 1)

For reconstruction of large bony defects allografts appear to have a unique and valuable place in the surgeon's armamentarium considering the extent of procedures involved.⁽¹⁹⁾

Table 1: Comparison of Studies where Allograft was used

S. No.	Study	Indication for Bone Grafting	Sample Size	Radiological Union	Follow Up
1.	Mankin et al ⁽⁴⁾ 1982	Tumour Resection	61	73.8%	2 years
2.	Ghazavi et al ⁽¹³⁾ 1997	Post traumatic Osteochondral defects of the Knee	126	85%	7.5 years
3.	Segur et al ⁽¹⁵⁾ 1998	Tibial Plateau Fractures	20	100%	-

4.	Bhan et al ⁽¹⁸⁾ 2003	ALL cases Including trauma	32	84%	2.5 years
5.	Wang et al ⁽¹³⁾ 2004	Hip reconstruction procedures following failed total hip arthroplasties	15	67%	7.6 years
6.	Lasanianos et al ⁽¹⁶⁾ 2008	Tibial Plateau Fractures	23	100%	1.08 years
7.	Isacker et al ⁽¹⁴⁾ 2011	Tumour resection in Forearm	10	70%	10 years
8.	Aponte-Tinao et al ⁽²⁰⁾ 2013	Tumour resection in Upper Limb	70	79%	5 years
9.	Feng et al ⁽¹⁷⁾ 2013	Tibial Plateau Fractures	22	95.4%	1.5 years
10.	Our Study 2016	Trauma in Upper Limb	11	91%	1 year

13 year old Male with Right Distal Radius Non-union following h/o Trauma

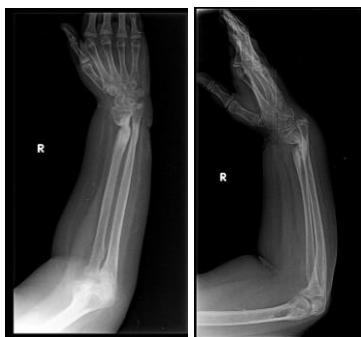

Fig. 1: Pre-Op Xrays

There was non-union of the radius with loss of height for which shortening of the Ulna was done and plating was done

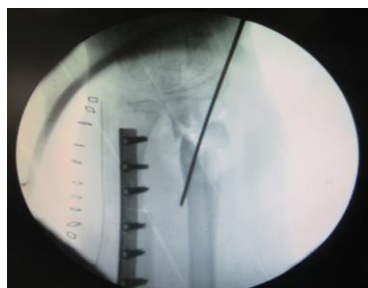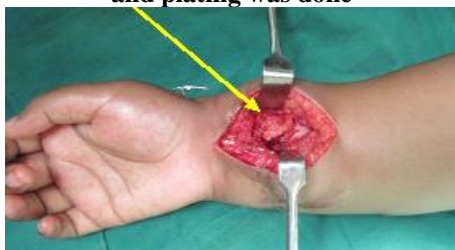


Fig. 2: Intra-Op Photos

Allograft placed in the recipient site and held in position with K-wires

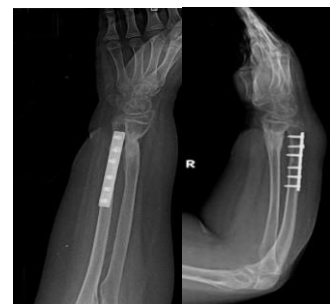
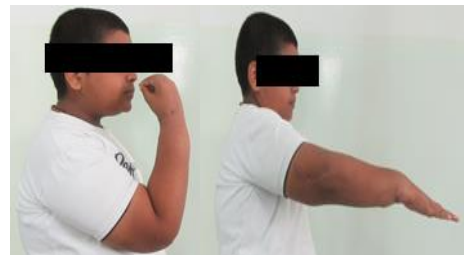
Fig. 3: One Year Follow Up, Post-Op X-Rays

Clinical Photos



Conclusion

Our study has shown good results with use of bone allografts in 11 cases with more than a year of follow up.

Allografts are a good substitute for bridging bone defects for patients with trauma. In contrast to Autografts, they help prevent postoperative donor site morbidity in patients who have already suffered trauma.

91% of the patients achieved radiological union. Union was seen by 3 months in 8 patients and by 6 months in 2 patients.

We can hence conclude that our results of using bone allografts with due care and attention in Upper Limb are very satisfactory and promising.

References

1. Keating J.F, Simpson AHRW and Robinson C.M. The management of fractures with bone loss. Journal of Bone

- and Joint Surgery - British Volume. 2005;87-B(2):142-150.
2. Vijay Langer, "Management of Major Limb Injuries," *The Scientific World Journal*, vol. 2014, Article ID 640430, 13 pages, 2014. doi:10.1155/2014/640430.
 3. Mumford JE, Simpson AHRW. Management of Bone Defects: A Review of Available Techniques. *The Iowa Orthopaedic Journal*. 1992;12:42-49.
 4. Mankin HJ, Doppelt Sh, Sullivan TR, Tomford WW. Osteoarticular and intercalary allograft transplantation in the management of malignant tumors of bone. *Cancer*.1982;50:613.
 5. Borja FJ, Mnaymneh W. Bone allografts in salvage of difficult hip arthroplasties. *Clin Orthop*.1985;197:123.
 6. Kandel RA, Gross AE, Ganel A, McDermott AGP, Langer F and Pritzker KPH. Histopathology of failed osteoarticular shell allografts. *Clin Orthop* 1985;197:103.
 7. Harris WH. Allografting in total hip arthroplasty. In adults with severe acetabular deficiency including a surgical techniques for bolting the graft to Ilium. *Clin Orthop*. 1982;162:150-164.
 8. Enneking WF. A system of functional evaluation of the surgical management of musculoskeletal tumors. Limb salvage in Musculoskeletal Oncology. New York; Churchill Living stone. 1987.
 9. Head WC, Berklacich FM, Theodore IM, Emerson RH. Proximal femoral allograft in revision total hip arthroplasty. *Clin Orthop* 1987;225:22-36.
 10. Heekin RD, Engh LA, Ving T. Morselized allograft in acetabular reconstruction. A post mortem retrieval analysis. *Clin. Orthop* 1995;319:184-190.
 11. Conn RA, Paterson LFA, Stauffer RN, and Ilstrup D. Management of acetabular deficiency: Long term results of bone grafting of acetabulum in THR. *Orthop Trans*.1985;9:451-452.
 12. Wang JW, Wang CJ. Proximal femoral allografts for bone deficiencies in revision hip arthroplasty: a medium-term follow-up study. *J Arthroplasty*. 2004 Oct;19(7):845-52.
 13. Ghazavi, M. T. et al. "Fresh Osteochondral Allografts For Post-Traumatic Osteochondral Defects Of The Knee". *The Journal of Bone and Joint Surgery* 79.6(1997):1008-1013.
 14. Van Isacker T., Barbier O, Traore A, Comu O, Mazzeo F, Delloye C. Forearm reconstruction with bone allograft following tumour excision: A series of 10 patients with a mean follow-up of 10 years. *Orthopaedics & Traumatology: Surgery & Research*. 2011;97(8):793-799.
 15. Segur, J. M. et al. "Use of Bone Allograft in Tibial Plateau Fractures". *Archives of Orthopaedic and Trauma Surgery* 117.6-7 (1998):357-359.
 16. Lasanianos, N., G. Mouzopoulos, and C. Garnavos. "The Use of Freeze-Dried Cancellous Allograft in the Management Of Impacted Tibial Plateau Fractures". *Injury* 39.10 (2008):1106-1112.
 17. Feng, Wei et al. "The Use Of Deep Frozen And Irradiated Bone Allografts In The Reconstruction Of Tibial Plateau Fractures". *Cell and Tissue Banking* 14.3(2012):375-380.
 18. Shukla S, Malhotra R, Bhan S, Results of fresh frozen bone allografts in Orthopaedics. *Indian J Orthop* 2003;37:8.
 19. Makley JT. The use of allografts to reconstruct intercalary defects of long bones. *Clin Orthop Relat Res*. 1985 Jul-Aug;(197):58-75.
 20. Aponte-Tinao L, Ayerza M, Muscolo D, Farfalli G. Allograft Reconstruction for the Treatment of Musculoskeletal Tumors of the Upper Extremity. *Sarcoma* 2013;2013:1-6.