

Treatment of unstable intertrochanteric fractures with cemented bipolar prosthesis- A prospective study

Lokesh Gudda Naik^{1,*}, Krishna Sudhakar Badgire², Gaurav Mahesh Sharma³, Faisal Qureshi⁴

^{1,2,3,4}Clinical Associate, Dept. of Orthopaedics, Sir HN Reliance Foundation Hospital, Mumbai

***Corresponding Author:**

Email: drortholokesh@gmail.com

Abstract

Introduction: Peritrochanteric fractures comprise of fractures of trochanter, subtrochanteric region and basi-cervical fractures and are the commonest fractures encountered. Patients with unstable intertrochanteric fractures need immediate mobilization to avoid serious complications.

Material and Methods: 43 patients with unstable intertrochanteric fractures were randomized and operated using the cemented bipolar prosthesis between September 2011 and August 2013. The inclusion criteria were patients more than 65 years of age, unstable intertrochanteric fracture (Type III and type IV as per Evans classification). Patients with polytrauma and medically unfit patients were excluded from the study.

Results: Mean age was 76.65 ± 5.48 years. The most common mechanism of injury was domestic fall comprising of 87%. The average duration of surgery from the time of injury was 3.5 ± 1.3 days. The average surgical duration was 03.5 mins. The average duration of stay in hospital was 8.4 ± 1.68 days. Final results were calculated using the Harris Hip score with 97% cases as excellent and good while 3% had fair results respectively. Follow-up was done at 1, 3, 6, 12 and 24 months.

Conclusion: Cemented bipolar hemiarthroplasty in unstable intertrochanteric fractures has an advantage of stable adequate fixation with early return to activities of daily living, thus preventing serious life threatening complications.

Keywords: Intertrochanteric fractures, Hemiarthroplasty, Femur, Harris hip score

Introduction

Peritrochanteric fractures are perhaps the most common fractures encountered by an orthopaedic surgeon today. These include fractures of trochanter, subtrochanteric region and basi-cervical fractures. These fractures often have substantial rate of morbidity and approximately 15% to 20% of patients die within one year of fracture.⁽¹⁻²⁾

Among the intertrochanteric fractures, the unstable type fractures pose more difficulty in treatment as well as prognosis. Osteoporosis associated with difficult reduction in such types of fractures dictate the final outcome.⁽³⁻⁵⁾ Owing to the varied surgical options available, we decided to undergo a prospective randomized trial in patients with unstable intertrochanteric fractures, treated with cemented bipolar prosthesis.

Material and Methods

43 cases of unstable intertrochanteric fractures treated with cemented bipolar hemiarthroplasty were studied over between September 2011 and August 2013 at a tertiary care hospital in Ahmednagar district. The inclusion criteria were patients more than 65 years of age, unstable intertrochanteric fracture (Type III and type IV as per Evans classification), patients with ambulatory status prior to the fracture. Patients with polytrauma, medically unfit patients, patients with cardio-respiratory distress and allergic to cement were excluded from the study.

A careful brief pre-operative history was elicited from the patients to know the mechanism of injury and

the severity of trauma. The patients were then assessed clinically and haematological investigations along with radiographs of the affected hip joint including opposite hip and pelvis were taken in antero-posterior and lateral views (Fig. 1). Well written prior informed consent was taken pre-operatively from all the patients. Prior ethical committee approval was obtained before commencing the study.

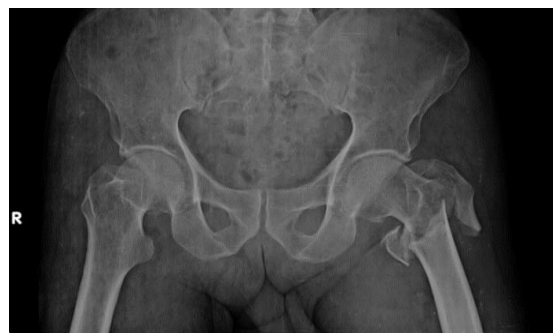

Fig. 1: Pre-operative

Surgical Technique: Spinal combined with epidural anaesthesia was given in majority of the cases. Three doses of second generation cephalosporin injection were given, one just after the induction and two at 12 hourly interval. Two doses of Inj Tranexamic acid, one just after the induction and one after 12 hour interval was given. All the surgeries were performed in lateral decubitus position. Moore's posterior approach was used in all the cases. 10 cm midline incision centered over the greater trochanter was taken. Fascia lata followed by vastus

lateralis was incised and the short external rotators were exposed (Fig. 2). Coxofemoral bypass was used and the short external rotators were not cut. Femoral head was delivered with the help of corkscrew. Adequate head size was assessed with the help of ring. The femoral canal was exposed and entry was made with the box osteotome. Gradual broach were inserted to assess the adequate size. Trial neck and head was introduced and carefully relocated with traction external rotation, extension and abduction. Range of movements were assessed thoroughly intra-operatively. Bone cement Palacos R+G was used in all the cases and the final implants were inserted and reduction was done. The fractured fragments of greater trochanter were sutured with the help of 18G SS wire in figure of 8 manner whenever necessary (Fig. 3). Meticulous closure was done in layers and no suction drain was used in any of the case. Compression dressing was done in all the cases. Similar pain control protocols were followed for all the patients. Patients were mobilized from post-operative day one in the form of full weight bearing with the help of walker as per the pain tolerance.

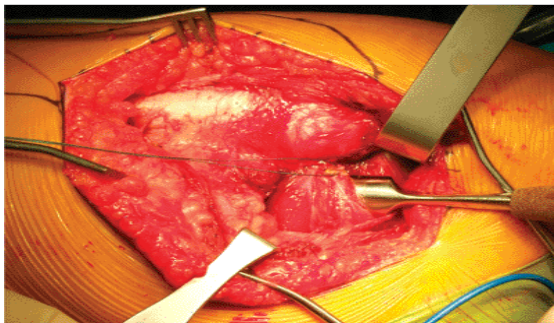


Fig. 2: Intra-operative Exposure

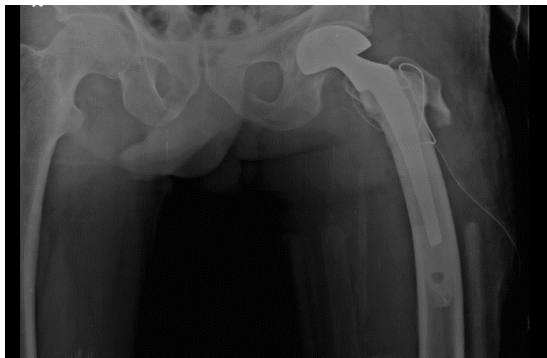


Fig. 3: Immediate Post-operative X ray

Results

The mean age observed was 76.65 ± 5.48 years, with 65% of the cases in the age group between 70-80 years. Seventy percent of the cases were females. Right side was predominantly involved in majority of the cases. The most common mode of injury encountered was a domestic fall comprising of 37 cases (87%). The average duration of surgery from the time of injury was 3.5 ± 1.3 days. The average operating time was 103.5 mins with

227.5ml of blood loss intra-operatively. Intra-operative blood was measured with the help of blood collected in the mobs used during the surgery. The average duration of stay in hospital was 8.4 ± 1.68 days. 0.5cm shortening was encountered in two patients in the present study. Final results were calculated using the Harris Hip score (Table 1). 14 (32.5%) patients had excellent, 23 (53.4%) had good, 4 (9.4%) had fair and 2 (4.7%) patients had poor results respectively (Table 2). Regular follow-up was done at 1, 3, 6, 12 and 24 months (Fig. 4).

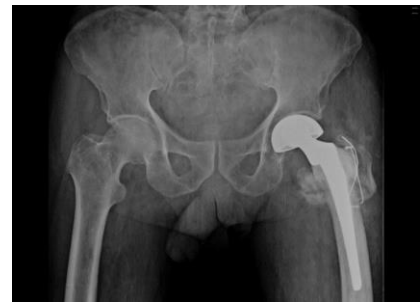

Fig. 4: Follow-up at 24 months

Table 1: Harris Hip score

Harris Hip Score	
Pain (check one)	Stairs
<input type="checkbox"/> None or ignores it (44)	<input type="checkbox"/> Normally without using a railing (4)
<input type="checkbox"/> Slight, occasional, no compromise in activities (40)	<input type="checkbox"/> Normally using a railing (2)
<input type="checkbox"/> Mild pain, no effect on average activities, rarely moderate pain with unusual activity; may take aspirin (30)	<input type="checkbox"/> In any manner (1)
<input type="checkbox"/> Moderate Pain, tolerable but makes concession to pain. Some limitation of ordinary activity or work. May require Occasional pain medication stronger than aspirin (20)	<input type="checkbox"/> Unable to do stairs (0)
<input type="checkbox"/> Marked pain, serious limitation of activities (10)	Put on Shoes and Socks
<input type="checkbox"/> Totally disabled, crippled, pain in bed, bedridden (0)	<input type="checkbox"/> With ease (4)
Limp	<input type="checkbox"/> With difficulty (2)
<input type="checkbox"/> None (11)	<input type="checkbox"/> Unable (0)
<input type="checkbox"/> Slight (8)	Absence of Deformity (All yes = 4; Less than 4 = 0)
<input type="checkbox"/> Moderate (5)	Less than 30° fixed flexion contracture <input type="checkbox"/> Yes <input type="checkbox"/> No
<input type="checkbox"/> Severe (0)	Less than 10° fixed abduction <input type="checkbox"/> Yes <input type="checkbox"/> No
Support	Less than 10° fixed internal rotation in extension <input type="checkbox"/> Yes <input type="checkbox"/> No
<input type="checkbox"/> None (11)	Limb length discrepancy less than 3.2 cm <input type="checkbox"/> Yes <input type="checkbox"/> No
<input type="checkbox"/> Cane for long walks (7)	Range of Motion (*indicates normal)
<input type="checkbox"/> Cane most of time (5)	Flexion (*140°) _____
<input type="checkbox"/> One crutch (3)	Abduction (*40°) _____
<input type="checkbox"/> Two canes (2)	Adduction (*40°) _____
<input type="checkbox"/> Two crutches or not able to walk (0)	External Rotation (*40°) _____
Distance Walked	Internal Rotation (*40°) _____
<input type="checkbox"/> Unlimited (11)	Range of Motion Scale
<input type="checkbox"/> Six blocks (8)	211° - 300° (5) 61° - 100 (2)
<input type="checkbox"/> Two or three blocks (5)	161° - 210° (4) 31° - 60° (1)
<input type="checkbox"/> Indoors only (2)	101° - 160° (3) 0° - 30° (0)
<input type="checkbox"/> Bed and chair only (0)	Range of Motion Score _____
Sitting	Total Harris Hip Score _____
<input type="checkbox"/> Comfortably in ordinary chair for one hour (5)	
<input type="checkbox"/> On a high chair for 30 minutes (3)	
<input type="checkbox"/> Unable to sit comfortably in any chair (0)	
Enter public transportation	
<input type="checkbox"/> Yes (1)	
<input type="checkbox"/> No (0)	

Table 2: Results as per Harris Hip scoring

Scores	No. of cases	Percentage (%)
91-100 (excellent)	14	32.5
81-90 (good)	23	53.4
71-80 (fair)	04	9.4
<70 (poor)	02	4.7
Total	43	100

Discussion

Albeit there have been excellent results in patients with intertrochanteric fractures treated with osteosynthesis thus reducing the mortality,⁽⁶⁾ still 56% of the cases with posteromedial comminution have problems such as inadequate fixation, severe comminution or osteoporosis, especially in geriatric population.^(7,8) Early return to activities of daily living often plays a pivotal role in the prevention of severe long term complications associated with co morbid conditions. Osteoporotic bones usually have a poor purchase for the implants thus causing early implant failure. The treatment of unstable intertrochanteric fractures has constantly been changing from osteosynthesis to replacement.

Primary hemiarthroplasty enables the patient to return to his pre fractured ambulatory status immediately with the benefits of secured fixation, thus avoiding serious complications like pseudoarthrosis, atelectasis, pneumonia and pressure sores. Few authors have mentioned about the application of primary arthroplasty in the Indian scenario.^(11,12)

Primary hemiarthroplasty for unstable intertrochanteric fractures is less commonly used in contrast to patients with neck femur fractures.⁽¹³⁾ Initial application of primary hemiarthroplasty usually follows cases with failed pinning or some other complications.⁽¹⁴⁾ Early ambulation and return to pre-fractured status was stated as a definitive advantage by Stern and Goldstein in their series of 22 patients with intertrochanteric fractures treated with Leinbach prosthesis.⁽¹⁴⁾

Liang *et al*,⁽¹⁵⁾ concluded in their study that hemiprosthesis is an effective modality which can decrease the morbidity, mortality and the cumulative financial burden of the patients family. Grimsrud *et al*⁽¹⁶⁾ in their series of 39 patients treated by cemented hemiarthroplasty in unstable intertrochanteric fractures, concluded that standard femoral stem can be combined with circlage cables for greater trochanter. They inferred that this technique allows early and safe weight bearing with relatively lower rate of complications.

Rodop *et al*⁽¹⁷⁾ in a similar study of 37 patients had 17 (45%) excellent and 14 (37%) good results respectively at the end of 12 months, using the Harris hip scoring system. 37 patients (85.09%) had excellent to good results, 4 patients (9.4%) had fair and 2 patients (4.7%) had poor results in the present study. This treatment modality has more promising results, especially with the variable outcomes of osteosynthesis.⁽¹⁸⁾

The opponents of the hemiarthroplasty are of the view that it is associated with intra operative complications such as increased blood loss, inadequate fixation of the greater trochanter and post-operative dislocation and infection. However the benefits outweigh the disadvantages and risks associated. The average intra-operative blood loss in the present study was 227.5ml.

Broosetal⁽¹⁹⁾ in their study stated that the patients with hemiarthroplasty (73%) had less pain post-operatively than those with internal fixation (63%). The Functional outcome of the hemiarthroplasty was comparable in terms of blood loss, mortality rates and surgical time in both the groups.

Limitations of the study

Parameters like rate of mortality and the time to operate were not studied in detail due smaller sample size which was a limitation of the present study. Long term follow-up and more multicentric randomized studies will help to correlate about the life expectancy of prosthesis in such kind of fractures.

Conclusion

Cemented bipolar prosthesis has promising results in future in patients with unstable intertrochanteric fractures. However, more meta-analysis and randomized trials will help to reach a final conclusion.

Acknowledgements: Nil

References

1. Eiskjaer S, Otsgard SE, Jakobsen BW, Jensen J, Lucht U. Years of potential life lost after hip fracture among postmenopausal women. *Acta Orthop Scand.* 1992;63(3):293–296.
2. Dahl E. Mortality and life expectancy after hip fractures. *Acta Orthop Scand.* 1980;51(1):163–170.
3. Kim WY, Han CH, Park JI, Kim JY. Failure of intertrochanteric fracture fixation with a dynamic hip screw in relation to pre-operative fracture stability and osteoporosis. *Int Orthop.* 2001;25:360–2.
4. Larsson S. Treatment of osteoporotic fractures. *Scand J Surg.* 2002;91:140–6.
5. Jensen JS, Tondevold E, Mossing N. Unstable trochanteric fractures treated with the sliding screw-plate system: A biomechanical study of unstable trochanteric fractures. III. *Acta Orthop Scand.* 1978;49:392–7.
6. White BL, Fisher WD, Laurin CA. Rate of mortality for elderly patients after fracture of the hip in the 1980's. *J Bone Joint Surg Am.* 1987;69:1335–40.
7. Kyle RF, Cabanela ME, Russell TA, Swiontkowski MF, Winquist RA, Zuckerman JD, et al. Fractures of the proximal part of the femur. *Instr Course Lect.* 1995;44:227–53.
8. Haidukewych GJ, Israel TA, Berry DJ. Reverse obliquity fractures of the intertrochanteric region of the femur. *J Bone Joint Surg Am.* 2001;83:643–50.
9. Wolfgang GL, Bryant MH, O'Neill JP. Treatment of intertrochanteric fracture of the femur using sliding screw plate fixation. *Clin Orthop Relat Res.* 1982;163:148–58.
10. Sernbo I, Johnell O, Gentz CF, Nilsson JA. Unstable intertrochanteric fractures of the hip: Treatment with Ender pins compared with a compression hip-screw. *J Bone Joint Surg Am.* 1988;70:1297–303.
11. Haentjens P, Casteleyn PP, DeBoeck H, et al. Treatment of unstable intertrochanteric and subtrochanteric fractures in elderly patients: primary bipolar arthroplasty compared with internal fixation. *J Bone Joint Surg* 1989; 71A: 1214–1255.

12. Stern MB, Angerman A. Comminuted intertrochanteric fractures treated with a Leinbachprosthesis. *Clin Orthop Relat Res.* 1987;218:75–80.
13. Kulkarni GS, Limaye R, Kulkarni M, Kulkarni S. Intertrochanteric fractures. *Indian J Orthop.* 2006;40:16–23.
14. Babhulkar SS. Management of trochanteric fractures. *Indian J Orthop.* 2006;40:210–8.
15. Stern MB, Goldstein TB. The use of the Leinbach prosthesis in Intertrochanteric fractures of the hip. *Clin Orthop Relat Res.* 1977;128:325–31.
16. Tronzo RG. The use of an endoprosthesis for severely comminuted trochanteric fractures. *OrthopClin North Am.* 1974;5:679–81.
17. Liang YT, Tang PF, Guo YZ, Tao S, Zhang Q, Liang XD, et al. Clinical research of hemiprosthesis arthroplasty for the treatment of unstable intertrochanteric fractures in elderly patients. *Zhonghua Yi XueZaZhi.* 2005;85:3260–2.
18. Grimsrud C, Monzon RJ, Richman J, Ries MD. Cemented hip arthroplasty with a novel cerclage cable technique for unstable intertrochanteric hip fractures. *J Arthroplast.* 2005;20:337–43.
19. Hardy DC, Descamps PY, Krallis P, Fabeck L, Smets P, Bertens CL, et al. Use of an intramedullary hip-screw compared with a compression hip-screw with a plate for intertrochanteric femoral fractures: A prospective, randomized study of one hundred patients. *J Bone Joint Surg Am.* 1998;80:618–30.