

Functional outcome of dual plate osteosynthesis in type V & VI Proximal tibial fracture

Mayank Patel^{1*}, Jayant Sharma², Sunil Jakhar³

¹Resident, ³Assistant Professor, Unique Superspeciality Centre, Indore, Madhya Pradesh, ²Associate Professor, Dept. of Orthopaedics, Index Medical College, Indore, Madhya Pradesh

***Corresponding Author:**

Email: drmpatel1@gmail.com

Abstract

Introduction: Comminuted of articular surfaces and metaphyseal region, extensive soft tissue injuries, infection and risk of compartment syndrome are the challenging factor for management of proximal bicondylar Tibial fractures. Various modalities like cast, traction or open reduction and internal fixation using single to dual plating available for treating such type of fractures. We study the results of dual locking plate and buttress plating in management of proximal Tibial Schatzker V and VI tibial plateau fracture by using minimally invasive surgical technique.

Method: The study was conducted on 30 patients admitted in the department of orthopaedics at Unique super specialty centre, Indore with diagnoses of Tibial plateau fractures (Schatzker classification type 5 and 6) treated with minimally invasive bicondylar fixation. The patients were followed up for a minimum period of six months and clinical and radiological progression of fracture union with the functional outcome was studied by using knee society score.

Result: 2 patients out of 30 were lost follow up and 20 patients showed excellent results while 8 patients had good to fair and none with poor result. The average time for radiological union was 12 weeks.

Conclusion: The results of the study concluded that by using minimal invasive technique of bi condylar fracture fixation are excellent without any major complication.

Keywords: Tibial plateau fractures, dual locking and buttress Tibial plate, proximal Tibial Schatzker type V, VI fractures, minimally invasive surgical fixation technique.

Introduction

Knee injuries are more common in generalized trauma due to increase motor vehicle accident nowadays. Stiffness, arthritis and instability are major complication of intraarticular fracture of tibia. soft tissue injury are usually a result of high velocity trauma due to axial loading combined with valgus / varus forces in complex tibial plateau injuries.⁽¹⁾ Challenge with treatment of proximal Tibial fracture is not only achieving union but also restoration of joint anatomy perfectly and joint mobility. Various methods of treatment for complex and compound fractures are being used now days for restoration and maintenance of reduction of the fracture with ultimate aim of prevention of occurrence of late degenerative arthritis and stiffness. Selection of proper implant play major role in such injuries. Casting and traction in these situations give poor results and functional outcome in displaced fracture. Till date common protocol of each type of complex Tibial plateau fractures has not developed. CT scan and MRI imaging techniques, are more helpful to studies fractures pattern. Surgical management of proximal tibial fracture is evolving from open reduction and internal fixation to arthroscopic assisted minimally invasive surgery. Currently such injuries are being managed by single medial or lateral/dual plating, fixator (hybrid, ring, JESS fixator) along with plate depending upon need of injury pattern and surgical expertise of surgeons. Locking plates are widely used now days⁽²⁾ and

techniques of fixation are continuously in process of evolution from LISS (less invasive stabilization system) to periarticular locking compression plate system (LCP).^(3,4) We have analyzed our results of dual locked and buttress plate in surgical treatment of proximal Tibia type 5 and 6 fractures with aim to achieve a good functional outcome.

Material and Method

Total 30 patients from April 2015 to December 2016, all Bicondylar Tibial plateau fractures (Schatzker type V, VI) admitted and treated with minimally invasive dual locking and buttress proximal Tibial plate at unique super specialty centre, Indore having following mention inclusion and exclusion criteria were included in study.

Inclusion criteria

- Schatzker type V, VI proximal tibial fractures.
- Open fractures up to Gustilo-Anderson Type II
- Age above 18 years & below 60 years.

Exclusion criteria

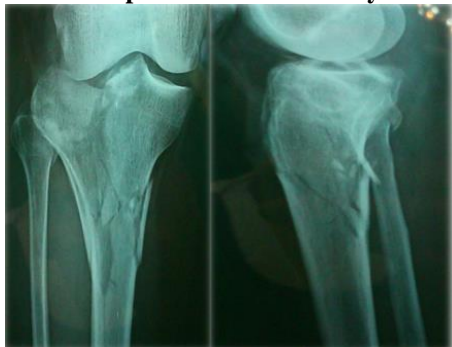- Fracture with ipsilateral neuro-vascular deficit
- Fracture with dislocation of knee joint
- Any previous pathology or fracture around knee joint
- Any past history of surgery around knee joint

With total 30 patient available for study mean of age of patients was 38.43 years (range from 18-60). 25 patient were male gender and 5 were female gender. 21 patient has right side Tibial plateau fractures as

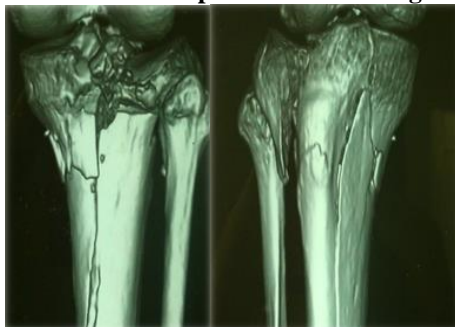
compared to 09 patient who sustained injury on left side tibia. 02 patient presented with open injury up to Gartland Anderson grade II, rest 28 patient had closed fracture with most of them having either bruising or blisters. 2 cases were lost during study and follow up. There were 22 patients with Schatzker type V fracture pattern as compared to 08 patients of Schatzker type VI. 28 patients had this complex Tibial plateau fracture as result of high velocity injury due to road traffic accidents remaining 02 patients had a low velocity injury due to fall at home. 25 patients presented within 72 hour of injury and rest 05 patient presented late after either referred from other hospital after primary management on slab.

Procedure: This study was approved by the Ethical Committee of unique super specialty centre Indore M.P. Preoperative radiographs Anteroposterior view and Lateral view and computed tomography (CT) scans were used to diagnosed each bicondylar proximal Tibial fracture.

Picture 1: Pre op AP & Lateral X Ray Knee Joint



Picture 2: Pre op 3D CT Scan Images



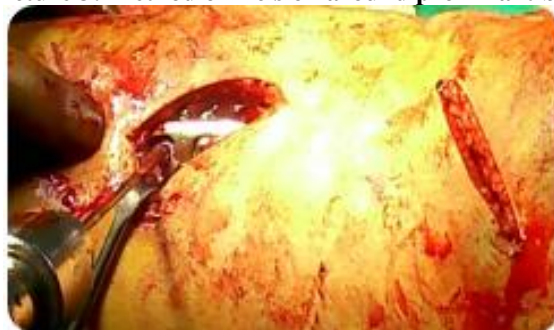Open injury patients were underwent surgical debridement within 8 hours of injury after received tetanus prophylaxis tetglob and intravenous antibiotics for prevention of infection. For open fractures, the wound was radically debrided and profusely lavaged with 3 to 6 litre of normal saline. The wound was closed either primarily or after 48 to 72 hours after a repeat irrigation with normal saline and debridement, depending on the level of contamination and amount of soft tissue damage. Intravenous Antibiotics (cefuroxime

and metronidazole) were prescribed for the first 5 days. Clinical signs of soft tissue recovery included decreased swelling, healing of Fracture blisters, and wrinkling of the skin around the proximal tibia.^(11,12) Decisions of fixation method, implant selection and timing were guided by the surgeon's experience.

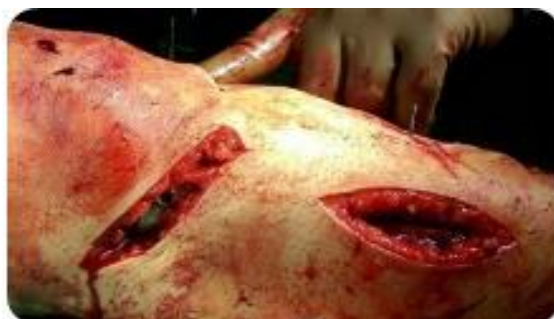All the patients in our study were managed by using minimally invasive dual anatomical pre contoured locking plate in sterile O.T at our centre.

Patient position was supine on a standard radiolucent orthopaedics operating table, after application of tourniquet, and put the small round bolster below the knee joint with four small incision two on lateral and two on medial side of proximal tibia.

Picture 3: Method of incision around proximal tibia



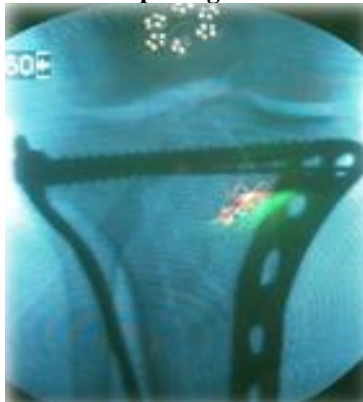
Medial Side of Upper Tibia



Lateral Side of Upper Tibia

Elevation of depressed fragments of articular surface done by the punch and mallet under guidance of image intensifier after making of cortical window on the affected side and fixed it with subchondral k wires initially. Bone grafting at empty space below the depressed segment was done in 3 cases after taking graft from iliac crest. Medial anatomical pre-contoured locked plate was secured using locking screw (Fig. 3). Laterally also anatomical pre-contour were inserted percutaneously to secure lateral tibial plateau fixation with 6.5 mm fully threaded cancellous screw in metaphyseal region and cortical screw in diaphyseal region of tibia.

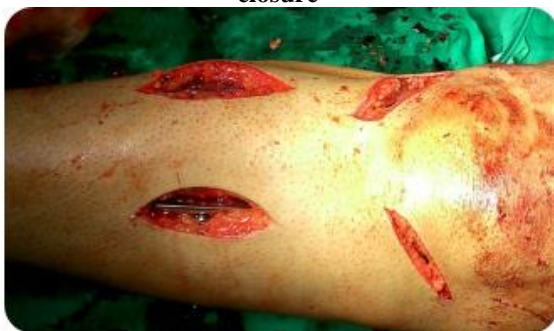Picture 4: Intra Op Image Intensifier Image



Fixation of the medial column was performed first after taking an incision made on anteromedial border of the Tibial metaphysis, with dissection through the interval between the pes anserinus tendons and the medial head of the gastrocnemius.

The anterolateral incision was started 1 to 2 cm lateral to the Patella and extended distally over Gerdy's tubercle and 1 cm lateral to the crest of the Tibia. Subperiosteal dissection was limited to the fracture margins and the diaphyseal region where plate should be placed. Depressed fragments were elevated and supported with autograft harvested from Iliac crest or allograft whenever it may required. Locking plates were applied once anatomic reduction had been achieved. Locking plate was used on the side with relatively more severe fracture comminution and the other side were fixed with a buttress plate.^(12,13)

Picture 5: Intra Op final Picture before wound closure



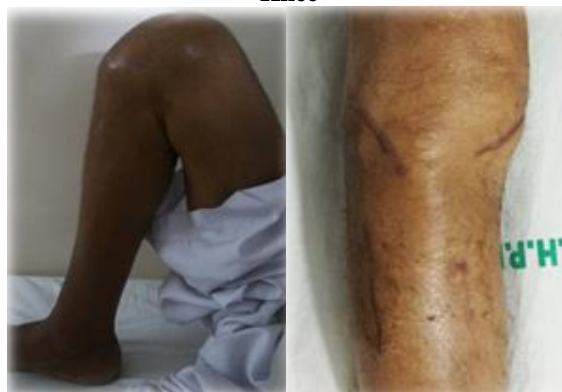In open fractures, incisions were based on the fracture pattern and location of the traumatic open wounds.

The goal was to minimize soft tissue stripping and periosteum damage.⁽¹³⁾ All patients had a similar postoperative regimen and were followed up at regular intervals at 6, 8, 12, 24 weeks for at least 6 months.

Post-Operative: After the pain was subside the Range of motion exercises and isometric muscle strengthening exercises started under supervision of

physiotherapist.^(12,13,14) Non weight bearing walking exercises started immediately after pain decreased and continue upto 6 weeks, then partial weight bearing started. Full weight bearing started after the sign of bony healing on radiograph.⁽¹³⁾ During the each follow-up period, radiograph and functional score measure and also maintain the record of any complication during follow up period. Functional evaluation of knee joint was performed at least after 6 months according to Knee Society Scores.^(14,15)

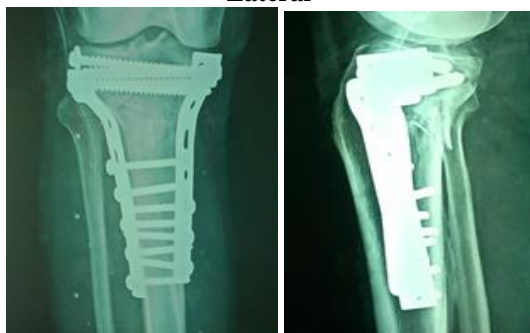Picture 6: Range of Motion Post Op 6 months at Knee



If an intra-articular step-off of at least 2 mm measured on scaled radiographs it is defined as malreduction. Alignment of the proximal tibia was determined by measuring the Tibial plateau angle (the medial angle between the tangential line and anatomic axial of the tibia) on anteroposterior radiographs and the posterior slope angle (the angle between the tangential line of medial plateau and the perpendicular line of the anterior tibial cortex) on lateral radiographs; tibial plateau angle $>90^\circ$ or $<80^\circ$ or posterior slope angle $>15^\circ$ or $<25^\circ$ was considered as a malalignment of intraarticular surface of proximal tibia.⁽¹⁵⁾

If there is an increase of 2 mm of Intra-articular step-off is defined as secondary loss of reduction, if an increase of 3° malalignment when compared with the first postoperative radiograph is defined as secondary loss of alignment.⁽¹⁵⁾ If >3 cortical unions during the follow-up period radiograph consider as a bony union. Non-union was defined as no evidence of healing after 9 months.⁽¹⁶⁾

Picture 7: 6 month Post op X Ray Knee AP & Lateral



Results

Out of 30 patients 2 patients lost the follow up subsequently and 28 patients were followed-up for at least 06 months. Age range of patients included was 18 years to 60 years, with mean age 38.43±15.16 years. 25 patients were male, while 5 were female. 75% injuries were due to road traffic accidents. 22 fractures were Schatzker type 5 fractures, and 08 were Schatzker type 6 fractures.⁽¹⁾ 28 fractures were close, and 2 were open grade 1 fractures according to Gustilo classification.⁽⁸⁾ 3 patients had head injury and 1 had chest trauma. Within 7 days most of patients were treated surgically.

All the 30 patients of proximal tibial fractures were surgically treated with a combination of locking plate and or buttress plate with dual minimal invasive incision approach.

Complications included 2 superficial infection which were treated by IV antibiotics and surgical wound management. Malreduction or malalignment was not measured on the first postoperative radiographs. Minor pain in the knee was common complain of most of patients. Out of 28 patients, 20 achieved excellent knee score (80-100), 6 achieved good (70-79), 2 achieved fair (60-69) and no patient had poor (<60) knee score. Mean range of knee flexion was 110 degrees.

The new Knee Society Score is composed of five components:

1. Patient Demographics
2. Objective Knee Score – filled by the surgeon.
3. Patient Expectations – filled by the patient.
4. Patient Satisfaction Score – filled by the patient.
5. Functional Knee Score– filled by the patient.

1. Type of Fracture (Schatzker)

Type of Fracture	No. of Patients
Type V	22
Type VI	08

2. Side of Fracture

Side of Injury	No. of Patients
Left	09
Right	21
Left and Right	00

3. Sex

Gender	No. of Patients
Male	25
Female	05

4. Complications

Name of Complication	Affected number of Patients
Infection	02
Wound Dehiscence	00
Residual Deformity	00
Change to Work	00
Unable to Work	00
Significant Pain	00
Walking Difficulty	00
Stiffness in Knee Joint	00

5. Functional Outcome Evaluate by Knee Society Scoring System

Grading	Patient's Number	Percentage
Excellent	20	71.42
Good	6	21.42
Fair	2	7.14
Poor	0	0
Total	28	99.98

Discussion

The swelling in the soft tissue around the knee joint and wound coverage are most common difficulties are faced by the treating surgeon during the surgery of proximal Tibia intraarticular fractures.

Various treatment option for proximal tibia are

1. Casts or braces, Traction;
2. External fixation (Ring or uniplaner);
3. Pre-counter anatomical plate for percutaneous fixation;
4. Dual plating with one or two incision;
5. Arthroscopically assisted fixation and minimal percutaneous pinning;
6. Medial fixator and lateral plating;
7. Minimally invasive techniques (LISS system).^(1,2,5,11,13-17)

Complications include in any method of treatment;

- Wound dehiscence;
- Super facial or Deep infection,
- Deep vein thrombosis;
- Compartment syndrome;
- Non-union;
- Knee stiffness, Myositis ossifican;
- Nerve palsies;
- Hardware failure, irritation of hardware; and
- Arthrofibrosis^(7,18-20)

Poor functional outcome and long hospital stays along with loss of reduction were found with using of non-operative treatment of proximal tibial fractures.⁽¹²⁾

Arthroscopically assisted fixation and minimal percutaneous pinning have also been reported to give Good results also achieved by arthroscopically assisted fixation and minimal invasive percutaneous pinning but these method are indicated in simple split depression and local compression fractures.^(17,21)

Complication like wound dehiscence and infection are commonly found in treated with open dual plating method of fixation.^(10,22,23)

Pin tract infection and prolonged courses of treatment are found in Hybrid fixation system.⁽²³⁻²⁸⁾ Some studies have reported that open lateral plating and medial uniplaner fixator in complex bicondylar fractures of the tibia give good functional results by the minimizing soft tissue complications.⁽¹³⁾

Now a days, minimally invasive techniques (LISS system) are used commonly performed by surgeons, and there have found the excellent results in proximal tibia plateau fractures being treated exclusively by this technique. By this system minimizes the surgical complications by decreasing the soft-tissue stripping, to provide a rigid fracture reduction at fracture site and to decreased post-traumatic soft tissue injury.^(15,29,30)

The major goals in the treatment of complex proximal Tibial fractures are anatomical reduction of articular surface and relatively stability at fracture site with good range of motion at knee joint and less complication.^(27,32)

In order to obtain stability of bicondylar and complex proximal Tibial fractures, anatomical reduction and rigid fixation of both medial and lateral columns is necessary. Dual plating with minimal invasive has highly successfully gives a good stability by buttressing both columns and low rate of complications associated with this miniopen technique is reported.

Steven N., *et al.* reported wound dehiscence and infection in proximal Tibial fractures treated with double plate fixation.⁽³³⁾

In our study superficial infection was observed in 2 cases but no soft tissue breakdown or wound dehiscence were noted and achieved excellent functional outcome of type V and type VI proximal tibial fractures in 20 patients.

Conclusion

The double plate fixation with minimal invasive by the two small medial and two small lateral incision is the best effective and simple procedure to perform in surgical treatment of complex proximal Tibial fractures (Types V and VI of Schatzker classification) with lower risk for complication and good radiological and functional outcomes.

References

- Schatzker J, McBroom R, Bruce D. The tibial plateau fracture, The Toronto experience 1968-1975. *Clin Orthop Relat Res* 1979;(138):94-104.
- Partenleimer A, Gosling T, Muller M, Schirmer C, Kaab M, Matschke S et al. Management of bicondylar fracture of the tibial plateau with unilateral fixed angle plate fixation. *Unfallchirurg* 2007;110:675-83.
- Gosling T, Schandelmaier P, Muller M, Hankemeier S, Wagner M, Krettek C. Single lateral locked screw plating of bicondylar tibial plateau fractures. *Clin Orthop Rel Res* 2005;439:207-14.
- Insall JN, Ranawat CS, Aglietti P, Shine J. A comparison of four models of total knee-replacement prostheses. *J Bone Joint Surg Am* 1976;58:754e65.
- Cole PA, Zlowodzki M, Kregor PJ. Less invasive stabilization system (LISS) for fractures of the proximal tibia: indications, surgical technique and preliminary results of the UMC Clinical Trial. *Injury* 2003;34(Suppl. 1):A16e29.
- Gosling T, Schandelmaier P, Marti A, Hufner T, Partenheimer A, Krettek C. Less invasive stabilization of complex tibial plateau fractures: a biomechanical evaluation of a unilateral locked screw plate and double plating. *J Orthop Trauma* 2004;18:546e51.
- Phisitkul P, McKinley TO, Nepola JV, Marsh JL. Complications of locking plate fixation in complex proximal tibia injuries. *J Orthop Trauma* 2007;21:83e91.
- Yang EC, Weiner L, Strauss E, Sedlin E, Kelley M, Raphael J. Metaphyseal dissociation fractures of the proximal tibia. An analysis of treatment and complications. *Am J Orthop (Belle Mead NJ)*. 1995; 24(9):695-704.
- Schatzker J, McBroom R, Bruce D. The tibial plateau fracture, The Toronto experience 1968-1975. *Clin Orthop Relat Res* 1979;(138):94-104.
- Gustilo RB, Anderson JT. Prevention of infection in the treatment of one thousand and twenty-five open fractures of long bones: retrospective and prospective analyses. *J Bone Joint Surg [Am]* 1976;58-A:453-8.
- Schatzker J, McBroom R, Bruce D. The tibial plateau fracture: the Toronto experience 1968-1975. *Clin Orthop* 1979;138:94-104.
- Gosling T, Schandelmaier P, Muller M, et al. Single lateral locked screw plating of bicondylar tibial plateau fractures. *Clin Orthop* 2005;439:207-14.
- Henry SL, Ostermann PA, Seligson D. The antibiotic bead pouch technique: the management of severe compound fractures. *Clin Orthop* 1993;295:54-62.
- Tscherne H, Oestern HJ. A new classification of soft-tissue damage in open and closed fractures (author's transl). *Unfallheilkunde* 1982;85:111-15 (in German).
- Roberts CS, Pape HC, Jones AL, et al. Damage control orthopaedics: evolving concepts in the treatment of patients who have sustained orthopaedic trauma. *Instr Course Lect* 2005;54:447-62.
- Egol KA, Tejwani NC, Capla EL, Wolinsky PL, Koval KJ. Staged management of high-energy proximal tibia fractures (OTA types 41): the results of a prospective, standardized protocol. *J Orthop Trauma* 2005;19:448-55.
- Sirkin M, Sanders R, DiPasquale T, Herscovici D Jr. A staged protocol for soft tissue management in the treatment of complex pilon fractures. *J Orthop Trauma* 1999;13:78-84.
- Rafii M, Firooznia H, Golimbu C, Bonamo J. Computed tomography of tibial plateau fractures. *AJR Am J Roentgenol* 1984;142:1181-6.

19. Chan PS, Klimkiewicz JJ, Luchetti W, et al. Impact of CT scan on treatment plan and fracture classification of tibial plateau fractures. *J Orthop Trauma* 1997;11:484-9.
20. Liow RY, Birdsall PD, Mucci B, Greiss ME. Spiral computed tomography with two- and three-dimensional reconstruction in the management of tibial plateau fractures. *Orthopedics* 1999;22:929-32.
21. A. Apley, "Fractures of the Tibial Plateau," *Orthopedic Clinics of North America*, Vol. 10, 1979, pp. 61-74.
22. Y. S. Chan, L. J. Yuan, S. S. Hung, C. J. Wang, S. W. Yu, C. Y. Chen, E. K. Chao and M. S. Lee, "Arthroscopic- Assisted Reduction with Bilateral Buttress Plate Fixation of Complex Tibial Plateau Fractures," *Arthroscopy*, Vol. 19, No. 9, 2003, pp. 974-984. doi:10.1016/j.arthro.2003.09.038.
23. C. A. Gaunche and A. W. Markman, "Arthroscopic Management of Tibial Plateau Fractures," *Arthroscopy*, Vol. 9, No. 4, 1993, pp. 467-471. doi:10.1016/S0749-8063(05)80324-X.
24. T. F. Higgins, J. Klatt and K. N. Bachus, "Biomechanical Analysis of Bicondylar Tibial Plateau Fixation: How Does Lateral Locking Plate Fixation Compare to Dual Plate Fixation?" *Journal of Orthopaedic Trauma*, Vol. 21, No. 5, 2007, pp. 301-306. doi:10.1097/BOT.0b013e3180500359.
25. H. Barbary, H. A. Ghani, H. Misbah and K. Salem, "Complex Tibial Plateau Fractures Treated with Ilizarov External Fixator with or without Minimal Internal Fixation," *International Orthopaedics*, Vol. 29, No. 3, 2005, pp. 182-185. doi:10.1007/s00264-005-0638-6.
26. H. M. Ariffin, N. M. Mahdi, S. A. Rhani, A. Baharudin and M. H. Shukur, "Modified Hybrid Fixator for High Energy Schatzker V and VI Tibial Plateau Fractures," *Strategies Trauma Limb Reconstruct*, Vol. 6, No. 1, 2011, pp. 21-26. doi:10.1007/s11751-011-0105-4.
27. T. M. McLaurin, "Hybrid Ring External Fixation in the Treatment of Complex Tibial Plateau Fractures," *Techniques in Knee Surgery*, Vol. 4, 2005, pp. 226-236. doi:10.1097/01.btk.0000187517.87625.3b.
28. J. A. Hall, M. J. Beuerlein and M. D. McKee, "Open Reduction and Internal Fixation Compared with Circular Fixator Application for Bicondylar Tibial Plateau Fractures," *The Journal of Bone and Joint Surgery. American Volume*, Vol. 1, No. 91, 2009, pp. 74-88.
29. D. Mahadeva, M. L. Costa and A. Gaffey, "Open Reduction and Internal Fixation versus Hybrid Fixation for Bicondylar/Severe Tibial Plateau Fractures: A Systematic Review of the Literature," *Archives of Orthopaedic and Trauma Surgery*, Vol. 128, No. 10, 2008, pp. 1169-1175. doi:10.1007/s00402-007-0520-7.
30. J. A. Lee, S. A. Papadakis, C. Moon and C. G. Zalavras, "Tibial Plateau Fractures Treated with the Less Invasive Stabilization System," *International Orthopaedics*, Vol. 31, No. 3, 2007, pp. 415-418. doi:10.1007/s00264-006-0176-x.
31. J. P. Stannard, T. C. Wilson, D. A. Volgas and J. E. Alonso, "The Less Invasive Stabilization System in the Treatment of Complex Fractures of the Tibial Plateau: Short- Term Results," *Journal of Orthopaedic Trauma*, Vol. 18, No. 8, 2004, pp. 552-558. doi:10.1097/00005131-200409000-00012.
32. S. N. Shah and M. A. Karunakar, "Early Wound Complications after Operative Treatment of High Energy Tibial Plateau Fractures through Two Incisions," *Bulletin of the NYU Hospital for Joint Diseases*, Vol. 65, No. 2, 2007, pp. 115-119.