

## Outcome of distal femoral fracture fixation with distal femoral locking compression plate using MIPPO technique

Gudaru Jagadesh<sup>1</sup>, Deepak Kaki<sup>2,\*</sup>, J. Srumith Kumar<sup>3</sup>

<sup>1</sup>Professor, <sup>2</sup>Assistant Professor, Dept. of Orthopaedics, BIRRD(T) Hospital, Tirupathi, Andhra Pradesh, <sup>3</sup>Junior Consultant, Dr. Muthus Ortho Hospital, Coimbatore

**\*Corresponding Author:**

Email: doc\_deep@yahoo.com

### Introduction

Fractures of distal femur historically have been difficult to treat. These fractures are usually unstable and comminuted and have potential to produce long term disability when treated non-operatively. Their management evokes controversy because of the poor results obtained and they are notorious for many complications. A refined understanding of bone biology and the role of tissue vascularity and gap strain in fracture healing, contributed to the development of the use of locked plate technology<sup>(1,2)</sup> and the concept of bridging plate osteosynthesis.

Biomechanically, the locked plate system is designed to convert the shear forces experienced at the implant with the application of load into compressive forces at the screw bone interface.<sup>(1,4)</sup> This conversion of shear forces into compressive forces is beneficial because cortical bone is stronger against the compressive forces than the shear forces.

The angular stability of locked screws allows the applied load to be more evenly distributed amongst the component screws, avoiding significant load concentration at a single screw-bone interface.<sup>(1,5,6)</sup> This provides better stability in osteoporotic bones. Locking plates and associated insertion guides adapted for minimally invasive insertion techniques facilitate closed indirect reduction of metaphyseal fragments and maintain the soft tissue attachments to bone thereby preserving blood supply.<sup>(7,8)</sup> The combination of excellent stability provided by locking compression plates and minimally invasive insertion technique lead to improved outcome of the distal femoral fractures over previously used implants.

In high-energy distal femoral fractures, the soft tissue envelope is extensively damaged and conventional plating which requires excessive dissection will further damage blood supply to bone. This explains why conventional treatment of these fractures has been associated with a high rate of wound complications and deep sepsis.<sup>(3)</sup> Efforts to preserve the soft tissue envelope around the fracture led to the development of minimally invasive percutaneous plate osteosynthesis (MIPPO) technique. This technique causes minimal disturbance of biology, retains fracture hematoma,<sup>(8)</sup> reduces risk of infection and non union, enables early mobilization and faster rehabilitation.<sup>(9)</sup>

The purpose of our study is to determine the clinical outcome, radiological outcome and complications of distal femoral fractures fixation with Distal Femoral Locking Compression Plate (DF-LCP) using MIPPO technique.

### Materials and Methods

Our study was held between October 2012 and October 2014 at BIRRD[T] Hospital, Tirupati. In this study of 20 patients with distal femur fractures, we included adults above 18 years; type A and C fractures according to AO classification and osteoporotic fractures. Out of 20 patients, 7 were males and 13 were females, showing a preponderance of females. The average age of all the patients was 49.4 years (range 18 to 85 years).(Table 1) Mode of injury was domestic fall in 65% patients and road traffic accidents in 35% of patients. Domestic fall was the most common cause of injury for distal femur fractures in elderly females. We found a right sided preponderance in our study with 60% of right sided and 40% of left sided involvement. Radiographs were taken of the affected femur including knee to study the fracture configuration (Fig. a, b). Muller's comprehensive classification system was used to classify the fractures. All the fractures of type A and C were in almost equal distribution and were of closed type. Regarding Co morbidities, in our study 5 patients had diabetes mellitus, 6 had hypertension, one had hypothyroidism and rheumatoid arthritis and one had rheumatoid arthritis alone. Two of them were operated for fracture neck of femur by Austin Moore prosthesis previously. One patient was a known case of post polio residual paralysis of left lower limb and had distal femur fracture on the same side.

Associated injuries were seen in 4 patients; 2 patients had patella fracture on the same side for which tension band wiring was done, one had humerus fracture for which DCP plating done and one had fracture both bones forearm and haemothorax on same side for which DCP plating and ICD insertion was done respectively.

All patients were operated under combined spinal epidural anaesthesia. We used DF-LCP (Synthes inc., Bettlach, Switzerland) in all the patients. The size of the plate used in our study was based on plate span width and screw density quotients, so as to increase the working length which increases inter fragmentary

motion and callus formation. Primary bone grafting was not done in any patient.

**Surgical Technique:** Surgery was done on a radiolucent table under C-arm guidance with the patient in supine position. A bolster was placed under the knee, to overcome the pull of gastrocnemius on the distal fragment. Minimal access lateral approach to the distal femur was used. A lateral skin incision of 3 to 5 cm length was given over the lateral condyle, iliotibial band incised in the same line and vastus lateralis gently elevated from the femoral shaft to facilitate submuscular plate placement. If necessary, arthrotomy was performed to ensure anatomic reduction of articular fragments. Following reduction of articular fragments, lag screw fixation was carried out when required, with partially threaded cancellous bone screws reconstructing these fragments into single articular block.

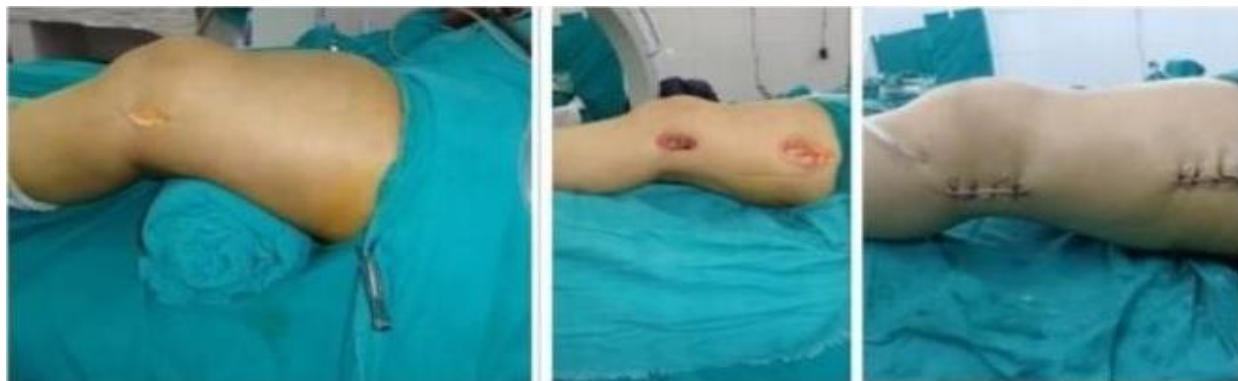The ideal plate length was determined by the plate span width and the plate screw density. The plate span width is the quotient of plate length divided by overall fracture length.<sup>(10)</sup> The screw density is the quotient of number of screws inserted divided by number of plate holes; this value should be under 0.4-0.5.<sup>(11)</sup> These factors were considered in order to maintain a favourable working length.

After sliding the plate, K-wires were used in the distal fragment to anchor the plate temporarily to the bone. A small lateral incision was given in the proximal thigh for plate adjustment and screw placement.

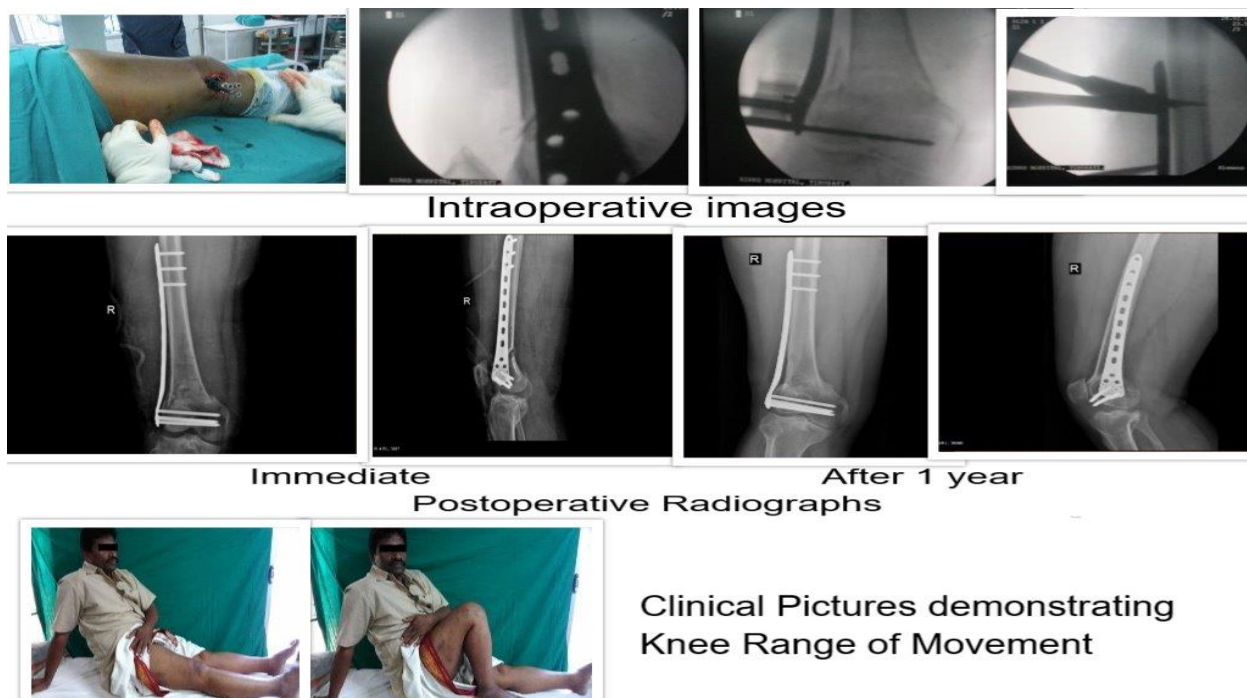
Manual traction was applied to the ankle with the knee in flexion to reduce the fracture and restore limb length, rotational and axial alignment. Attention was given for restoration of medial and lateral columns. In case of oblique metaphyseal fractures, to facilitate the reduction, a single lag screw was inserted across the fragments. Reduction in coronal & sagittal planes was achieved and then stabilised with the plate. When required, the standard screws were used to draw the bone to the plate for proper alignment of the fragments. A threaded drill sleeve was used for accurate drilling of screw holes and therefore proper alignment of screws for proper mating of the plate and screw threads. The locking head screws were inserted into the distal fragment. Care was taken so that the screws did not enter the intercondylar notch. The locking head screws were inserted bicortically in to the proximal fragment. A torque limiting screw driver was to be used for screw insertion.

Active knee mobilisation and Quadriceps strengthening exercises were started on the first postoperative day. Toe touch weight bearing was allowed with the aid of a walker. Partial weight bearing was permitted at 6 weeks postoperatively and then progressed to full weight bearing at around 8 to 12 weeks depending on the clinical and radiological progress of union.

Post operatively, all the patients were followed up for every 6 weeks till union, thereafter for every 3 months upto 1 year and then for every 6 months.



Intraoperative positioning, Incision Placement



## Results

In our study 70% of the patients were aged above 50 years and domestic fall was the most common cause of fracture. The mean duration of surgery was 99.5 mins (range 80-150 mins). The mean follow up period was 16 months (range 12 to 24 months). The average time for union was 15.7 weeks (range 12-20 weeks). Union time was longer in type C2 and C3 as compared to other types. More the comminution more is the time taken for radiological union. The average range of motion of the knee joint was  $1^{\circ}$ - $116^{\circ}$ (range 0- $140^{\circ}$ ). Full weight bearing was achieved by 4 to 5 months in 75% of patients. 90% of the patients have returned to their regular work.

Complications include deep infection seen in 1(5%) patient managed by wound wash out and IV antibiotics, valgus malalignment of  $15^{\circ}$  and 2 cm shortening in 1(5%) patient, valgus malalignment of  $10^{\circ}$  and 0.5 cm shortening in 1(5%) patient, and valgus malalignment of  $5^{\circ}$  and 0.5 cm shortening in 1(5%) patient. Overall complication rate in our study was 20%.

There were no cases of screw backing out, non union, nerve injury, implant failure, implant removal due to iliotibial band pain or compartment syndrome, as reported by other studies. In our study, we had excellent results in 12(60%) patients, good results in 6(30%) and fair results in 2(10%) patients according to Neer's Criteria.<sup>(12)</sup> (Table 2)

**Table 1: Patient demographics - October 2012 and October 2014**

No	Age	sex	AO type	Full wt bear (mnths)	union (wks)	F/up (mths)	Complications	Neer's score
1	59	F	33C1	3	12	17	Nil	Excellent
2	55	F	33A2	3	12	12	Nil	Excellent
3	55	F	33A1	3	14	24	Nil	Good
4	33	F	33C2	5	20	13	$10^{\circ}$ Valgus angulation, 0.5 cm Shortening	Fair
5	44	M	33A3	5	18	18	Nil	Excellent
6	58	F	33A3	4	15	13	Nil	Excellent
7	53	M	33C3	5	20	15	infection	Excellent
8	22	F	33A1	3	12	20	Nil	Excellent
9	85	F	33A1	4	16	17	Nil	Excellent
10	50	F	33A2	12	16	16	Nil	Fair
11	67	F	33A2	4	16	11	Nil	Good
12	62	F	33C1	4	14	19	Nil	Excellent
13	52	M	33A3	4	14	20	0.5 cm Shortening,	Good

							5° Valgus	
14	65	F	33A2	4	16	12	Nil	Good
15	56	M	33C2	4	18	16	15° Valgus, Shortening 2 cm	Good
16	26	M	33C1	4	16	15	Nil	Excellent
17	19	F	33C3	4	16	16	Nil	Excellent
18	18	M	33C2	4	14	18	Nil	Excellent
19	60	F	33C1	4	16	16	Nil	Excellent
20	50	M	33C2	5	20	12	Nil	Good

Table 2: NEER'S Criteria

<b>I) Functional (70 points)</b>	
<b>a) Pain (20 points)</b> <ul style="list-style-type: none"> <li>No pain -20</li> <li>Intermittent -16</li> <li>With fatigue- 12</li> <li>Limits function - 8</li> <li>Constant or at exertion - 4-0</li> </ul>	<b>c) Joint movement (20 points)</b> <ul style="list-style-type: none"> <li>Normal or 135 degrees- 20</li> <li>Up to 100 degrees- 16</li> <li>Up to 80 degrees- 12</li> <li>Up to 60 degrees- 8</li> <li>Up to 40 degrees- 4</li> <li>Up to 20 degrees- 0</li> </ul>
<b>b) Walking capacity (20 points)</b> <ul style="list-style-type: none"> <li>Same as before accident- 20</li> <li>Mild restriction - 16</li> <li>Restricted stair side ways- 12</li> <li>Use crutches or other walking aids- 4-0.</li> </ul>	<b>d) Work capacity (10 points)</b> <ul style="list-style-type: none"> <li>Same as before accident- 10</li> <li>Regular but with handicap- 8</li> <li>Alter work- 6</li> <li>Light work- 4</li> <li>No work- 2-0</li> </ul>
<b>II) Anatomical (30 points)</b>	
<b>a) Gross anatomy (15 points)</b> <ul style="list-style-type: none"> <li>Thickening only – 15</li> <li>5 degree angulation or 0.5 cm shortening- 12</li> <li>10 degree angulation or rotation, 2 cm shortening- 9</li> <li>15 degree angulation or rotation, 3 cm shortening - 6</li> <li>Healed with considerable deformity- 3</li> <li>Non-union or chronic infection - 0</li> </ul>	<b>b) Roentgenogram (15 points)</b> <ul style="list-style-type: none"> <li>Near normal 15</li> <li>5 degree angulation or 0.5 cm displacement- 12</li> <li>10 degree angulation or 1 cm displacement-9</li> <li>15 degree angulation or 2 cm displacement- 6</li> <li>Union but with greater deformity, spreading of condyles and osteoarthritis- 3</li> <li>Non-union or chronic infection- 0</li> </ul>

Excellent..... More than 85 points  
 Good ..... 70 to 85 points  
 Fair..... 55 to 69 points  
 Poor..... Less than 55 points

### Discussion

Current fracture patterns showing complex comminuted types and osteoporotic fractures of the distal femur led to the increased use of distal femur locking compression plates (DF-LCP).

Conventional screw-plate systems (condylar buttress plates and dynamic condylar screws) depend on the bone-plate interface for stability.<sup>(13,14,15)</sup> The stability of the standard screw depends on bone quality. In metaphyseal comminution, the holding power of the screw is compromised leading to failure of the screw-plate system. In addition, such systems have technical problems such as primary and secondary loss of reduction and compression of the periosteum leading to

disturbance of the cortical blood supply.<sup>(16)</sup> Soft-tissue stripping during conventional plating adds a biologic insult to the poor bone quality as in metaphyseal comminution and osteoporotic bones. These may lead to poor outcomes such as non-union, implant failure, malunion, and infection.<sup>(17)</sup>

Locking plate systems such as the Less Invasive Stabilization System (LISS) have been extensively used for distal femoral fractures.<sup>(18)</sup> The LCP differs from the LISS in that the LCP has combination holes<sup>(19)</sup> and does not have a jig.<sup>(18)</sup> The 'Combi hole' of LCP has compression component and locking component.

The LCP is a single beam construct where the strength of its fixation is equal to the sum of all screw-bone interfaces rather than a single screw's axial stiffness and pullout resistance in unlocked plates.<sup>(1)</sup> Its unique biomechanical function is based on splinting rather than compression resulting in relative stability,

avoidance of stress shielding and induction of callus formation.<sup>(18)</sup>

V. Sharma et al,<sup>(21)</sup> studied 29 distal femoral fractures and 12 periprosthetic fractures treated using distal femur LCP. Excellent to good Knee Society score was achieved in 82 percent of cases. Fair to poor score was seen in 18 percent of cases. Excellent to good Knee Society score was achieved in 82 percent of cases. Fair to poor score was seen in 18 percent of cases.

Jain JK et al,<sup>(22)</sup> studied on 20 distal femoral and 20 proximal tibial fractures which were fixed using LCPs. The average Knee Society scores were 82.66 (excellent) and 77.77 (functional score- good). (Table 3)

Our results were better than studies using DF-LCP with open technique in terms of surgical time, early mobilization, requirement for bone grafting, union time and union rate.

**Table 3: Comparison of results of distal femoral fractures treated with locking plates**

Author	No.	Open #s (%)	Age	F/up (months)	Rom <sup>0</sup> (%)	Time to Union (WKS)	Bone Graft	Complications (%)				Scoring System	Excellent and Good Results (%)
								Deep Infection	Revision Loose/Broken	Removal Due to pain	Malalignment		
Schandelmaier et al	54	18.5	N/A	6	104	14.3	-	1.9	7.4	-	13	NEER	N/A
Schutz et al	99	29	54	13.7	0-107	N/A	6	7	6	-	1	-	-
Fankhauser et al	30	46.7	57	20	4-113	12	-	-	10	23.3	-	KSS	65.50
Kregor et al	103	34	52	14	1-109	12	7	3	5	3	6	-	-
Markmiller et al	20	N/A	57	12	0-110	13.8	-	-	10	-	15	LYSHOLM	87.5
Weight and Collinge	22	27	44	18	5-114	13	-	-	-	18.2	13.6	-	-
Schutz et al	66	32	52	12	112	N/A	9	3	4.5	-	37	-	-
Wong et al	16	-	75	23	N/A	30	-	-	12.5	-	-	OXFORD	76.6
Yeap and Deepak	11	36	44	9.7	1-107.7	18	18.2	-	9	-	9	SCHATZKER	72.7
Jain JK et al	20	-	37.05	12	95.83	15.2	-	5	10	-	5	KSS	82
Our Study	20	N/A	49.4	16	1-116	15.7	-	5	-	-	15	NEER	90

Starr AJ et al<sup>(23)</sup> described the Swashbuckler approach which is a modified anterior approach for distal femoral fractures. This is very useful in distal femoral fractures especially in those with intraarticular extension. A midline skin incision is utilized which extends from the tibial tuberosity proximally upto one third length of the thigh. The vastus fascia is incised, vastus lateralis is lifted off the lateral intermuscular septum which exposes the distal femur and both the condyles. The advantages of this approach are the excellent exposure of the entire distal femoral articular surface, sparing of the quadriceps mechanism and no hindrance to any future knee arthroplasty. However, the extensive soft tissue dissection may cause higher blood loss, decrease periosteal perfusion and further hamper the chances of fracture union.<sup>(24)</sup> These limitations dissuaded us from using this approach.

When applied using minimally invasive technique, DF-LCP increases the chances of healing, reduces the need for bone grafting, decreases infection rate as blood supply is preserved.

Abdel-Rahman et al,<sup>(25)</sup> evaluated the results of minimally invasive percutaneous plate osteosynthesis (MIPPO) of distal femoral fractures in elderly diabetic patients with osteoporotic bone and had 69% of excellent to good results with 15.3% complication rate.

Ravi MN et al,<sup>(26)</sup> reported that in their study on treatment of distal femur fractures by LCP using MIPPO technique and had 93.5% good to excellent results and 20% complication rate. (Table 4)

**Table 4: Comparison of results of distal femoral fractures treated with DF-LCP using MIPPO technique**

Variable	Abdel-Rahaman et al (2010)	Ravi MN et al (2011)	Our Study
No. of patients	13	31	20
Min Age	62	21	18
Max Age	74	65	85
Male	1	22	7
Female	12	9	13

Fracture Type	Closed	28- Closed, 3- Open	Closed
Mean operating time	100 mins	70 mins	99.5 mins
Mean follow up period	22.4 months	18 months	16 months
Mean time of union	6.3 months	3.7 months	3.9 months
Complications	15.30%	20%	20%
Results	69% Good and Excellent	93.5% Good and Excellent	90% Good and Excellent

Stress moment concentration occurs in short spanned segments and may result in failure of construct.<sup>(27)</sup> Shorter working lengths are associated with non-unions.<sup>(28)</sup> The adequate working length which enables flexible fixation enhancing callus formation is obtained by leaving 3 to 4 vacant holes at the level of fracture site.<sup>(11,29)</sup>

We had comparable results with the studies using DF-LCP and MIPPO technique.

Depending on the fracture situation, DF-LCP can be used as a bridge plate, as a compression plate, or combining both techniques. The DF-LCP should be considered an internal fixator. Its placement is analogous to placement of an external fixator where in it stabilizes the fracture reduction that has been previously achieved.

### Conclusion

Distal Femoral Locking compression plate (DF-LCP) is a good fixation system for distal femur fractures. Use of DF- LCP with MIPPO technique reduces the need for bone grafting. It provides better fixation of fracture in elderly patients with Osteoporosis. Aim must be to achieve length, axis and rotation by maintaining the biology at fracture site. Careful attention should be given to restoring alignment in all planes. Optimal Working length and screw placement are crucial factors for preventing implant failure and nonunion. Post-operative early mobilization of the knee gives good range of motion. Use of DF-LCP is associated with fewer complications.

### References

- Egol KA, Kubiak EN, Fulkerson E, et al. Biomechanics of locked plates and screws. *J Orthop Trauma*. 2004; 488-93.
- Perren SM. Evolution and rationale of locked internal fixator technology. Introductory remarks. *Injury*. 2001;32(Suppl 2):B3-9.
- Lachiewicz PF, Funcik T. Factors influencing the results of open reduction and internal fixation of tibial plateau fractures. *Clin Orthop Relat Res*, 1990;259:210-215.
- Gardner MJ, Brophy RH, Campbell D, et al. The mechanical behavior of locking compression plates compared with dynamic compression plates in a cadaver radius model. *J Orthop Trauma*. 2005;19:597-603.
- Gardner MJ, Helfet DL, Lorich DG. Has locked plating completely replaced conventional plating? *Am J Orthop*. 2004;33:439-446.
- Cordey J, Borgeaud M, Perren SM. Force transfer between the plate and the bone: relative importance of the bending stiffness of the screws friction between plate and bone. *Injury*. 2000;31(Suppl 3):C21-C28.

- Perren SM. Evolution of the internal fixation of long bone fractures. The scientific basis of biological internal fixation: choosing a new balance between stability and biology. *J Bone Joint Surg Br*. 2002;84: 1093-1110.
- Kregor PJ, Stannard J, Zlowodzki M, et al. Distal femoral fracture fixation utilizing the Less Invasive Stabilization System (LISS): the technique and early results. *Injury*. 2001;32(Suppl 3):SC32-SC47.
- Syed AA, Agarwal M, Giannoudis PV, et al. Distal femoral fractures: long-term outcome following stabilisation with the LISS. *Injury, Int. J. Care Injured* (2004) 35, 599—607.
- Gautier E, Sommer C. Guidelines for the clinical application of LCP. *Injury, Int. J. care injured* 34 (2003) B63-B76.
- Stoffel K, Dieter U, Stachowiak G, Gächter A, Kuster MS: Biomechanical testing of the LCP—how can stability in locked internal fixators be controlled? *Injury* 2003, 34(Suppl 2):B11–B19.
- Neer CS, Grantham SA, Shelton ML. Supracondylar fracture of the adult femur. *J Bone Joint Surg Am* 1967;49:591-613.
- Higgins TF. Distal femoral fractures. *J Knee Surg* 2007;20:56-66.
- Schatzker J, Tile M. The rationale of operative fracture care. Berlin: Springer Verlag; 1987.
- Klaue K. Principles of plate and screw osteosynthesis. In: Bulstrode C, Buckwalter J, Carr A, editors. Oxford textbook of orthopaedics and trauma. Oxford: Oxford University Press; 2002:1697-710.
- Frigg R, Frenk A, Haas NP, Regazzoni P. LCP. The Locking Compression Plate system. In: Colton CL, editor. AO Dialogue. Vol 14(1). Davos/Dubendorf: AO Publishing;2001:16-7.
- Greiwe RM, Archdeacon MT. Locking plate technology: current concepts. *J Knee Surg* 2007;20:50-5.
- Frigg R, Appenzeller A, Christensen R, Frenk A, Gilbert S, Schavan R. The development of the distal femur Less Invasive Stabilization System (LISS). *Injury* 2001;32(Suppl 3):SC24-31.
- Wagner M. General principles for the clinical use of the LCP. *Injury* 2003;34(Suppl 2):B31 42.
- Kregor PJ, Stannard JA, Zlowodzki M, Cole PA. Treatment of Distal Femur Fractures Using the Less Invasive Stabilization System: Surgical Experience and Early Clinical Results in 103 Fractures. *J Orthop Trauma* 2004; 18(8): 509-20.
- Sharma V, Gale, Mansouri R, Maqsood M. use of distal femoral LCP in the fractures of distal femur and periprosthetic fractures- functional and radiological results in 41 consecutive cases. *J Bone Joint Surg Br*. 2010;92-B(IV):559.
- Jain JK, Asif N, Ahmad S, Qureshi O, Siddiqui YS, Rana A. Locked compression plating for peri- and intra-articular fractures around the knee. *Orthop Surg*. 2013 Nov;5(4):255-60.
- Starr AJ: The “Swashbuckler”: A modified Anterior approach for fractures of the distal femur. *Journal of Orthop Trauma* 1999 Feb;13(2):138-40.
- Beltran MJ et al: Articular exposure with the swashbuckler vs a “Mini – swashbuckler” approach.

## Injury

(2012),<http://dx.doi.org/10.1016/j.injury.2012.10.021>

25. Abdel R, Adham E. Treatment of distal femoral fractures in elderly diabetic patients using minimally invasive percutaneous plating osteosynthesis (MIPPO). *Acta Orthop. Belg.* 2010;76:503-506.
26. Ravi MN, Koichade MR, Alok NU, Milind VI. Minimally invasive plate osteosynthesis using a locking compression plate for distal femoral fractures. *Journal of Orthopaedic Surgery* 2011;19(2):185-90.
27. Strauss EJ, Schwarzkopf R, Kummer F, Egol KA: The current status of locked plating: the good, the bad, and the ugly. *J Orthop Trauma* 2008,22:479-486.
28. Hoffmann MF, Clifford BJ, Debra LS. Clinical outcomes of locked plating of distal femoral fractures in a retrospective cohort. *Journal of Orthopaedic Surgery and Research* 2013, 8:43.
29. Smith WR, Ziran BH, Anglen JO, Stahel PF: Locking plates: tips and tricks. *J Bone Joint Surg Am* 2007, 89:2298-2307.