

## Functional outcome of Primary total knee replacement in severe flexion deformity and without flexion deformity knee – A comparative study

Mukesh Kumar<sup>1,\*</sup>, Vinod Padmanabhan<sup>2</sup>

<sup>1</sup>Assistant Professor, MMIMSR, Mullana, Ambala, Haryana, <sup>2</sup>Consultant, Dept. of Orthopedics, Sree Sudheendra Medical Mission, Kochi, Kerala

**\*Corresponding Author:**

Email: mukeshmedico@gmail.com

### Abstract

**Aims & Objectives:** To know the functional outcome of Primary TKR in Severe fixed flexion deformity of knee compared with TKR in knees without fixed flexion deformity (FFD).

**Materials & Methods:** This is a prospective study of the patients with severe flexion deformity and without FFD of knees underwent primary TKR between 2009-2014. Total of 45 knees were taken for the study with 22 with FFD of more than 30 degree and 23 were without FFD which were kept as a control. This study includes both inflammatory and non-inflammatory arthritis.

**Results:** Primary TKR in FFD - Average FFD was 46 degree, Pre-operative average KSS-pain score was 28 and functional score was 12, post operatively KSS pain score was 83.2 and function score was 78.3. There was significant difference in pain score and patient's satisfaction in patients with inflammatory arthritis (though the number were less) than non-inflammatory arthritis.

The postoperative KSS- pain and functional score, in patients with no FFD was comparable with patients with FFD and there was no significant difference.

**Conclusion:** Patients with severe FFD knees perform same as patients with knees without FFD. Finally, patient with severe FFD and Inflammatory arthritis are happier than patient without FFD knees in midterm follow up.

**Level of Evidence:** II

**Keywords:** FFD(fixed flexion deformity), Total Knee Replacement, Knee society score.

### Introduction

Fixed flexion deformities are a combination of ligamentous, capsular and bony deformity having an adverse effect on knee biomechanics, increasing the forces across the patellofemoral and tibiofemoral joints.<sup>(1)</sup> The presence of fixed flexion deformities has been reported in up to 61% of knees undergoing primary TKA.<sup>(3)</sup> Study has demonstrated that preoperative range of motion (ROM) was the strongest predictor of postoperative ROM.<sup>(2)</sup>

If the knee is unable to fully extend, increased demand is placed on the Quadriceps because they are required to stabilize the flexed knee at heel strike and during the stance phase.<sup>(5,6,9)</sup> Impaired function may result from increased energy requirements and earlier fatigue of the quadriceps, causing functional impairment, limping gait, decreased walking distance or problems with sporting or leisure activities.<sup>(6,9)</sup> Trunk alignment may also be affected by a fixed flexion deformity, altering the kinematics of the spine.<sup>(7)</sup> The use of computer navigation appears to be a more accurate method for assessing the degree of knee flexion, with a reduced range of error compared with clinical assessment.<sup>(8)</sup>

Incomplete intraoperative correction of severe flexion deformity would lead to more residual flexion contracture postoperatively.<sup>(10)</sup>

In spite of full intraoperative correction flexion contracture can reoccur postoperatively in some cases.<sup>(16-18)</sup>

Study by Rao et al.<sup>(19)</sup> has demonstrated that severity of preoperative fixed flexion deformity is very significant factor influencing the development of recurrence of FFD of postoperatively. Chance of developing recurrence of FFD was more in non-obese patients compared to obese patients; postoperative restriction of flexion was not significantly associated with recurrence of FFD. Preoperative and postoperative coronal plane deformities were not significantly associated with recurrence of FFD.

Although some contractures after TKR may eventually resolve,<sup>(13)</sup> if the lack of extension is greater than 15° three months postoperatively, it is likely to persist.<sup>(14)</sup>

It is recommended to limit bone resection with mandatory release of the posterior capsule and the collateral ligaments to get the knee straight in the operation and stable in the postoperatively in the most severe cases.<sup>(15)</sup>

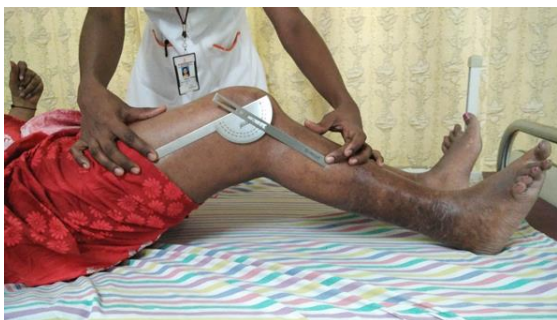This study by Cheng et al<sup>(11)</sup> concluded that patients with a preoperative fixed flexion deformity show continued improvement in their fixed flexion up to ten years' post arthroplasty and have similar outcomes to those with no preoperative fixed flexion.

Muzaffar et al<sup>(12)</sup> demonstrated that preservation of tibia with increased distal femur cut and upsizing of femur component may occasionally be required to achieve proper balancing the knee.

## Materials & Methods

This is a prospective study of the patients with severe flexion deformity and without FFD of knees underwent primary TKR between 2009-2014. Total of 45 knees were taken for the study with 22 with FFD of more than 30 degree and 23 were without FFD which were kept as a control. This study includes both inflammatory and non-inflammatory arthritis.

We recorded the preoperative ROM, KSS-Pain and functional score of all patients; all patients were evaluated with radiographs of knee AP/lateral and whole leg (if patients were able to stand). Clinical measurement of FFD was done with goniometer one limb of goniometer along the long axis of tibia and another limb along long axis of femur directed towards greater trochanter (Fig. 1). All patients were started on preoperative physiotherapy for at least of 4 weeks (average 6 weeks), all the cases were operated by single surgeon with MBK (Mobile bearing knee) or FBK (Fixed bearing knee) and data was recorded at follow up at 6 weeks, 12 weeks, 6 months and then yearly. At every follow up, patient's KSS(Pain and functional score) were recorded.



**Fig. 1:** Photo showing measurement of FFD by goniometer with one limb of goniometer along the long axis of tibia and another limb along long axis of femur directed towards greater trochanter

**Surgical Technique:** All patients were operated by standard midline incision with medial parapatellar approach, FFD was corrected by removing posterior osteophytes, posterior capsular release, gastrocnemius release and additional distal femoral cut if required. Hamstring muscles were released in few cases. We tried to correct deformity completely on table. Navigation was not used in any of our cases. Drain was put in all the cases; Standard post TKR rehabilitation program was followed in all cases.

**Statistical Analysis:** Statistical analysis was done by paired T test for the normal variables and Wilcoxon signed rank test for the non-normal variables.

## Results

There were 12 bilateral cases and 10 unilateral cases. 12 knees were inflammatory arthritis and 10 with non-inflammatory arthritis. There were 9 females and 7 male patients. Average age of the patients was 56.5 years

(25-68 years). Average follow up was 2.5 years (1-6 years).

In Primary TKR in FFD - Average FFD was 46 degree, Pre-operative average KSS-pain score was 28 and functional score was 12, post operatively KSS pain score was 83.2 and function score was 78.3. There was significant difference in pain score and patient's satisfaction in patients with inflammatory arthritis (though the number were less) than non-inflammatory arthritis.

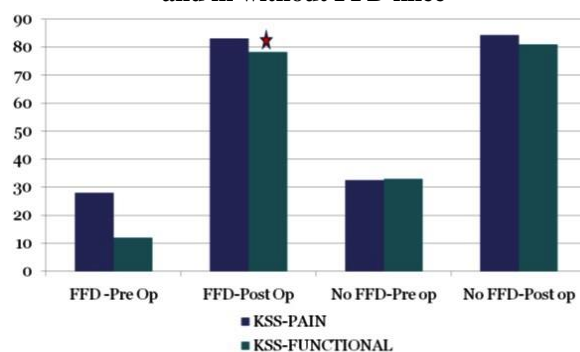
The postoperative KSS- pain and functional score, in patients with no FFD was comparable with patients with FFD and there was no significant difference.

There was 1 case of superficial wound infection in posterior wound in patients with JRA in which Hamstring release was done which was treated with antibiotics and saline dressing and wound healed.

There was no case of deep infection in any of the patients with FFD, no injury to peroneal nerve, no radiological signs of loosening.

Residual FFD was present in 5 knees which were corrected fully by 3 months, hamstrings were released in 3 knees, and electrical stimulation to quadriceps was given in 5 knees.

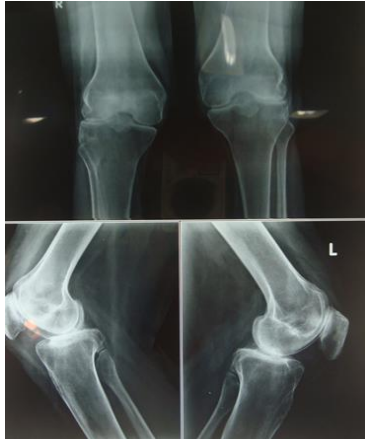**Graph: Showing comparison of preoperative and postoperative pain and functional score in FFD knee and in without FFD knee**



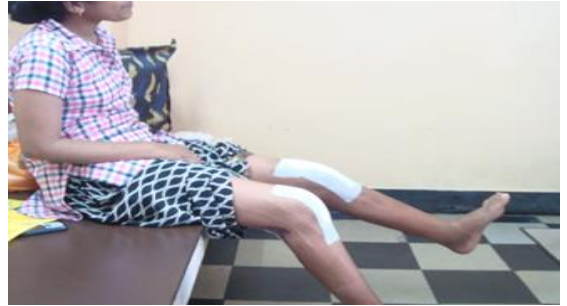## Case 1



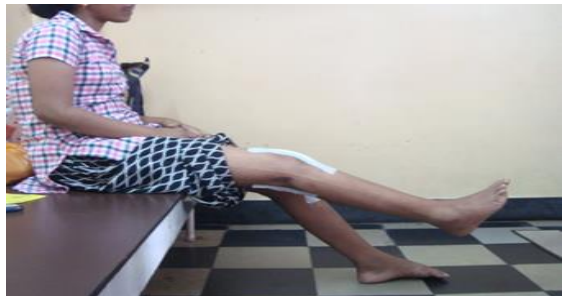**Fig. 2:** Photos showing severe fixed flexion deformity of both knee in 25 years old RA patient



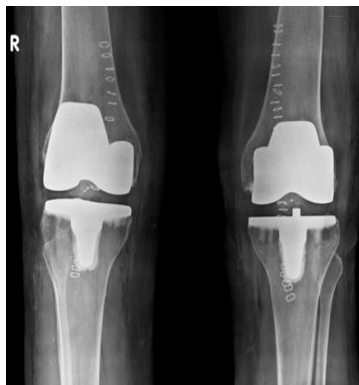**Fig. 3: Radiographs of Knee AP/LAT showing concentric narrowing of joint space known case of RA**



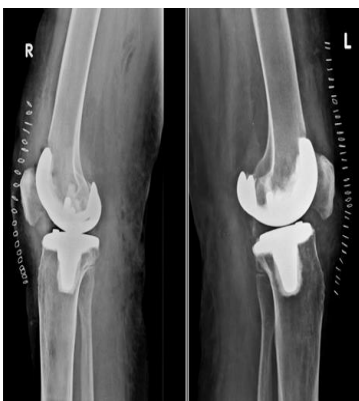**Fig. 6: Clinical Photos of a patient showing residual FFD in left knee at 2 weeks of follow up**



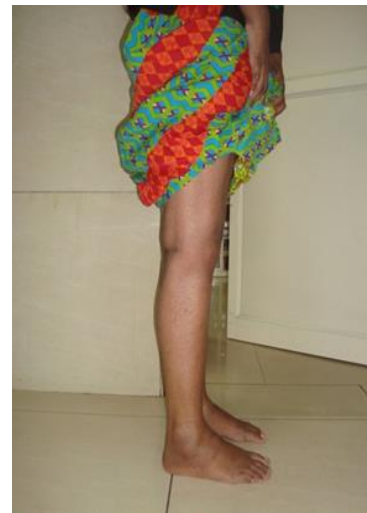**Fig. 7: Clinical Photos of a patient showing residual FFD in right knee at 2 weeks of follow up**



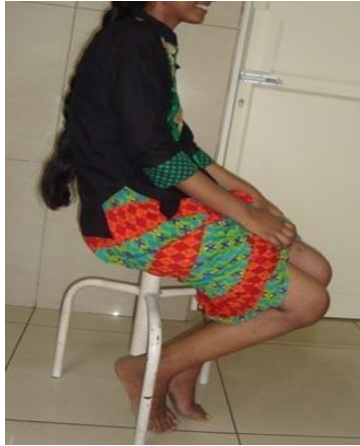**Fig. 4: Radiographs of both Knee immediate post-operative- AP view showing Implant in situ**



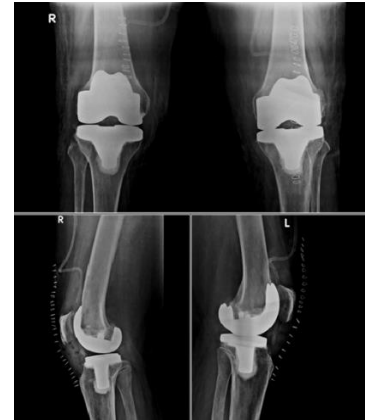**Fig. 5: Radiographs of both Knee immediate post-operative- lateral view showing Implant in situ**



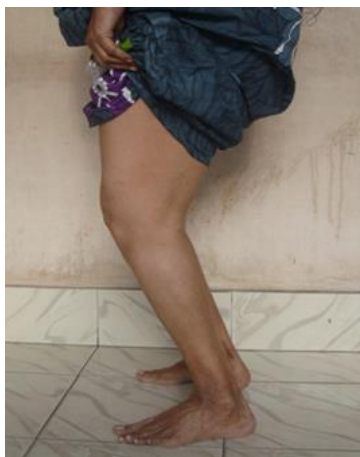**Fig. 8: Photos of a patient showing fully corrected FFD at one year follow up**



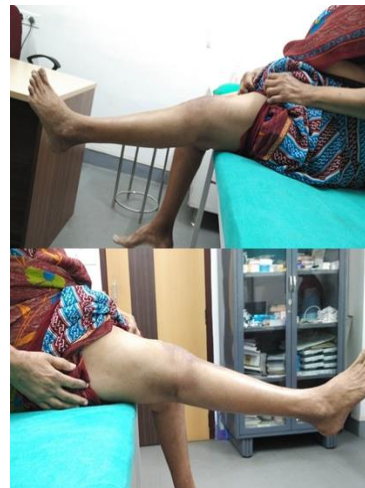**Fig. 9: Photos of a patient showing flexion of both knee at one year follow up**  
Case 2



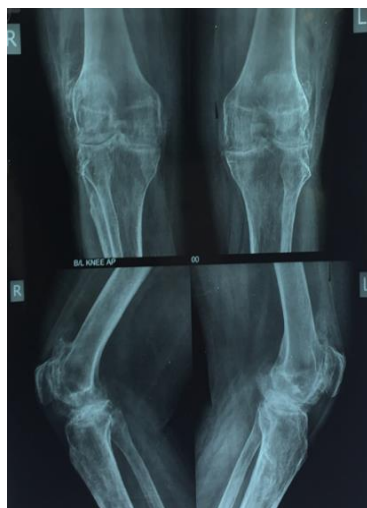**Fig. 12: Radiographs of both Knee immediate post-operative– AP and Lat view showing Implant in situ**



**Fig. 10: photos showing severe fixed flexion deformity of both knee in 55 years old patient**



**Fig. 13: Clinical Photos of a patient showing fully corrected FFD at one year follow up**



**Fig. 11: Radiographs of Knee AP/LAT showing concentric narrowing of joint space, osteopenia and osteophytes involving all three compartment of knee in known case of RA**

### Conclusion

Patients with severe FFD knees perform same as patients with knees without FFD. Finally, patient with severe FFD and Inflammatory arthritis are happier than patient without FFD knees in midterm follow up.

### Discussion

The definition of a knee flexion contracture is a knee that is unable to fully extend to 0°, either actively or passively.

The etiology of a pre-operative fixed flexion deformity is multifactorial; bony impingement, posterior capsular contracture, hamstring shortening, and ligament contracture all contribute to the inability to fully straighten the knee.

Residual flexion contractures after TKA can create similar problems and forces upon the contralateral limb. Using gait and force plate analysis, Harato et al<sup>(20)</sup> confirmed that there was greater force placed on the contralateral knee if a flexion contracture persisted after TKA.

Most flexion contractures are caused by tight collateral ligaments and posterior capsule, and often are worsened by osteophytes impingement under these ligaments. The first step in treating flexion contracture is thorough removal of osteophytes. Then the ligaments should be assessed. Tight ligaments then should be released until the ligaments are properly balanced, and again the flexion contracture should be reassessed. Almost all flexion contracture is alleviated by ligament balancing, leaving very few knees in need of resection of more distal femoral bone.

After TKR, residual flexion contractures are associated with poorer clinical scores and greater forces upon the contralateral knee. Clearly, flexion deformities must be corrected post- TKR and the correction maintained in order to maximize functional results after surgery. The algorithm for correcting a fixed flexion deformity begins with the recognition of the problem pre-operatively.

A significant interaction between the groups was observed for fixed flexion, total range of movement and Knee Society scores at the one year. This suggests that those with a preexisting FFD demonstrated a greater improvement in the first year, which could be explained by the fact that this group started off worse and improved significantly due to the correction of their fixed flexion deformity.

According to Shurman et al<sup>(16)</sup> and Firestone et al,<sup>(4)</sup> virtually all improvement in flexion contracture occurred at the time of surgery only. We have found that up to 15 degree of residual flexion contracture corrected fully at the end of 12<sup>th</sup> months.

Our study also has shown that there was no significant difference in outcomes of knees with severe FFD and knees without FFD, there was significant improvement in functional outcome of patients with FFD as the preoperatively KSS –functional score was very low as compare to the knees without FFD. Patient with inflammatory arthritis had better satisfaction score compared to the non-inflammatory arthritis.

**Conflict of Interest:** Nil

## References

- Swanson SAV (1980) Biomechanics. In: Aubriot H, Freeman MAR (eds) Arthritis of the knee: clinical features and surgical management. Springer-Verlag, Berlin, pp 1–30.
- Ritter MA, Harty LD, Davis KE, Meding JB, Berend ME (2003) Predicting range of motion after total knee arthroplasty. Clustering, log-linear regression, and regression tree analysis. *J Bone Joint Surg Am* 85-A:1278–1285.
- Tew M, Forster IW (1987) Effect of knee replacement on flexion deformity. *J Bone Joint Surg Br* 69:395–399.
- Firestone TP, Krackow KA, Davis JD IV. The management of fixed flexion contracture during total knee arthroplasty, *Orthopaedics*, 1990;13:643-9.
- Laskin RS, Beksac B. Stiffness after total knee arthroplasty. *J Arthroplasty* 2004;19(Suppl 1):41-6.
- McPherson EJ, Cushner FD, Schiff CF, et al. Natural history of uncorrected fixed flexion contracture following total knee arthroplasty. *J Arthroplasty* 1994;9:499-502.
- Harato K, Nagura T, Matsumoto H, et al. A gait analysis of simulated knee flexion contracture to elucidate knee-spine syndrome. *Gait Posture* 2008;28:687–692.
- Price A.M, Gallie, Edward T. Davis, Kelly Macgroarty, James P. Waddell, Emil H. Schemitsch, Computer-assisted navigation for the assessment of fixed flexion in knee arthroplasty, *Can J Surg*, Vol. 53, No. 1, February 2010, 42-46.
- Bhave A, Mont M, Tennin S, et al. Functional problems and treatment solutions after total hip and knee joint arthroplasty. *J Bone Joint Surg Am* 2005;87:9-21.
- Sarokhan AJ, Scott RD, Thomas WH, Sledge CB, Ewald FC, Cloos DW: Total knee arthroplasty in juvenile rheumatoid arthritis. *J Bone Joint Surg Am* 1983;65(8):1071–1080.
- Cheng K, Ridley D, Bird J, McLeod G: Patients with fixed flexion deformity after total knee arthroplasty do just as well as those without: ten-year prospective data. *Int Orthop* 2010;34(5):663–667.
- N.Muzaffar, J-R Yoon, Y.B Kim, Knee replacement in severe flexion deformity: The role of release and cut, *Journal of orthopedics*, Vol.3 No.-1 3-8 (2011).
- Quah C, Swamy G, Lewis J, Kendrew J, Badhe N. Fixed flexion deformity following total knee arthroplasty: a prospective study of the natural history. *Knee* 2011; (Epub ahead of print).
- Mitsuyasu H, Matsuda S, Miura H, et al. Flexion contracture persists if the contracture is more than 15° at 3 months after total knee arthroplasty. *J Arthroplasty* 2011;26:639–643.
- Koshino T, Okamoto R, Takagi T, Yamamoto K, Saito T: Cemented ceramic YMCK total knee arthroplasty in patients with severe rheumatoid arthritis. *J Arthroplasty* 2002;17(8):1009–1015.
- Scheurman DJ, Parkar JN, Ornstein D. Total Condylar Knee Replacement. *J Bone Joint Surg(Am)*. 1985;67:1006-14.
- Tew M, Forster IWE, Effect of flexion deformity. *J Bone Joint Surg(Br)*. 1987;69-B:395—9.
- Tanzer M, Miller J. The natural history of flexion contracture in total knee arthroplasty. *Clin Orthop*. 1989;248:129-34.
- SPB Rao, Jaswant Rai, Factor influencing recurrence of fixed flexion deformity after total knee arthroplasty, *Indian journal of orthopaedics*; October 2004, Vol 38: P. 235-238.
- Harato K, Nagura T, Matsumoto H, et al. Extension limitation in standing affects weight-bearing asymmetry after unilateral total knee arthroplasty. *J Arthroplasty* 2010;25:225–229.