

Traumatic rupture of the extensor pollicis longus tendon due to hyperextension of wrist

Nitin Bhimrao Patil¹, Prashant Alwani^{2,*}, Jayesh Pawar³, Yogesh Narkhede⁴

¹Associate Professor, ^{2,3,4}Resident, Dept. of Orthopaedics, KIMS, Karad, Maharashtra

***Corresponding Author:**

Email: drprashantalwani@yahoo.com

Abstract

A case of a traumatic rupture of the EPL tendon due to sudden extreme hyperextension of wrist, where the tendon was crushed between the Lister's tubercle and the base of the third metacarpal was encountered. The patient didn't have history of rheumatoid arthritis or steroid injection or any wrist fracture. During surgery, the EPL tendon was found to be ruptured at the level of the lister's tubercle and direct repair was not possible. Reconstruction of the extensor tendon using the palmaris longus tendon was performed. At the 24-months follow-up, the patient showed satisfactory extension of the thumb at interphalangeal joint and full extension and flexion at the wrist.

Keywords: Extensor pollicis longus, Tendon rupture, Traumatic rupture, Hyperextension of wrist, Palmaris longus

Introduction

A spontaneous rupture of the extensor pollicis longus (EPL) tendon is associated fractures around wrist, local steroid injections, rheumatoid arthritis and repetitive abnormal movements at the wrist joint. Here we encountered a case of a traumatic rupture of the EPL tendon due to sudden extreme hyperextension of wrist, where the tendon was crushed between the Lister's tubercle and the base of the third metacarpal. The patient didn't have history of rheumatoid arthritis or steroid injection or any wrist fracture. During surgery, the EPL tendon was found to be ruptured at the level of the lister's tubercle and direct repair was not possible. Reconstruction of the extensor tendon using the palmaris longus tendon was performed. At the 24-months follow-up, the patient showed satisfactory extension of the thumb at interphalangeal joint and full extension and flexion at the wrist.

Case Report

A 25-year-old male patient visited our clinic with complaints of right wrist pain and an inability to extend the interphalangeal joint of right thumb. The pain in the right wrist and thumb started 15 days before the visit. He had history of trauma to wrist as his hand got trapped in car door 15 days before he came to hospital. He had no history of rheumatoid arthritis, wrist pain, or steroid injection. He had been working as a driver for 3 years. On local examination there was moderate swelling and tenderness at lister's tubercle. Flexion at interphalangeal joint of the thumb was possible but active extension was not. On radiograph there was no sign of fracture around wrist or at lister's tubercle. The clinical findings clearly indicated an acute rupture of the EPL tendon. Thus surgery was planned without MRI or USG.

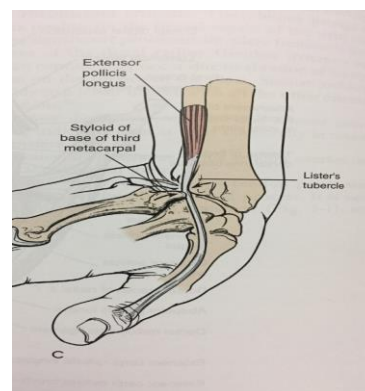


Fig. 1: Mechanism of Injury

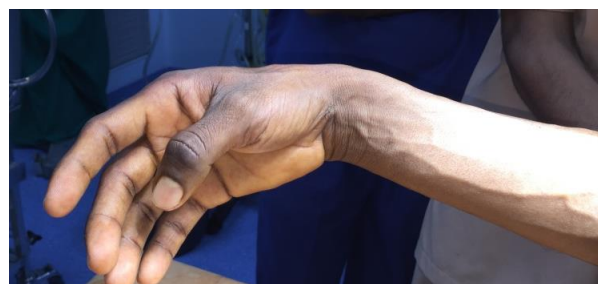

Fig. 2: Pre op Thumb Attitude showing flexion at interphalangeal joint

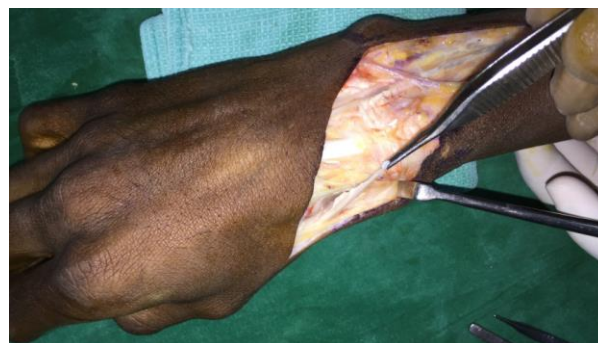

Fig. 3: Distal cut end of the tendon

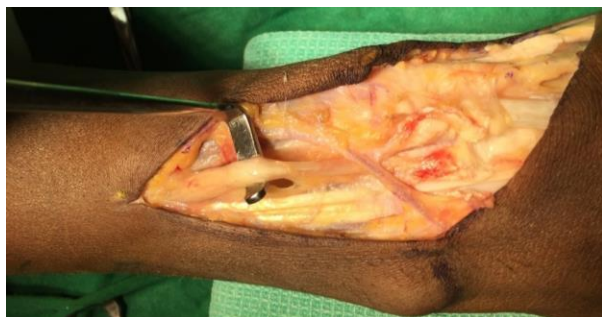

Fig. 4: Proximal atrophied cut end and muscle belly

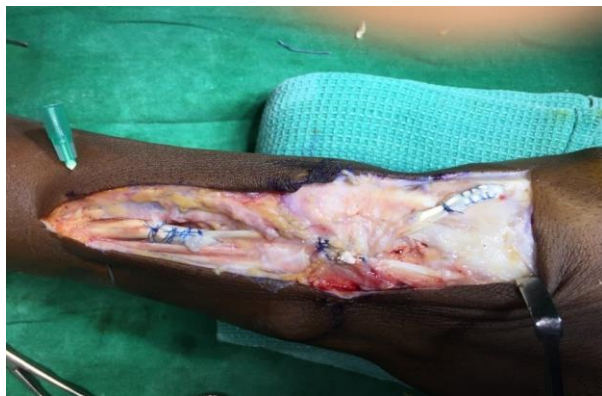

Fig. 5: Repair with Palmaris Longus graft and creating a tunnel

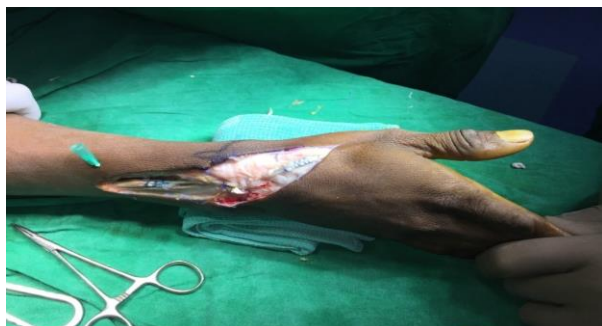

Fig. 6: Immediate Post Op Thumb Attitude

Surgical Technique: An incision was made from the base of the thumb curving it at Lister's tubercle and extending it straight towards mid forearm keeping it fully pronated. The extensor retinaculum was identified and cut and the third compartment consisting of EPL tendon was reached. The ruptured ends of tendon were identified where the distal end was found attenuated at base of thumb and proximal end was atrophied near the muscle belly. Tenosynovitis and synovitis around the Lister's tubercle was not present. An interposition graft reconstruction was done using a palmaris longus tendon graft because the injured tendon could not be repaired end-to-end. Second incision was taken over volar aspect of the same wrist and the palmaris longus tendon graft was obtained with length adequate enough for end to end suturing. The atrophic and degenerative areas at the proximal and distal stumps of the ruptured tendon were

removed. The graft obtained from the ipsilateral palmaris longus tendon was attached to the EPL tendon. The distal end of the graft was sutured to the distal stump of the EPL tendon using Side to Side Suture technique, the tendon was now placed around the Lister's tubercle thus creating the tunnel and the extensor retinaculum was now resutured, then the proximal end of the graft was sutured to the muscle belly of the EPL by Pulvertaft's technique. During the procedure, tension was adjusted to keep interphalangeal joint in extension and also wrist in extension. Postoperatively, a short-arm plaster splint was applied to the wrist in extension and the thumb in abduction and extension. After suture removal a thumb spica cast was applied with the thumb in extension for 6 postoperative weeks and physiotherapy and a rehabilitation program were started thereafter. The range of extension of the thumb at interphalangeal joint was satisfactory at the 2nd postoperative month, which then increased to a normal level at the last follow-up (24 months after surgery), thus leading to high patient satisfaction.

Discussion

This unusual injury was probably a result of the sudden dorsiflexion of wrist, the EPL tendon was trapped or crushed between the Lister's tubercle and base of third metacarpal. Hirasawa et al.⁽¹⁾ showed that the EPL tendon is poorly vascularised around Lister's tubercle, which is the usual location of EPL ruptures. Thus options are direct repair, tendon grafting, or tendon transfer. Attrition ruptures of tendons are rarely suitable for direct repair, thus a tendon graft is needed for end to end repair. Spontaneous rupture of the EPL tendon in wrist fractures is very common. Spontaneous rupture of the EPL tendon can also be caused by tophaceous gout infiltration,⁽²⁾ ankylosing spondylitis, wrist fractures, bone spurs developing after metastatic distal radius or scaphoid fractures, misplaced external fixators or metal plates, non-metastatic distal radius or scaphoid fractures,⁽³⁻⁵⁾ prolonged non-union of the scaphoid, dorsal subluxation of the distal ulna after trauma, and Madelung's deformity.⁽⁶⁾ In contrast, there are some reports concerning EPL tendon ruptures caused by repeated abnormal movements of the wrist joint.⁽⁷⁾

Our patient had alleged history of his hand getting trapped in car door. He had been working as a driver for 3 years. This injury was probably a result of sudden extreme hyperextension of wrist, where the tendon was trapped or crushed between the Lister's tubercle and the base of the third metacarpal. The end to end repair was performed using palmaris longus graft and thus patient recovered without any functional limitation to thumb or other joints. The palmaris longus tendon transfer is recommended by most surgeons when direct repair of the extensor pollicis longus is not possible, as it has an appropriate direction and excursion. The reported problem with the use of EIP (Extensor Indicis Propius) is weakness and extensor lag of the index finger.⁽⁸⁾ Thus

palmaris longus graft is recommended for repair of EPL as no functional limitation is noted.

Conclusion

The EPL tendon is always associated with attrition rupture thus rendering it unable for direct repair. The end to end repair of tendon is advised by using Palmaris longus graft as no functional limitation to the wrist and thumb movements was observed.

References

1. Hirasawa Y, Katsumi Y, Akiyoshi T, et al. Clinical and microangiographic studies on rupture of the E.P.L. tendon after distal radial fractures. *J Hand Surg.* 1990;15B:51-57.
2. Hung JY, Wang SJ, Wu SS. Spontaneous rupture of extensor pollicis longus tendon with tophaceous gout infiltration. *Arch Orthop Trauma Surg.* 2005;125(4):281-4.
3. Bonatz E, Kramer TD, Masear VR. Rupture of the extensor pollicis longus tendon. *Am J Orthop (Belle Mead NJ).* 1996;25(2):118-22.
4. Hove LM. Delayed rupture of the thumb extensor tendon: a 5-year study of 18 consecutive cases. *Acta Orthop Scand.* 1994;65(2):199-203.
5. Payne AJ, Harris NJ, Kehoe NJ. Bilateral delayed extensor pollicis longus rupture following bilateral undisplaced distal radial fractures. *Orthopedics.* 2000;23(2):163.
6. Harvey FJ, Harvey PM. Three rare causes of extensor tendon rupture. *J Hand Surg Am.* 1989;14(6):957-62.
7. Anwar I, Owers KL, Eckersley R. Spontaneous rupture of the extensor pollicis longus tendon. *J Hand Surg Br.* 2006;31(4):457-8.
8. Levine J, Schneider M. Spontaneous rupture of the extensor pollicis longus tendon following the fracture of the carpal navicularbone. *J Bone Joint Surg [Am]* 1955;37:364-5.