

## The underutilised modality of radiation synovectomy in management of chronic inflammatory arthritis in the Himalayan State of India: Concepts & A brief review

Mohit Dhingra<sup>1</sup>, Vandana Dhingra<sup>2,\*</sup>, Ashutosh Panday<sup>3</sup>

<sup>1</sup>Assistant Professor, Dept. of Orthopedics, SGRR, Dehradun, Uttarakhand, <sup>2</sup>Associate Professor, <sup>3</sup>Technologist, Dept. of Nuclear Medicine, AIIMS, Rishikesh, Uttarakhand

**\*Corresponding Author:**  
Email: modisbanu@yahoo.com

### Abstract

Arthritis carries significant morbidity in populations across the world and also in India. The arthritis of the inflammatory variety can be managed with medications and synovectomy if severe. Intraarticular radioisotope colloid also known as radiation synovectomy have shown good results in management of inflammatory arthritis in majority of literature. This modality remains underutilised in the Himalayan State of India mainly due to lack of awareness and availability issues, hence we bring forth the practical aspects of radiation synovectomy and discuss literature in this brief review.

**Keywords:** Inflammatory arthritis, Radiation synovectomy, Himalayan State, India

### Introduction

Arthritis, especially rheumatoid arthritis, is a common, chronic disease and systemic and local drug treatments are used. Disease modifying anti-rheumatic drugs in rheumatoid arthritis or non-steroidal anti-inflammatory drugs in poly-arthritis are therapeutic options in these conditions, including biologics and systemic steroid administration.<sup>(1)</sup> In cases with persistent synovitis local steroid injection, or surgical, chemical or radiation synovectomy may be an option. The intra-articular administration of steroid is a fast and safe procedure, but the long-term response is limited. Surgical synovectomy is associated with a high cost and longer time of rehabilitation. Different drugs were used for the chemical synovectomy, e.g. rifampicin as an antibiotic or osmium acid. Especially the chemical synovectomy using osmium acid is painful, and the long-term response is relatively low.

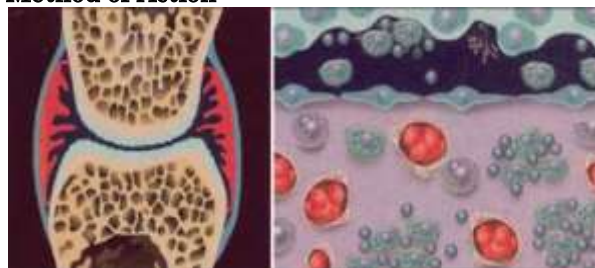
### Radiosynovectomy Basic Concepts

Radiosynovectomy is a well-established therapy in arthritis and involves an intra-articular injection of small radioactive particles to treat a synovitis. The intra-articular injection of beta-emitting radionuclides (e.g. colloidal preparations of <sup>90</sup>-Yttrium, <sup>186</sup>-Rhenium or <sup>169</sup>-Erbium), is an approved, reliable and easily performed therapy for the treatment of chronic synovitis without harmful side effects.<sup>(2)</sup>

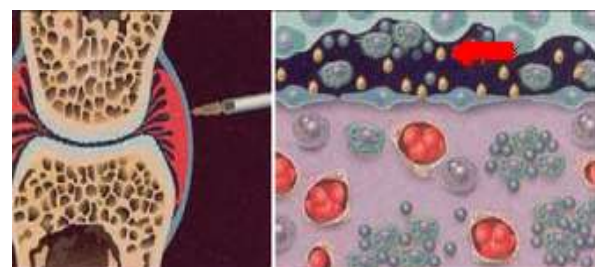
It is performed in a Nuclear Medicine facility which deals with internal administration of radioisotopes for diagnosis and therapy.

Radioisotope synovectomy/ Radiosynovectomy is defined as the intra-articular injection of radioisotopic agents with the aim of fibrosis on hypertrophic synovium in the target joint (Fig. 1-4).

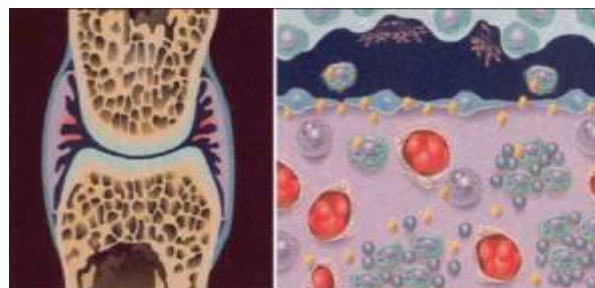
### Method of Action



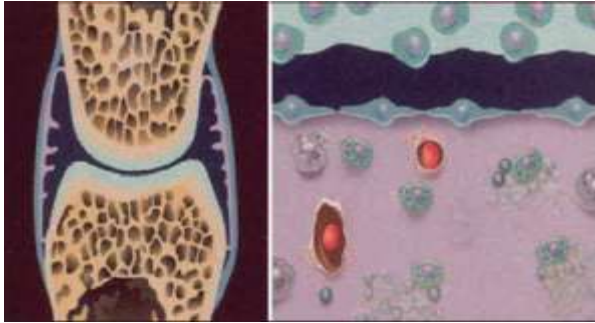
**Fig. 1: Typically in rheumatoid arthritis and poly-arthritis a proliferation of synovia with increasing numbers of macrophages is seen. (Adapted from Liepe Knut)**



**Fig. 2: Small particles (arrow) with a size >2 μm applied intra-articularly with homogeneous distribution in the joint cavity**



**Fig. 3: Complete uptake of radio-colloids in the synovia with phagocytosis in macrophages and other inflammatory cells within 48 hours**



**Fig. 4: Long-term the radiation leads to fibrosis of inflammatory synovia and clinical response**

Frequent indications are rheumatoid and polyarthritis. In developing countries with low availability of clotting factors the radiosynovectomy represent a cost effective therapeutic option for repeated bleedings in hemophilic arthropathy. The special focus in these countries is maintaining of mobility and work ability.<sup>(3)</sup> The knee and medium joints (ankle, elbow and arthritis, shoulder) are treated using yttrium-90, rhenium-186 or

phosphorus-32. Small joints are treated using Erbium-169 (Table 1).

The best clinical results have been obtained in patients with predominantly inflammatory joint disease such as rheumatoid arthritis or reactive arthritis. But radiosynovectomy is also established to treat pain and persistent effusions after total knee replacement.

It also represents an adjuvant therapy in patients with pigmented villonodular synovitis to protect against recurrence following synovectomy. In patients with hemophilia and arthropathy a reduction in joint bleeding is seen and the use of coagulation factor is reduced. The indication for radiosynovectomy should be made in close cooperation between the referring physician, the rheumatologist and the nuclear medicine expert in the context of a multimodal therapy concept. In this way, success rates of over 80%, with only few side effects, can be achieved, particularly in rheumatoid arthritis, reactive arthritis and haemophilic arthropathy.<sup>(4)</sup>

**Table 1: Radioisotope characteristics of commonly used isotopes for radiosynovectomy**

	<b>Yttrium-90</b>	<b>Rhenium-186</b>	<b>Erbium-169</b>	<b>Phosphorus-32</b>
Physical T <sup>1/2</sup>	2.7 days	3.7 days	9.5 days	0.6 days
Maximum of beta-energy (MeV)	2.26	1.07	0.34	1.71
Gamma-energy (keV)	No	137	No	No
Maximum of tissue penetration (mm)	11.0	3.7	1.0	7.9
Mean of tissue penetration (mm)	2.8	1.0	0.3	2.2
Mean particle size (µm)	2	1-2	0.05-0.5	6-20
Chemical labelling at	Citrate	Sulfate	Citrate	Chromic

#### Indications:

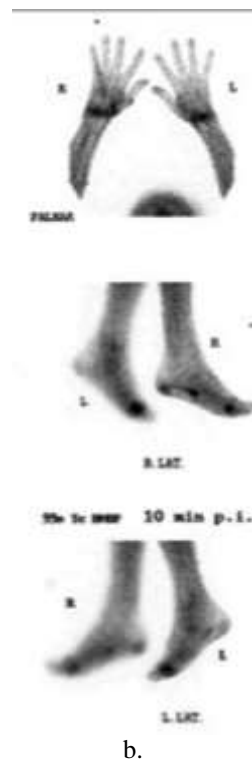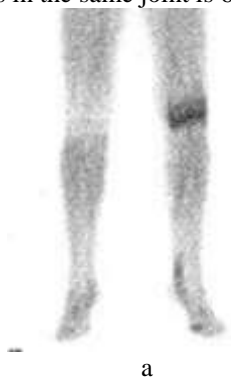<sup>90</sup>Y silicate/citrate, <sup>186</sup>Re sulphide and <sup>169</sup>Er citrate are indicated for the treatment of joint pain arising from arthropathies including:<sup>(2)</sup>

- rheumatoid arthritis
- spondylarthropathy (e.g. reactive or psoriatic arthritis)
- other inflammatory joint diseases e.g. Lyme disease, Behcet's disease
- persistent synovial effusion
- haemophilic arthritis
- calcium pyrophosphate dihydrate (CPPD) arthritis
- pigmented villonodular synovitis (PVNS)
- persistent effusion after joint prosthesis
- undifferentiated arthritis (where the arthritis is characterised by synovitis, synovial thickening or effusion).

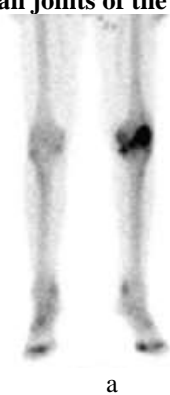#### Procedure:

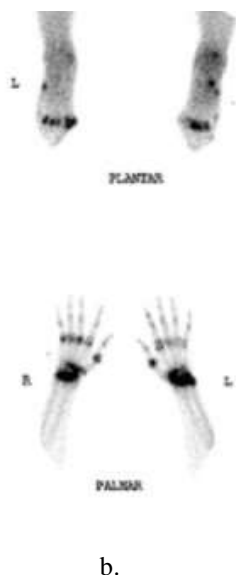1. Patients considered for intra articular <sup>90</sup>-Y silicate/citrate, <sup>186</sup>-Re sulphide or <sup>169</sup>-Er citrate therapy will have failed at least one intra-articular injection of long-acting glucocorticoid (e.g. methylprednisolone acetate or triamcinolone). Pain will usually be severe enough to limit normal activities and/or require regular analgesics.

2. Radiographs of the joints to be treated should be obtained and reviewed prior to undertaking radiosynovectomy. Weight-bearing views of lower limb joints should be requested specifically. Symptoms attributable largely or exclusively to cartilage damage are unlikely to benefit from radiosynovectomy.
3. Additional imaging procedures useful in planning radiosynovectomy:
  - Scintigraphic assessment of soft tissues and severity of active inflammation (e.g. by 3-(2-)phase 99mTcMDP/HDP/HEDP bone scintigraphy and/or 99mTc-HIGscintigraphy) of the affected joints (fig 5a &b).
  - Ultrasound - to evaluate synovial structure and Thickness and exclude ruptured Baker's cyst.
  - Magnetic resonance imaging of the affected joint.
4. Time interval between arthroscopy or joint surgery and radiosynovectomy should be (2-6) weeks and between joint puncture and radiosynovectomy 2 weeks. The minimum interval between repeated treatments in the same joint is 6 months.<sup>(5)</sup>



**Fig. 5a, b: Planning of radiosynovectomy: Early phase of bone scan depicting increased blood pooling (inflammation) in the left knee (a) bilateral wrist and small joints of the hands and feet(b)**





**Fig. 6 a, b: Delayed phase of whole body bone scan in the same patient depicting increased joint uptake (arthritis) in the left knee (a), bilateral wrists and small joints of the hands and feet (b)**

**Administration**

1. Joint puncture for radiosynovectomy carries the same risk as any joint puncture and should follow the rules of strict asepsis.
2. Local skin anaesthesia is advisable.
3. Correct deposition and homogeneous distribution of the radiopharmaceutical agent in the joint space is essential. Puncture of all joints other than knee should be performed under fluoroscopic (X-Ray screening) or ultrasound guidance. The knee can routinely be injected without imaging guidance (Fig. 4).
4. If imaging guidance is not used (e.g. knee) then radiopharmaceuticals should not be injected unless intra- articular needle placement has been ensured by aspiration of joint fluid through the needle which is being used to inject the radiopharmaceutical.
5. A particle size of at least 5-10 nm is essential to avoid leakage.
6. Absolute immobilization of the treated joint(s) for 48 hour radiosynovectomy using splints or bed rest is recommended as this will reduce transport of particles through the lymphatics to the regional lymph nodes.
7. Where possible, simultaneous administration of intra articular long acting glucocorticoids (e.g. methylprednisolone or triamcinolone) is recommended to reduce the risk/severity of acute synovitis and to improve treatment response. (e.g. triamcinolone acetonide 40mg [1ml] for the knee, hip or shoulder or 20mg [0.5ml] for elbow, ankle, wrist or subtalar joints).

8. The needle through which the radiopharmaceutical has been injected should be flushed before and during withdrawal with 0.9% saline.

**Instructions for patients**

The importance of joint immobilisation following treatment should be emphasised. The treating clinician must advise the patient on reducing unnecessary radiation exposure to family members and the public. Written instructions should be provided where required.<sup>(2)</sup>

Following treatment, patients should avoid pregnancy for at least 4 months.

If inpatient treatment is required, nursing personnel must be instructed in radiation safety. Any significant medical conditions should be noted and contingency plans made in case radiation precautions must be breached for a medical emergency. Concern about radiation exposure should not interfere with the prompt appropriate medical treatment of the patient.

Joint	Administered Radioactivity MBq(mCi)	Recommended Volume
Hip	74-185 (2-5)	3ml
Shoulder	74-185(2-5)	3ml
Elbow	74-111(2)	1-2ml
Wrist	37-74(102)	1-1.5ml
Ankle	74(2)	1-1.5ml
Subtalar	37-74(1-2)	1-1.5ml

**Side effects**

1. Early: Increased synovitis – temporary
2. Late: Radionecrosis – rare

**Follow up:**

1. Post therapy imaging should be undertaken, where possible, to confirm appropriate radiopharmaceutical distribution within the treated joint space.
2. Patients should be reviewed 6-8 weeks after injection. Review should include clinical and laboratory indices of treatment response, assessment of synovial inflammation and of possible radionecrosis.
3. In cases where clinical evaluation cannot provide reliable indication of failure/response and where appropriate pre-injection MR/ultrasound data are available, further MR/ultrasound may be of value to document changes in synovial volume and/or vascularity.
4. Clinical examination and ultrasound should be repeated at 3-4 months/6 months and 12 months after treatment.
5. Pain reduction typically occurs 1-3 weeks post injection. Treatment failure is likely if no response is detected by 6 weeks post injection.
6. A few patients who have failed to respond to the first radionuclide injection report pain reduction

and improvement of joint function following re-treatment 6 months later. Two failed injections should not be followed by subsequent radiosynovectomy treatments.

### Brief Review of Literature

Rheumatoid arthritis is characterized by hyperplastic synovium, production of cytokines, chemokines, autoantibodies like rheumatoid factor and anticitrullinated protein antibody, osteoclastogenesis, angiogenesis and systemic consequences like cardiovascular, pulmonary, psychological, and skeletal disorders.<sup>(6)</sup>

Rheumatic diseases are a major cause of morbidity in India. Lack of adequate manpower and training facilities, staggering costs of therapy and unique problems like burden of infectious diseases challenge adequate management of rheumatic diseases in the country.<sup>(7)</sup> Even though there have been seen multiple studies on this subject, limited evidence/literature is available regarding radiosynovectomy from India, PUBMED shows about ten articles when key words radiation synovectomy and India are searched.

Radiation Synovectomy has been used since early 1950 in the treatment of resistant synovitis for individual joints where other form of therapy has failed.<sup>(8)</sup> It has been shown to be very efficacious in relieving the symptoms in 60–80% of cases.<sup>(9)</sup> A wide variety of radiopharmaceuticals in colloidal form have been used for different joints depending upon their size.<sup>(10)</sup>

Pharmacotherapy is the first line of treatment for inflammatory synovitis. In the case of pharmacotherapy failure, other methods which directly remove the inflamed synovial membrane are used – “synovectomies” (from Greek: synovium – synovial membrane, ectomia – ectomy or cutting). There are chemical, radioisotope and surgical synovectomies. Surgical synovectomy is the surgical removal of inflammatory synovium during arthroscopy or open surgery synovectomy. In chemical and radioisotope synovectomy, for the knee joint cavity an appropriate substance is given, such as Aethoxysklerol in chemical synovectomy.<sup>(11)</sup>

Even though few studies do report inefficacies in treatment with radiosynovectomy, overall results have been promising over the years.

In many studies decrease in pain and improvement of joint movement upto 44% have been observed and are key indicators and observations in most successful radiosynovectomies. However, they obtained a decrease of pain in 43.5% two weeks after treatment and a 20% decrease at the last visit. They also noted an increase of percentage in the group with complete resolution of pain from 8.5% 2 weeks after treatment to 60% one year after treatment and a decrease of inflammatory fluid evacuated from the joint during subsequent punctures.<sup>(11)</sup>

A rare side effect is necrosis of surrounding tissue caused by leakage of the radionuclide. When these lesions are recognized early surgical therapy or hyperbaric oxygen therapy can be initiated.<sup>(12)</sup>

Radiation Synovectomy in the Himalayan state of Uttarakhand in India:

Though significant prevalence of debilitating Rheumatoid disorders exists in India, there are few studies on this subject in India and much work needs to be done.<sup>(7)</sup> Especially in the state of Uttarakhand which has less than four Nuclear Medicine facilities, which provide diagnostic and radioiodine therapy but none of which currently provide radiosynovectomy, literature is scant in this context.<sup>(13)</sup> Hence, although it has promising clinical results, the advantage of therapy on outpatient basis, main challenges remain availability of therapy and knowledge regarding the same. Many orthopaedic surgeons are not aware of the advantages of radiosynovectomy and are underutilized even if available. More work needs to be done in providing the facility as well as spreading awareness regarding the procedure and its benefits. We propose that Rheumatologists, Orthopedic surgeons and Nuclear Medicine specialists could work in a team and see benefits and challenges radiation synovectomy could pose in this region.

### Conclusion

Radiation synovectomy - an established modality of utilizing intra-articular injection of therapeutic radioisotopes - needs to be utilized optimally with proper patient selection, proper post procedure care and follow-up. It can prove to be a very cost effective and simple method for relieving pain and improving joint movement in patients with inflammatory arthritis. In the context of a resource challenged Himalayan State of India (Uttarakhand), work needs to be done in this field.

### References

1. Liepe Knut, Radiosynovectomy in the Therapeutic Management of Arthritis. *World J Nucl Med.* 2015 Jan-Apr;14(1):10–15.
2. Clunie G, Fischer M; EANM. EANM procedure guidelines for radiosynovectomy. *Eur J Nucl Med Mol Imaging.* 2003 Mar;30(3):BP12-6.
3. Peter Schneider, Jamshid Farahati and Christoph Reiners Radiosynovectomy in Rheumatology, Orthopedics, and Hemophilia *The Journal Of Nuclear Medicine.* Vol. 46 No. 1 (Suppl) January 2005.
4. Linke R, Gelse K, Schuch F. The indication for radiosynoviorthesis. From the perspective of the nuclear medicine expert, rheumatic orthopedist and internist. *Z Rheumatol.* 2011 Jan;70(1):34-44.
5. Markou P, Chatzopoulos D. Yttrium-90 silicate radiosynovectomy treatment of painful synovitis in knee osteoarthritis. Results after 6 months. *Hell J Nucl Med.* 2009 Jan-Apr;12(1):33-6.
6. Alam J, Jantan, Bukhari SNA, Rheumatoid arthritis: Recent advances on its etiology, role of cytokines and pharmacotherapy. *Biomed Pharmacother.* 2017 Jun 2;92:615-633.

7. Misra DP, Agarwal V, Negi VS .Rheumatology in India: a Bird's Eye View on Organization, Epidemiology, Training Programs and Publications. *J Korean Med Sci.* 2016 Jul;31(7):1013-9.
8. Fellingner K, Schmid J. Local therapy of rheumatic diseases. *Wien Z Inn Med.* 1952;33:351–63.
9. Deutsch E, Brodack JW, Deutsch KF. Radiation synovectomy revisited. *Eur J Nucl Med.* 1993;20:1113–27.
10. AshwaniSood, Aman Sharma, Devendra Kumar Chouhan et al. Failed Radiation Synovectomy in Diseased Knee Joint with Missed Tuberculous Synovitis. *World J Nucl Med.* 2016 Sep;15(3):206–208.
11. Joanna Zalewska, Małgorzata Węgierska, Tacjana Barczyńska, et al Efficacy of radiation synovectomy (radiosynovectomy or radiosynoviorthesis) with yttrium-90 in exudative inflammation of synovial membrane of knee joints in patients with rheumatic diseases – preliminary report. *Reumatologia* 2016;54,1:3–9.
12. Hartig I, Matveeva I, Braun M. Radionecrosis after radiation synovectomy. *Z Rheumatol.* 2016 Nov;75(9):943-944.
13. How a tertiary medical nuclear medicine department at the Himalayan area in India can be established and function in an exemplary manner. Basic rules revisited. Dhingra VK, Saini S, Basu S. *Hell J Nucl Med.* 2015 Sep-Dec;18(3):252-6.