

Role of Closed intramedullary Titanium Elastic Nailing in Fracture Shaft Femur in Children

V.P. Pathania¹, Saurabh Arora^{2*}, Sanjay Gupta³

¹Professor & Head, ²Junior Resident, ³Professor, Dept. of Orthopaedics, Shri Ram Murti Smarak Institute of Medical Sciences, Bareilly, Uttar Pradesh

***Corresponding Author:**

Email: arorabonehospital97@gmail.com

Abstract

Introduction: Fracture shaft femur is a common injury in children. The best treatment for children between 5 to 14 years of age is still debatable. The ideal device for the treatment of most displaced femoral fractures in children would be a simple, load-sharing internal splint that allows mobilization and maintenance of alignment and extremity length until bridging callus forms. Titanium elastic nails offer these features.

Aim and Objectives: To assess the functional and radiological outcome of closed reduction and internal fixation of fractures of shaft femur in children aged 5-14 years with TENS.

Materials and Methods: 30 patients were treated from November 2014 to July 2016 between age group of 5-14 years by retrograde TEN fixation.

Patients were mobilized without weight bearing on the 7th day post operatively. Partial weight bearing was started at 6 weeks and full weight bearing at 12 weeks depending on the fracture configuration, callus response and associated injuries. Follow up was done at 6 weeks, 12 weeks and 24 weeks.

Results: Average radiological union was seen in 12.8 weeks. Maximum patients achieved full range of hip and knee movements. Only two had knee stiffness. Based on Flynn's criteria 70% excellent and 30% good results were recorded.

Conclusion: Titanium Elastic Nailing system for the treatment of paediatric shaft femur fractures in the age group of 5-14 years is an effective method, as it avoids any growth disturbance by preserving the epiphyseal growth plate, and avoids bone damage or weakening through the elasticity of the construct.

Keywords: Titanium Elastic Nail (TEN), Flynn criteria, Retrograde, Shaft femur, Children.

Introduction

Fracture shaft femur is a common injury in children. The incidence in children is 20 in 1,00,000 in the United States and Europe (Poolman et al 2006).⁽¹⁾ The male to female ratio of femoral fracture is 2.6:1 with a bimodal distribution.⁽¹⁾

The mechanism of injury in femoral shaft fractures is largely correlated with age. High-energy trauma results in more significant fracture displacement.

There are various methods of treating femoral shaft fractures depending the age group of a child. It can be closed reduction and spica cast in age group younger than six years but above six years of age closed reduction and spica cast may lead to various complications like loss of reduction, malunion and complications of plaster.⁽²⁾ These complications are more frequent at the age of bony maturity because deformities cannot be corrected by remodeling. Most of the femoral shaft fracture in adults are treated by interlock intramedullary nails.⁽³⁾ It is well documented that for children between 5-14 years of age would be a simple, load sharing intramedullary nail that allows mobilization and maintenance of alignment and length of extremity until bridging callus forms. The titanium elastic nail is a stable intramedullary nail for the treatment of the above age group of children of fracture shaft femur.

The technique is simple, effective and has several advantages, including better fracture reduction and dynamic axial stabilization. There is early fracture union due to repeated micromotion at fracture site leading to early mobilization, early weight bearing and rehabilitation. Physis is not disturbed so chances of limb length discrepancy are reduced. The scar mark is well accepted, hospital stay is shorter and implant removal is easy with this technique. The high patient satisfaction rate with low complication rate makes it a suitable implant.⁽⁴⁾ This study is intended to assess the functional and radiological results following treatment of fracture shaft of femur in children by titanium elastic intramedullary nail.

Materials and Method

This prospective study was conducted in the Department of Orthopaedics in SRMSIMS, Bareilly from November 2014 to July 2016 on 30 patients between age group of 5-14 years after obtaining approval from Hospital Ethics committee.

Inclusion Criteria was children and adolescent patients from 5 to 14 years with closed fracture Shaft of femur.

Exclusion Criteria were patients less than 5 years of age and more than 14 years of age having pathological fractures, open fractures and fractures involving the distal 1/3rds of femur.

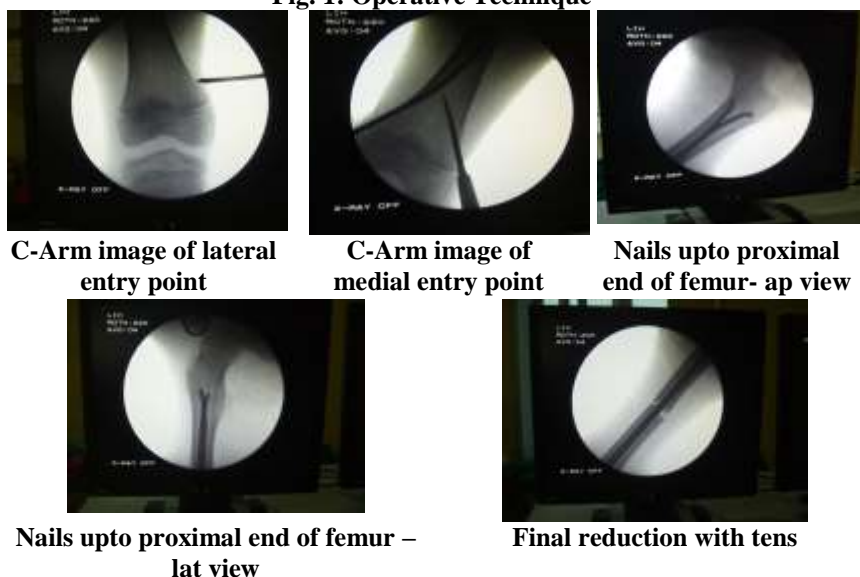
All the fractures in this series were treated by retrograde TEN fixation using two nails of equal diameter for each fracture. The diameter of each nail was selected according to Flynn et al's formula (Diameter of nail = Width of the narrowest point of the medullary canal on the anteroposterior and lateral view x 0.4 mm) and intra-operative assessment. The diameter of the nail was chosen so that each nail occupied at least one third to 40% of the medullary cavity.

Operative Technique

Under regional/ general anaesthesia, the patient was placed on an orthopaedic table and fracture was reduced partially by traction guided by fluoroscopy. Blunt-ended nails of titanium with diameters of 3.0, 3.5 and 4.0 mm were used depending on the child's weight and age. The nails were prepared preoperatively by

angling them at 45 degrees about 2 cm from one end to facilitate penetration of the medullary canal. With the help of T-handle nails were introduced through a longitudinal drill hole, 4 to 5 mm in diameter made in the distal femoral metaphysis just above the physis. Two nails, one lateral and one medial were used to stabilize the fracture. Both nails were pushed up carefully upto the already reduced fracture site. After touching the opposite internal cortex, the nails bent themselves in the direction of the long bone's axis. The T-handle was rotated or limb manipulated to direct the nails into the opposite fragment. When the nails passed the fracture level, traction was released and nails were pushed further and tips were fixed in the spongy tissue of the metaphysis. The distal portion of the nails were left slightly protruding outside the cortex.

Fig. 1: Operative Technique



Postoperatively depending on fracture healing and callus response patients were mobilized without weight bearing on the 7th day post operatively. Partial weight bearing was started at 6 weeks and full weight bearing at 12 weeks. Patients were followed up after 6 weeks, 12 weeks and 24 weeks. On each subsequent visit clinical and radiological examination was done. Functional outcome was assessed at each follow up.

All patients were followed clinically as well as radiologically until the fracture healed, for any complications like infections, skin irritation/ ulceration, range of motion of the joints above and below, nonunion, leg length discrepancy (LLD) and gait abnormalities. Radiographs of all patients were reviewed for malalignments.

The observations obtained were assessed and compared according to FLYNN'S criteria.

Results

The mean age of patients was 9.8 years. The male patients (70%) outnumbered the females (30%) exclusively. Road traffic accident (RTA) was the major cause of fracture shaft of femur (19 cases, 63.3%) followed by fall from height (6 cases, 20%) and self-fall (5 cases, 16.7%). The right side was involved in 56.7% of cases. Transverse fractures were maximum (50%), followed by spiral fractures (20%), oblique fractures (16.7%) and comminuted fractures (13.3%) and maximum number of fractures (22, 73.3%) were of middle 1/3rd, followed by 4 (13.3%) each for upper and lower 1/3rd of shaft of femur. The time between trauma and surgery was less than 2 days (19 cases, 63.3%) and mean duration of surgery was 45.8 minutes.

In our study, no immobilization was required in 11 (36.7%) cases and 19 (63.3%) were immobilized (long leg cast with a pelvic band) postoperatively for 4 weeks. The mean duration of immobilization was 12.37

days. The average radiological union was seen in 12.8 weeks. In 19 cases (63.3%) fracture united between 12-18 weeks and 1 (3.3%) took around 20 weeks for union.

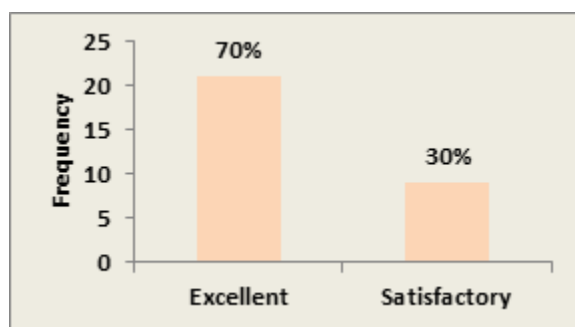
17 patients (56.7%) achieved full range of hip flexion between 0 - 140 degrees, 9 patients (30%) had movements ranging between 0-120 degrees and 4 patients (13.3%) had restriction of hip flexion, ranging between 0 - 100 degrees. 19 patients (63.3%) achieved full range of knee flexion between 0 - 140 degrees, 6 patients (20%) had mild restriction between 0-120 degrees, 3 patients (10%) had knee flexion between 0 - 100 degrees and 2 patients (6.7%) had severe restriction of knee flexion of less than 100 degrees. 28 patients (93.3%) had no knee stiffness.

25 patients (83.3%) had no incidence of superficial infection. Only 1 patient had an incidence of deep infection and varus angulation of more than 10 degrees (3.3% each). There was no incidence of non union in our study and none of our patients had loss of reduction. 22 (73.3%) patients did not have any limb length discrepancy. 5 (16.7%) patients had lengthening and 3 (10%) patients had shortening.

Results were evaluated by using FLYNN'S criteria for fracture shaft femur. We recorded 70% excellent and 30% good results. There was no poor result in any case.

Table 1: Final result

Result	No. of Cases	Percent
Excellent	21	70.0
Satisfactory	9	30.0
Total	30	100.0



Discussion

Recently, Orthopaedic surgeons have been motivated to consider alternatives to skeletal traction and application of a spica cast to avoid the adverse physical, psychological, and social consequences of prolonged immobilization of a school aged child.

Compression plating of femur requires a large soft tissue dissection, has been related with hardware failure, infection, greater blood loss and a second operation for removal.⁽⁵⁾ Solid intramedullary nailing is associated with avascular necrosis of the femoral head, thinning of femoral neck and growth arrest of the greater trochanter with secondary coxa valga.⁽⁶⁾

Recently, the standard of care for most paediatric shaft femur fractures has been the use of ESINs, whether stainless steel or titanium. Titanium elastic nail seems advantageous over other surgical methods particularly in this age group because it is simple, is a load-sharing internal splint that doesn't violate open physis, allows early mobilization and maintains alignment. Micromotion conferred by the elasticity of the fixation promotes faster external bridging callus formation.

In our study union was achieved in <12 weeks in 10 patients (33.3%), 12-18 weeks in 19 (63.3%) of the patients and 18-24 weeks in 1 patient (3.3%). Average time to union was 10.5 weeks. Ramseier LE et al in their study of 194 diaphyseal femoral fractures found mean union time of 11.2 weeks.⁽⁷⁾ Singh R et al in their study of 35 paediatric patients of diaphyseal femoral fractures found that all the fractures healed with an average time to union of 9.6 (6-14) weeks.⁽⁸⁾

The mean duration of immobilization in our study was 12.37 days. The average length of immobilization in plaster was 9.6 weeks in Gross RH et al study.⁽⁹⁾ In a study by Lohiya R et al of 73 patients, no postoperative immobilization was used routinely. Only 3 (4.1%) cases required hip spica cast for initial 4 weeks.⁽¹⁰⁾ Immobilization was required in children more than 10 years of age to prevent rotation and in cases where fracture stability was less than expected. Our study is comparable with the literature with regard to postoperative immobilization.

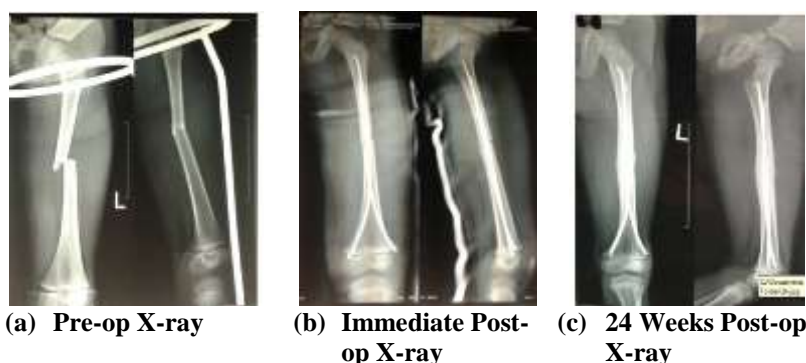
The average duration of hospital stay in the present study is 7.7 days. Shorter hospital stay in our series is attributable to the minimally invasive technique of the procedure which requires very minimal soft tissue insult and also because of stable fixation and less incidence of complications. The mean hospital stay was 5 days in Ramseier LE et al study.⁽⁷⁾

Limb length discrepancy is the most common sequelae after femoral shaft fractures in children and adolescents. 22 (73.3%) patients had no limb length discrepancy. 3 (10%) patients had shortening of 1 cm and 5 (16.6%) patients had lengthening of 1.3 cm. No patient in our study had major limb length discrepancy (i.e. $> \pm 2$ cm). In a study by Salem KH et al there was no significant difference between the injured and uninjured limbs in terms of femoral length. Only eleven patients (16%) out of 68 had a limb length discrepancy of >10 mm.⁽⁴⁾ Ligier et al out of 62 fractures reported mean discrepancy with 1.2 cm lengthening for transverse fractures, 0.7 cm of shortening for spiral fractures.⁽¹¹⁾ The overgrowth phenomenon occurs predominantly in children who are two to ten years of age and it has been attributed to local hyperaemia or the release of growth factors secondary to trauma or surgery that stimulate physal growth.

In our study, there were no complications in 21 (70%) patients. Only 9 (30%) patients had minor complications. Minor complications included skin

irritation or pain at nail insertion site, superficial skin infection not requiring surgery, angulation or malalignment less than 10 degrees and limb length inequality of less than 2 cm. There was no nonunion and no loss of reduction in any of the cases in our study. In the study by Ramseier LE et al only 2 (2%) of the 105 fractures had loss of reduction.⁽⁷⁾ Out of 56 patients, no case of nonunion was reported by Wall EJ et al.⁽¹²⁾

In the present study, the final outcome according to Flynn's criteria was excellent in 21 (70%) cases, satisfactory in 9 (30%) cases and there were no poor outcome cases. Saikia KC et al in their study of 22 children with femoral diaphyseal fractures reported 13 (59%) excellent, 6 (27.2%) satisfactory and 3 (13.6%) poor results.⁽³⁾ Flynn JM et al treated 234 femoral shaft fractures and the outcome was excellent in 150 (65%) cases, satisfactory in 57 (25%) cases and poor in 23 (10%) of the cases.⁽¹³⁾



(a) Pre-op X-ray (b) Immediate Post-op X-ray (c) 24 Weeks Post-op X-ray

Fig. 2: (a) Pre-op, (b) Immediate Post-op, (c) 24 Weeks Post-op X-ray

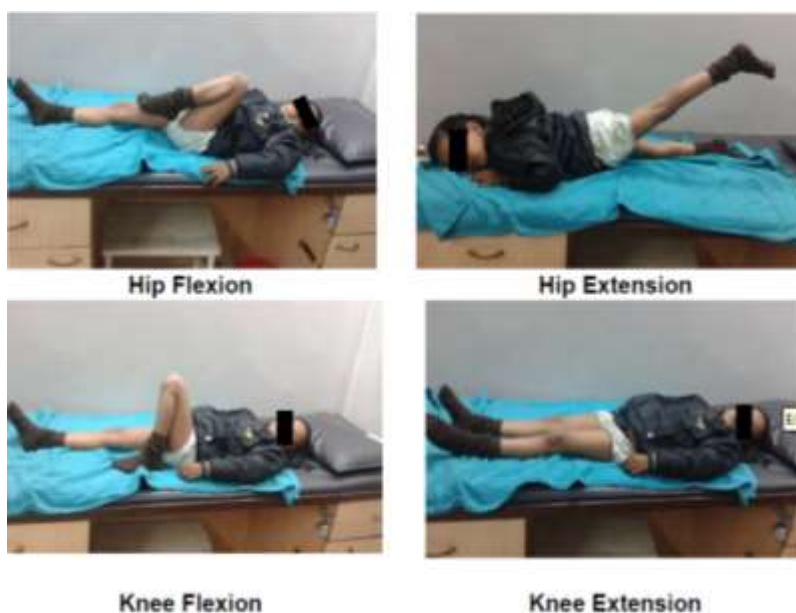


Fig. 3: Clinical photographs

Conclusion

This study has shown that TENS is an ideal method for the treatment of paediatric shaft femur fractures in age group of 5-14 years as it avoids growth disturbance by preserving epiphyseal growth plate. This method of fixation avoids damage or weakening of the construct which provides load sharing and biocompatibility and there is hardly any risk of bone infection.

References

1. Flynn JM, Skaggs. Rockwood and Green's fracture in children. 8th ed. Philadelphia: Lippincott Williams & Wilkins; 2010:1655-1718.
2. Moroz LA, Launay F, Kocher MS, Newton PO, Frick SL, Sponseller PD, et al. Titanium elastic nailing of fractures of femur in children. JBJS (Br). 2006;88-B:1361-6.
3. Saikia KC, Bhuyan SK, Bhattacharya TD, Saikia SP. Titanium elastic nailing for femoral diaphyseal fractures in children. IJO. 2007;41(4):381-5.
4. Salem KH, Keppler P. Limb geometry after elastic stable nailing for paediatric femoral fractures. J Bone Joint Surg Am. 2010;92:1409-17.

5. Bar-on E, Sagiv S, Porat S. External fixation or flexible intramedullary nailing for femoral shaft fractures in children. *J Bone Joint Surg (Br)*. 1997;79-B:975-8.
6. Anastasopoulo J, Petratos D, Konstantoulakis C, Plakogiannis C, Matsinos G. Flexible intramedullary nailing in paediatric femoral shaft fractures. *Injury, Int. J. Care Injured* 41. 2010:578–82.
7. Ramseier LE, Janicki JA, Weir S, Narayanan UG. Femoral fractures in adolescents: a comparison of four methods of fixation. *J Bone Joint Surg Am*. 2010;92:1122-9.
8. Singh R, Sharma SC, Magu NK, Singla A. Titanium elastic nailing in pediatric femoral diaphyseal fractures. *IJO*. 2006;40(1):29-34.
9. Gross RH, Davidson R, Sullivan JA, Peeples RE, Hufft R. Cast brace management of the femoral shaft fracture in children and young adults. *J Pediatr Orthop*. 1983;3(5):572-82.
10. Lohiya R, Bachhal V, Khan U, Kumar D, Vijayvargiya V, Sankhala SS, et al. Flexible intramedullary nailing in paediatric femoral fractures. A report of 73 cases. *Journal of Orthopaedic Surgery and Research*. 2011;6(64):1-10.
11. Ligier JN, Metaizeau JP, Prevot J, Lascombes P. Elastic stable intramedullary nailing of femoral shaft fractures in children. *JBJS [Br]* 1988;70-B:74-7.
12. Wall EJ, Jain V, Vora V, Mehlman CT, Crawford AH. Complications of titanium and stainless steel elastic nail fixation of pediatric femoral fractures. *J Bone Joint Surg Am*. 2008;90:1305-13.
13. Flynn JM, Luedtke LM, Ganley TJ, Dawson J, Davidson, Dormans JP, et al. Comparison of Titanium elastic nails with traction and spica cast to treat femoral fractures in children. *JBJS*. 2004;86-A(4):770-7.